591.4
L725

Horace E. Wood, 2

Digitized by the Internet Archive
in 2026

https://archive.org/details/laboratorymanual0000malc_u0t8

A LABORATORY MANUAL FOR COMPARATIVE ANATOMY

THE MACMILLAN COMPANY
NEW YORK · BOSTON · CHICAGO · DALLAS
ATLANTA · SAN FRANCISCO

MACMILLAN & CO., LIMITED
LONDON · BOMBAY · CALCUTTA
MELBOURNE

THE MACMILLAN CO. OF CANADA, LTD.
TORONTO

A LABORATORY MANUAL FOR COMPARATIVE ANATOMY

BY

MALCOLM E. LITTLE

ASSISTANT PROFESSOR OF BIOLOGY, NEW YORK UNIVERSITY

AND

RUDOLF T. KEMPTON

INSTRUCTOR IN BIOLOGY, NEW YORK UNIVERSITY

New York

THE MACMILLAN COMPANY

1929

All rights reserved

QL
812
.L5
1928

L.A.100, A.986.4

Copyright, 1926, by
MALCOLM E. LITTLE
RUDOLF T. KEMPTON

Copyright, 1928,
By THE MACMILLAN COMPANY

Set up and electrotyped.
Published October, 1928.
Reprinted May, 1929.

PRINTED IN THE UNITED STATES OF AMERICA

BY T. MOREY & SON

MUSEUM ASSOCIATES
LOS ANGELES COUNTY MUSEUM
LIBRARY

PREFACE

The purpose of this manual is to give dissection directions which are sufficiently full to convey principles, but which are not complicated by too much detail or too great discussion. No attempt has been made to make it a text book, or adapt it for general reference, though paragraphs of discussion are added to clear various points. These are separated from the laboratory directions so that the student in the laboratory can attend to the business in hand. Developmental processes rather than minutiae of structure are stressed, with a consideration of both the ontogenetic and phylogenetic history.

The authors have taken a compromise course between the "systemic" and the "systematic" treatment of vertebrate anatomy. There is no need to defend the modern method of teaching by systems, though there are two important objections. First, in large classes, the physical problem of handling the numerous specimens needed at one time; and second, the pedagogic problem of giving the student an idea of the animal as a group of inter-related systems. The attempt is made here to overcome these objections by teaching the dogfish first as a type, and then proceeding to the other vertebrates in a systemic manner. A method of handling material in the laboratory is given in Appendix IV.

At Washington Square College all three methods of teaching anatomy have been tried, and the present method was adopted as most efficient. Since the adoption of the compromise course more than a thousand students have been used as laboratory material, and the results have justified the idea. For, before studying the comparative structure of the organs, the student has a thorough knowledge of the vertebrate as a functional unit, and while comparing one system thinks in terms of its relation to the others.

However, in compiling the manual, the needs of other courses were kept in mind, and the material is arranged in unit sections so that the dogfish can be studied systemically with the other types; or the higher vertebrates can be dissected as type specimens. To assist with this, a systematic Table of Contents is included.

The more important laboratory animals have been included, the

frog being omitted as it is used in so many elementary courses in biology. Cryptobranchus can be dissected easily by following the directions for Necturus, though a separate discussion of the skull is necessary. Both the alligator and the turtle are described. If a reptile is included the alligator is exceptionally adapted for laboratory dissection, though difficult to obtain. If prepared skeletons of Alligator are available it fills perfectly the gap between amphibia and mammals and can be used without the dissection of the animal. The cat and rabbit are described for the mammal dissection. The cat skeleton is cheaper and more generalized for study, but better success in soft anatomy has been had with the rabbit. All the animals described have been used in our courses, and the directions constantly checked.

In the course at this college Amphioxus is given a prominent place at the beginning of the course to give the idea of the primitive vertebrate characters. The sections on the dogfish, classification, the skeleton, and integument are taken almost in their entirety. For soft anatomy only Necturus and the rabbit are used, except in the Nervous System, where the dogfish is also included. For this study an extra head (obtainable from any supply house) is used. The exercises on the embryology of systems are always included to give the developmental point of view. Even if time does not permit verification in the laboratory, the descriptions are sufficiently generalized to give a useful introduction to the dissection of the system.

The manual in its present form is the development of mimeographed laboratory directions which were written for the authors' changing ideas of the best laboratory animals. These directions were revised and printed in 1926, and in this form were used for two years. In the spring of 1928 Walter's *Biology of the Vertebrates* was adopted as the course text, and with the advice of Professor Walter the manual was again rewritten for publication by The Macmillan Company. The publishers have been more than cooperative during the process of getting the book in shape.

Acknowledgments cannot be made individually for assistance from books and papers which have been drawn upon. These have been freely used, and the only originality claimed is the arrangement of the subject matter. However, we wish to acknowledge our debt to our colleague, Mr. Arthur M. Crosman for invaluable assistance in making the manual usable in the laboratory, and for

critically reading the manuscript. We are also indebted to Professors W. K. Gregory and J. H. McGregor, of the American Museum of Natural History and Columbia University, for many suggestions as to the book and for the information we have gained from them. Most of the drawings are the work of Mrs. Louise Duggar Plunkett, whom we wish to thank for her assistance. We also wish to express appreciation for the assistance of our instructors and students in checking ambiguities and inconsistencies. Messrs. George Howlin, Samuel Feinberg, and Sigmund Friedman have been of unusual value in the technical preparation of the manuscript. The errors which have slipped in are our own.

M. E. L.
R. T. K.

WASHINGTON SQUARE COLLEGE,
NEW YORK UNIVERSITY,
September, 1928.

Presented to Horace Elmer Wood II
after being held up for it
With the compliments of
Mack L.

Sept. 23, 1930

TABLE OF CONTENTS

PAGE

INTRODUCTION xvii

PART

I. AMPHIOXUS

A. Gross Anatomy 1
B. Cross-Sections 5
C. Discussion 8

II. THE DOGFISH

A. External Anatomy 11
B. Trunk and Appendicular Skeleton 13
C. Chondrocranium and Visceral Arches 15
D. Musculature 19
E. Digestive System 20
F. Circulatory System 22
G. Urinogenital System 29
H. Brain 32
I. Cross-Sections 34

III. CLASSIFICATION OF VERTEBRATES

A. Method of Classification 36
B. Classes of the Chordata 37
C. Laboratory Identification of Types 38
D. Orders of the Vertebrates 44

IV. STRUCTURE OF FUNDAMENTAL TISSUES

A. General Discussion 50
B. Laboratory Study of Tissues 52

V. ENDOSKELETON

A. Structure of Bone and Cartilage 56
B. Evolution and Development of the Skull . . . 58
C. The Amphibian Skull 61
D. The Reptile Skull 67
E. The Mammal-Like Reptile and Mammal Skulls . . 72
F. The Alligator Skeleton 80
G. The Turtle Skeleton 82
H. The Bird Skeleton (Pigeon) 84
I. Vertebral Column, Ribs, and Sternum of the Mammal 87
J. Pectoral Girdle and Anterior Limb of the Mammal . 91
K. Pelvic Girdle and Posterior Limb of the Mammal . 93
L. Comparison of the Vertebrate Skeletons . . . 95

PART PAGE

VI. EXOSKELETON

A. Dermal Structures of the Skin 100
B. Skin and Epidermal Structures 101

VII. EXTERNAL ANATOMY

A. Necturus 107
B. Turtle 108
C. Alligator 109
D. Bird 110
E. Mammal 110

VIII. MUSCULAR SYSTEM

A. Development 113
B. General Discussion 116
C. Superficial Description 118
D. Muscles of the Head 121
E. Muscles of the Neck and Shoulder 126
F. Muscles of the Anterior Limb 138
G. Muscles of the Body 143
H. Muscles of the Pelvis and Thigh 147
I. Muscles of the Shank 156

IX. DIGESTIVE AND RESPIRATORY SYSTEMS

A. Necturus 159
B. Turtle 160
C. Alligator 163
D. Pigeon 165
E. Mammal 167
F. Structure of the Digestive Tract 173

X. CIRCULATORY SYSTEM

A. Necturus 175
B. Turtle 179
C. Alligator 185
D. Pigeon 188
E. Rabbit 191
F. Cat 200
G. Structure of the Heart 209
H. Microscopic Structure of Blood 214

XI. URINOGENITAL SYSTEM

A. Necturus 217
B. Turtle 218
C. Alligator 220
D. Pigeon 221
E. Mammal 222
F. Structure of the Gonads 227

PART PAGE

XII. NERVOUS SYSTEM

A. Development 231
B. Inner Ear of the Dogfish 234
C. Eye of the Dogfish 236
D. Nervous System of the Dogfish 238
E. Nervous System of the Bird (Pigeon) 244
F. Brain of the Mammal 247
G. Spinal Cord and Nerves of the Mammal . . . 251

APPENDIX

I. Preparation of Demonstration Slides 257
II. Staining and Clearing Embryos 260
III. Injection and Preservation of Animals 263
IV. Laboratory Storage of Specimens 269
V. Latin and Greek Roots of Scientific Names 270

INDEX 275

TABLE OF CONTENTS FOR SYSTEMATIC STUDY

PAGE

AMPHIOXUS

Gross Anatomy 1
Cross-Sections 5
Discussion 8

DOGFISH

External Anatomy 11
Trunk and Appendicular Skeleton 13
Chondrocranium and Visceral Arches 15
Musculature 19
Digestive and Respiratory System 20
Circulatory System 22
Urinogenital System 29
Inner Ear 234
Eye 236
Nervous System 238

NECTURUS

External Anatomy 107
Skull 62
Exoskeleton 101
Superficial Description of Muscles 119
Muscles of the Head 122
Muscles of the Neck and Shoulder 126
Muscles of the Anterior Limb 138
Muscles of the Body 143
Muscles of the Pelvis and Thigh 147
Muscles of the Shank 156
Digestive and Respiratory System 159
Circulatory System 175
Urinogenital System 217

TURTLE

External Anatomy 108
Skull 67
Endoskeleton 82
Exoskeleton 102
Digestive and Respiratory Systems 160
Circulatory System 179
Urinogenital System 218

PAGE

ALLIGATOR

External Anatomy 109
Skull 69
Endoskeleton 80
Exoskeleton 102
Superficial Description of Muscles 120
Muscles of the Head 123
Muscles of the Neck and Shoulder 127
Muscles of the Anterior Limb 138
Muscles of the Body 144
Muscles of the Pelvis and Thigh 148
Muscles of the Shank 156
Digestive and Respiratory Systems 163
Circulatory System 185
Urinogenital System 220

PIGEON

External Anatomy 110
Endoskeleton 84
Exoskeleton 103
Digestive and Respiratory Systems 165
Circulatory System 188
Urinogenital System 221
Nervous System 244

RABBIT

External Anatomy 110
Skull 72
Endoskeleton 91
Exoskeleton 104
Superficial Description of Muscles 120
Muscles of the Head 123
Muscles of the Neck and Shoulder 130
Muscles of the Anterior Limb 140
Muscles of the Body 145
Muscles of the Pelvis and Thigh 151
Muscles of the Shank 157
Digestive and Respiratory Systems 167
Circulatory System 191
Urinogenital System 222
Brain 247
Spinal Cord and Nerves 251

CAT

External Anatomy 110
Skull 72
Endoskeleton 91
Exoskeleton 104

PAGE

Superficial Description of Muscles 120
Muscles of the Head 125
Muscles of the Neck and Shoulder 134
Muscles of the Anterior Limb 142
Muscles of the Body 146
Muscles of the Pelvis and Thigh 153
Muscles of the Shank 158
Digestive and Respiratory System 167
Circulatory System 200
Urinogenital System 222
Brain 247
Spinal Cord and Nerves 251

INTRODUCTION

Definitions of vertebrate characters are properly included in textbooks and not in laboratory manuals, therefore the student is referred to any standard reference on the subject. However, a few of the terms of anatomists should be defined.

The vertebrate is considered as having three axes: First, an antero-posterior, or primary axis. The vertebrate normally progresses with the head forward and the tail behind. The head, therefore, is the *cranial* or *anterior* part of the body, and the tail the *posterior* or *caudal* part. *Craniad* and *caudad* mean toward the head and tail respectively. Some confusion arises in human anatomy due to the fact that man walks upright with the ventral side to the front, and older anatomists named structures from the human condition. Comparative anatomists and recent human anatomists adopt the morphological nomenclature and give human structures names which can apply to all vertebrates. Consequently, "anterior" and "posterior" of man are ventral and dorsal; and "superior" and "inferior" refer to anterior and posterior.

The *second* axis is the dorso-ventral axis, passing through the animal from top to bottom. The mouth of the vertebrate is always *ventral* in its development, and the nerve cord *dorsal.*

The third axis passes at right angles to the first two, passing from side to side in the horizontal plane. Structures which lie along this axis are considered as beginning at the middle of the body. Those which lie near the primary axis being *median* in position. Those lying outward from the middle are *lateral. Mediad* and *laterad* mean passing toward the median or lateral position, i.e., an artery from the heart passes laterad to the arm.

Other terms used in anatomy are:

(1) *Proximal* means near, and *distal* is out from. The upper part of the arm is proximal, the hand is distal. The same definitions apply to any structure, a bone, blood vessel, or muscle.

(2) *Longitudinal* refers to the long or antero-posterior axis. If the plane passes longitudinally through the median line, it is a *sagittal* plane or section. This divides the vertebrate into equal

parts, and in the early embryo into mirror halves. As the adult vertebrate is never perfectly bilaterally symmetrical, this is not true after modifications set in.

(3) *Transverse,* or *cross-sections* are planes which cut the animal through the second and third axes. These may pass through any point on the antero-posterior axis.

(4) *Phylogeny* refers to the development of the race. Phylogenetic development is traced by embryology and palaeontology (study of fossils). The latter give a fairly accurate account of the appearance of a group in past geologic time periods; and the succession of fossils from oldest to youngest gives a clue to the development of the particular group.

(5) *Ontogeny* is the development of the individual, the embryonic history. In many ways the development of the individual repeats the racial history, though the embryo of one race never resembles the *adult* of another group, whether it be ancestral or not.

(6) *Homology* of parts is the condition where the development of the structures is the same. Both phylogeny and ontogeny are considered in determining homologous structures.

(7) *Analogy* is similarity of function, and has no reference to homology. The jaws of a sea-urchin and the jaws of a fish are analogous and not homologous. The wings of a bat (a mammal) and of a bird are analogous and homologous; but the arm of a monkey and the wing of a bird are homologous and not analogous.

Dissection of structures is laying them bare, and should be done with reference to all the systems of the body. In dissecting an animal the student needs good instruments. Two knives (scalpels) are useful, one for heavy work, and one for fine cutting. The latter is particularly useful with the dogfish where the structures are often embedded in cartilage, which must be shaved away to expose a small organ. For this purpose a knife with removable blades is recommended, as these can be kept with a razor edge at little expense. In addition, the usual forceps, scissors, needles, etc., which are included in good sets of instruments, are needed.

Drawings are a local problem, opinions differing as to their number and usefulness. Most students waste too much time making beautiful and not useful sketches. Several outlines are included in the manual to save students' time, and these should be filled in to make useful illustrations which will serve later for reference, even though not required in the laboratory. Methods in drawing differ. As the course is designed for anatomists, not

artists, drawings are usually kept as simple as possible. Colors add much to the clarity of most drawings, and are most useful in work in embryology and the circulatory system. In the former, *ectoderm* is usually colored blue; *endoderm*, yellow; and *mesoderm*, red.

Since comparative anatomy has become a required course for entrance to most medical schools the field has been flooded by students who wish an elementary course in human anatomy so that their first year in a professional school will be a detailed review. Though this might help many students to pass the "first year," it is not a preparation for medical practice. Comparative anatomy should give a foundation for the intelligent understanding of the human body, which is best gained by an understanding of the history and development of animals and their organs. The student should follow the system from its generalized to its specialized condition, which necessarily gives a clearer understanding of the relationships of complex structures. The result is valuable, whether the animals are interpreted as an evolutionary or an accidental series.

A LABORATORY MANUAL FOR COMPARATIVE ANATOMY

A LABORATORY MANUAL FOR COMPARATIVE ANATOMY

PART I

AMPHIOXUS

A. Gross Anatomy

1. Formalin Specimen. This is an individual which was killed and preserved by immersion in formalin. This preservative causes the normally transparent animal to become opaque, so that only the external structures can be observed. Keep the animal immersed in water in a watch glass during study so that it will not become dried and thus spoiled. Orient the animal. The tail is more acutely pointed than the anterior end, and the ventral surface more rounded than the dorsal.

a. Note the metameric, V-shaped *myomeres*, or muscle plates. In which direction is the apex of the "V" pointed? The myomeres are separated by thin sheets of connective tissue, the *myosepta*. These show as very narrow white lines between the muscle plates. The muscle fibers extend lengthwise of the body, and the fibers of each myomere attach at their ends to each of the two myosepta bounding the muscle plate. How is movement produced?

b. With the aid of a hand lens note the *rostrum*, an anterior projection of the dorsal surface, extending along the top of the funnel-shaped *buccal hood*. The margin of the hood is fringed with *buccal cirri*.

c. The *metapleural folds* will be seen as thickened ridges along the sides of the ventral surface, extending posteriorly from the buccal hood. They extend about two-thirds the length of the body, and at their posterior limit is a depression in the ventral surface. This depression is the location of an opening for the outlet of water, the *atriopore*.

d. Along the dorsal surface of the animal is a low ridge, the *dorsal fin*. Posteriorly this becomes enlarged to form the tail or *caudal fin* which has continuous dorsal and ventral parts. The latter merges into the low *ventral fin* which extends as far anteriorly as the atriopore.

e. The *gonads* (ovaries or testes) are whitish, spheroidal bodies that may usually be seen through the ventral wall. Are they metamerically arranged? Are the two corresponding gonads exactly opposite? How many gonads are there on either side?

f. Consider the burrowing and swimming habits of the animal, and try to determine the special functions of the myotomes, rostrum, oral hood, and atriopore.

2. Cleared Specimen. This is a small adult which has been stained to show the various structures, made transparent to allow the internal structures to be observed, and mounted on a slide for the use of a microscope in studying the animal. The slide is to be handled with great care. Use *low power* of the microscope only, as the preparation is too thick to permit the use of high power. Study the animal as a whole for a few minutes and then make the following more detailed study.

a. The *notochord* is a cylindrical elastic rod extending the entire length of the body from the tip of the rostrum to the tip of the tail. It can be identified by its position in the dorsal region, its length, and the minute cross markings that appear in a preparation of this type. The cross markings are artificially formed in the preparation of the slides.

b. Near the margin of the buccal hood note the horseshoe-shaped *buccal skeleton* that tends to keep the soft structures in position. An extension passes from the skeleton into each of the buccal cirri.

c. Within the hood is the deeply stained, lobulated *wheel organ*. This surrounds the mouth, and is covered with cilia, the action of which causes a constant current of water to pass into the mouth. In addition, it is said to have a sensory function. The small *mouth*, located immediately behind the wheel organ, is simply an opening in the base of the hood. Since it is seen on edge it is very difficult to identify it. From the margin of the mouth, extending into the oral hood, are

delicate thread-like projections, the *oral tentacles*. They can be folded across the mouth, thus acting as a sieve to keep out particles that are too large.

d. The *pharynx* is a cylindrical structure into which the mouth opens directly. It is perforated by many *gill slits*, which have not yet attained their full number.

e. The *branchial rods* are the skeletal structures that support the soft tissues separating the gill slits. Note that they slant postero-ventrally. Visualize a cross-section of the pharynx. The soft tissues are composed largely of the *gills*, or *branchial lamellae*. These are richly supplied with blood, and it is in them that aëration of the blood takes place. The rods are of two kinds; the *primary bars*, which are forked ventrally, and the *secondary* or *tongue bars* which are straight.

f. The *endostyle* is a ciliated groove in the mid-ventral line of the pharynx. From its anterior end the *peripharyngeal grooves* may be seen extending upward around the mouth, and connecting with the mid-dorsal *epipharyngeal groove*. The latter empties, at the posterior end of the pharynx, into the *stomach-intestine*. The cilia beat anteriorly in the endostyle, posteriorly in the epipharyngeal groove. What is the course of a food particle in the pharynx? What is the course of water?

g. Trace the alimentary canal from the pharynx to the *anus*. On which side of the body is this opening found? The *liver*, or *hepatic caecum*, is a ventral outpocketing from the canal, originating just posterior to the pharynx. It extends anteriorly along the right side of the pharynx. Its length depends on the age of the animal, as its growth is gradual. Near its posterior end, there is a deeply staining region of the stomach-intestine which is thought to be glandular in function.

h. The *nerve cord* lies just dorsal to the notochord. How does it compare with the notochord as to its anterior limit? Note the black "*eye-spot*" near its anterior end, and the numerous *pigment cells* along the side. What is the distribution of these cells? What is their probable function?

i. Dorsal to the eyespot the *olfactory pit* may be seen with difficulty.

j. The atriopore is the mid-ventral opening of the atrium that was observed on the formalin specimen. What is the rela-

tion of the atriopore to the metapleural folds and the ventral fin?

k. *Skeletal blocks*, supporting structures, may be seen in the dorsal and ventral fins. How is the caudal fin supported?

3. Drawings. In the outline marked "A" fill in six of the myotomes, and the buccal and fin cartilages. Label the fins and any other structures that could be seen in the formalin specimen. In the outline marked "B" show the organs in place with the muscles not shown.

4. The following questions are to be answered from your laboratory work, lectures or reading:

a. What three systems are distinctly metameric? Do you consider this a primitive character?

b. Do the gill slits correspond with the myomeres in their segmentation, or are they more numerous?

c. What structures that you have seen in Amphioxus would justify the placing of this animal among the Chordata?

d. What advantages would there be in dissecting this animal with the right side up rather than the left?

e. Recall the various ciliated grooves in the pharynx, the direction of their ciliary actions, and the function of these parts in feeding. Would you call Amphioxus an active or a passive feeder? Of what does its food consist?

f. Trace the course of intaken water from the buccal hood to the atriopore. What mechanism produces this current?

g. What is the mechanism of swimming? Of burrowing? Is the notochord of any assistance in either movement? What structures would seem to be a special adaptation to the burrowing habit?

h. What characters common to all vertebrates does Amphioxus possess? How does it differ from the craniate chordates? What is the meaning of "Cephalochordata", the name of the group in which Amphioxus is placed? In what way does this name apply to this animal?

i. Try making diagrammatic cross-sections through various regions of the body.

PLATE 1. Outlines of Amphioxus. One outline can be used for external structures, the other for internal anatomy. Label the drawings fully.

B. Cross-Sections

1. The finer details of the structure of Amphioxus can be seen only by means of slides of cross-sections to be studied with the microscope. These slides usually contain sections through various parts of the body. Try to visualize the structures in three dimensions. Remember that a longitudinal duct or blood vessel will appear as a circle in a cross-section. How would it appear in a longitudinal section? Outlines are provided to save time in drawing. Fill in the outlines, sketching and labelling the structures mentioned below. All accidental breaks or distortions should be omitted from the drawings. Use the entire specimens or your previous drawings to aid in locating the section in the body.

2. **Section through the Buccal Funnel.**

a. Identify the *notochord*, found in the dorsal region. Adjust the slide so that this appears away from you.

b. Above the notochord find the nerve cord. Does it show a cavity? Nerve cells? Nerve roots?

c. Laterally find the *myomeres*, or muscle plates. Does more than one myomere appear in a single section? Explain. Note the arrangement of the *myosepta*. What is their relation to the notochord? What is the significance of this fact in regard to the function of the notochord? Notice that the connective tissue of these septa is continuous with that of the inner layer of the skin, the *dermis*. What is the relation of the muscle fibers to the septa?

d. The body is covered with the *epidermis*, composed of elongated columnar cells. External to this is the very thin *cuticle*. In stained slides the latter was probably lost in preparation, and the cells of the epidermis have shrunk, so that the outer surface appears fringe-like.

e. The thickened edges of the buccal funnel enclose the cartilage-like *buccal skeleton*. The buccal cirri appear as if detached from the body. What is the explanation of this?

f. If the section cuts through the posterior part of the buccal hood, the *wheel organ* will be found as bands of ciliated epithelium. In this posterior section, in the mid-dorsal line of the roof of the hood may be seen a ciliated groove, the *groove of Hatschek*. This is supposed to have a sensory function.

3. Section through the Pharynx, Liver and Gonads. There are two possible types of sections through the pharynx, and it is only in sections through the posterior part that the liver and gonads will appear, since their anterior extent is not so great as that of the pharynx. It is this posterior section that will be described. Identify as many of the structures mentioned in Paragraph 2 as possible, and in addition the following:

a. The *metapleural folds* are on the lateral-ventral sides. Do they contain cavities?

b. The *transverse muscles* are ventral, and support the ventral side of the body. This band of muscle is a thin sheet running under the pharynx. How does it connect laterally? Account for the difference in appearance between this muscle and the myomeres.

c. The *liver* is easily identified by its appearance, since it is a simple sac-like structure and appears in section as a more or less circular mass with a cavity in the middle. On which side of the body is the liver actually located? On which side does it appear to be located in the section through the microscope? With a hand lens? Can you tell from this whether the anterior or posterior side of the section is face up on the slide? Is the liver surrounded by a coelomic space?

d. The *pharynx* is the central cavity outlined by the irregularly triangular sections of the *branchial lamellae*. How many gill bars were cut in this section? Identify the *gill slits*. How do you account for the great number present? Even under low power the primary and secondary bars can be distinguished, as the former tend to be the larger. Which one carries a tube of coelom? Note the mid-ventral endostyle and the dorsal *epipharyngeal groove*. Recall their function.

e. It is important to recognize the limits of the *coelom* and *atrium*. The coelom is visible as two narrow, dorso-lateral spaces between the pharynx and the myotomes, to either side of the mid-line; and as a tube immediately ventral to the endostyle. These dorso-lateral and ventral spaces are in communication through delicate tubes in the primary branchial lamellae.

f. The *gonads* may appear on only one side, and usually one is larger than the other in section. How do you explain this?

The sex is easily determined, since the ovary, if present, contains small round eggs. The testis, if the animal is a male, appears to be very compact. How do the eggs or sperm pass out of the body? Where does fertilization take place?

g. Identify the following blood vessels: (1) two *dorsal aortae*, one on either side of the epipharyngeal groove and close to the sheath of the notochord; (2) the *ventral aorta*, in the ventral coelomic space; and (3) the *hepatic vein*, close to the liver. What is the direction of the flow of blood in each?

h. The *nephridia* cannot be studied to advantage in most sections. They are located just lateral to the upper end of the gill slits, but probably will not be seen.

4. Section between the Pharynx and Atriopore. Since sections through the atriopore are rather infrequent, a section just anterior to it is described. If the section is through the atriopore, that structure will appear as a ventral opening in the section.

a. Compare the extent of the atrium to that in the preceding section.

b. Are the metaplcural folds present?

c. Are the ventral transverse muscles present?

d. Is the lining of the intestine ciliated? Has the intestine any muscular layers? How does the structure of the intestine compare with that of the liver? What is the function of the liver of Amphioxus?

e. Determine the extent of the coelom.

f. Are two dorsal aortae present, or only a single one? Just ventral to the intestine may be found the *subintestinal vein*. If the liver is present, on the ventral surface may be seen the *hepatic portal vein*. What is the course of blood in these vessels?

5. Section Posterior to the Atriopore. Sections exactly through the anus are rare in commercial slides, but if one is found, the *anus* shows as an indentation at one side of the ventral lobe of the caudal fin.

a. Is the intestine present? Is the section through the ventral fin or through the ventral part of the caudal fin? Is the section anterior or posterior to the anus?

b. Is the atrium or coelom present in the section?

c. Are any blood vessels present?
d. What is the character of the skeletal supports for the fins?

6. Study the following sections under *high power*. In focussing use care not to break the slide.

a. *Nerve cord:* The parts of the nerve cord are better seen in the more anterior sections. The cavity in the center of the cord, the *central canal*, is elongated as a narrow slit dorsally. Bounding this cavity is a group of large cells. Some of these are nerve cells, and others are supporting cells, the difference not being clear in ordinary preparations. The main mass of the cord as seen in section is made up of sections of longitudinal fibers, passing from the anterior end posteriorly, or in the other direction. In some sections, a mass of fibers may be seen passing laterally from the cord. These are the *roots* of the nerves. If they leave the cord from the *dorsal* half, they are mostly *sensory;* if from the *ventral* part, they are *motor*, innervating the muscles. Amphioxus differs from higher vertebrates in having the dorsal root mixed, although predominantly sensory.

b. *Endostyle.* Note the long cilia extending from the cells into the groove. The cells lining the groove are secretory, giving off a sticky mucus in which food becomes entangled.

C. Discussion

The significance of Amphioxus, and its value to the study of evolution has been a point of disagreement among zoologists since the discovery of its relationship to the Chordates. It was then placed as a Sub-class to the fishes; but later, its lack of true piscene characters forced its inclusion with the lower forms of the Chordates. The Tunicates, its nearest relatives among the Protochordates, being admittedly degenerate led to the belief that Amphioxus itself was a case of reversed evolution—a fish that had gone backward. Later, its similarity to the larval form of the lamprey, a true vertebrate, led to the belief that it is the larva of some higher form which attained sexual maturity while still in the larval condition. As other sexually mature larval forms are known, the theory is well within the range of possibility. The most recent work, however, leads to the belief that Amphioxus represents a highly specialized descendant of a very primitive

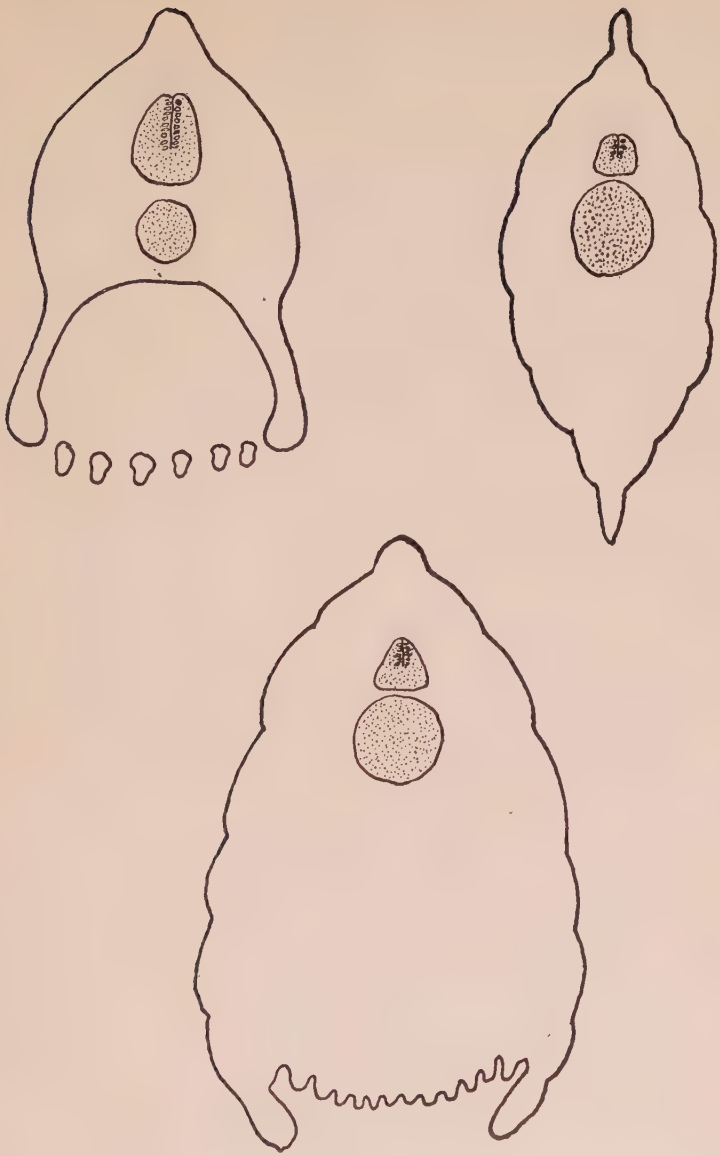

PLATE 2. Cross sections of Amphioxus. The three outlines are from the region of the buccal funnel, the pharynx (below), and the post-pharyngeal. Both the nerve cord and notochord are included to orient the student. The other structures should be filled in and labelled.

MUSEUM ASSOCIATES
LOS ANGELES COUNTY MUSEUM
THE LIBRARY

group which was at the base of the evolutionary stem of the vertebrates. Considered from this viewpoint, Amphioxus becomes a basic form, having the fundamental characters of the vertebrates in their simplest condition.

The proof that Amphioxus is a primitive vertebrate lies first in its embryology. A student finds its early stages of development a diagrammatic presentation of vertebrate embryology, the different steps being taken slowly and in typical order. In the higher vertebrates early development is more rapid and specialized. In addition, the vascular system is the simplest possible structure from which that of other groups could have evolved, lacking any vestigial vessels which should be present if the animal were degenerate rather than primitive. Further evidence is the metameric structure of the gonads, and the student should remember that metamerism is primitive and generalized, the more specialized animals tending to lose it. The *nephridia* are metameric, and in structure bear little resemblance to those of other vertebrates; the gills are at first simple and metameric; and the visceral organs are as generalized as the vertebrate digestive tract could be. These facts lend weight to the belief that its ancestors were the common stock from which the craniates arose, and that Amphioxi form a connecting link between the lower chordates and the higher.

On the other hand, the evident specializations which occur in the later development of Amphioxus, and the degenerate condition of the brain and sensory organs, have been used as evidence of its degenerate or larval condition. The fact that a typical endostyle is present in the larva of the lamprey (one of the most primitive craniate vertebrates) is used as evidence for the belief that Amphioxus is a permanent larva of a form allied to these animals. But as an endostyle is found in the Tunicates, and Amphioxus fits between them and the lampreys both anatomically and embryologically, this condition really strengthens the belief that Amphioxus is primitive. The question is still open, but the opinion of most students favors the interpretation that Amphioxus has a definite place in the evolutionary chain.

The student at this point should get an idea of the anatomist's use of "*primitive*", "*generalized*" and "*specialized*". A primitive animal is one which has kept the fundamental structures of the ancestral group, one which is closely linked with his distant

ancestors. "Generalized" refers to the fact that during the course of evolution the race has not taken on many marked adaptations for a special environment. Thus, a shark may be more generalized than Amphioxus, but the latter is more primitive, as in its deeper structure it has varied less from the first model. "Specialized" refers to those adaptations to environment which unfit the animal to life in any other medium. These terms apply not only to the entire animal, but to individual parts, so that a generalized animal may have a number of specializations. When the terms are applied to a group, the entire balance of characters is considered. If one thinks of the vast period of time covered by the history of any race, it is easy to understand that during the changing geological periods it would be impossible for any race to survive without certain specializations; and further, that no modern group could possibly be ancestral to another recent race. Amphioxus is *not* ancestral to man. It is a primitive animal that has evolved but little from the primitive chordate that gave rise to the different vertebrate stocks, each evolving in many directions. To use the symbols of genetics, we are not the F_1 of Amphioxus, but we are both Fn's of the same P_1, the human race having suffered from more mutations of the germ plasm.

PART II

THE DOGFISH

A. External Anatomy

1. The Dogfish (*Squalus acanthias*) is a small shark inhabiting the coast waters of the United States. It is selected for study of the vertebrate as a whole because it is one of the most primitive and generalized of modern vertebrates, though specialized in many organs. The student should bear in mind that no animal is primitive in all its parts, as specializations are always acquired in the course of race history. Squalus belongs to the Elasmobranch fishes, a group entirely lacking in bone. The skeleton is formed of cartilage, and though calcium salts may be deposited in the cartilage of old animals, it never takes the histological structure of bone.

2. Note the fusiform body shape, and the relative length of the head, trunk and tail. On the dorsal side notice the median, unpaired fins, the *anterior* and *posterior dorsals*. The tail, or *caudal* fin, is also unpaired. In addition there are two pairs of fins, the *pectoral* and *pelvic* fins. Observe that the dorsal fins are attached to the body for about half their length, and that each has a spine on the anterior margin. Are the two lobes of the caudal fin symmetrical? What is the relation of the vertebral column to this fin? Are the median and paired fins similar in structure? The anterior paired fins are the *pectoral fins*. These are freely movable, and act as balancing organs in the swift, darting movements of the animal. The posterior *pelvic fins* are smaller, and differ in the sexes. In the male they serve the double function of balancer and copulatory organs. The latter are the *claspers*, the elongated inner edge of the fins. The sexes are easily distinguished by this character. On the dorsal surface of the clasper is a groove extending from a sac at the base of the fin to the tip, through which the spermatozoa pass. These structures are used for internal fertilization, which is a general characteristic of this group.

3. Between the two pelvic fins find the *cloaca*, the external opening of the digestive and urinogenital tracts. Spread open the cloaca and notice in the anterior part the *anus*, or outlet of the digestive tract. Posterior to this is a large fleshy process perforated by a pore. In the female this is the *urinary papilla;* but in the male it also serves as the genital outlet and is called the *urinogenital papilla*. The paired genital openings of the female are located on either side of the anterior part of the papilla. They are difficult to find in sexually immature animals. Note the *abdominal pores* at the lateral edges of the cloaca, opening into the body cavity or *coelom*. Their function is unknown.

4. The *lateral line*, which extends along the sides of the animal, can be identified by a color difference. It consists of many minute pores which form a canal near the caudal fin. It is the location of many sensory organs.

5. Pass your finger along the side of the animal. The roughness is caused by the *dermal denticles*, or *placoid scales*, which are made of dentine and may be considered homologous with the large spines and the teeth. Study the scales with a hand lens. Determine the distribution of the scales. Are any areas free from them?

6. In the head region identify:

a. The *eyes*. Is there a lid?

b. The *nostrils*. Probe with a blunt instrument to see if they open into the mouth cavity. What is their function? What is the functional difference between these nostrils and those of man?

c. The *spiracles*, openings posterior to the eyes. Do they connect with the mouth cavity? Is there a rudimentary gill within the spiracle? What is the probable homology of the spiracle?

d. The *endolymphatic pores*, lying between the spiracles, close to the mid-dorsal line. These are the openings of the endolymphatic ducts which connect with the inner ear and transmit vibrations to the auditory apparatus.

e. The *mucous pores*, from which mucus may be squeezed by pressing on the skin of the snout. Their function is not well known.

PLATE 3. Outline of Squalus, for study of external anatomy. Add all structures not shown in the diagram.

f. The *gill slits*, on the lateral surface anterior to the pectoral fins. What is their number? Their function? Where do they open internally?

g. The *mouth*. Is there more than one row of teeth? Can the upper jaw be moved without moving the cranium? Is this true of the other animals that you know?

B. Trunk and Appendicular Skeleton

1. Trunk Vertebrae: End View. Examine preserved specimens. Keep these covered with water as they are very delicate, and must be handled with care. Study the end of a vertebra. Identify:

a. The *centrum*, which is laid down around the notochord. In higher vertebrates the centrum is solid and the notochord has disappeared. In Elasmobranchs a remnant is present.

b. The *neural arch* is dorsal to the centrum and encloses the spinal cord. The latter has been lost in the process of preparation.

c. The *neural spine* completes the neural arch dorsally.

d. The *transverse processes* of the centrum. In the living animal *ribs* are attached to these projections, but they are always lost in preparation.

2. Trunk Vertebrae: Lateral View. Study the lateral surface of the vertebrae, identifying those structures previously noted. Observe that the arch is made up of two kinds of plates: (a) The *vertebral plates* directly over the centrum and (b) the *intervertebral plates* alternating with them. Find the openings for the dorsal and ventral roots of the spinal cord. What is the relation of these foramina to the neural plates?

3. Caudal Vertebrae: Cross-Section. Make a cross-section of the vertebral column in the region posterior to the cut made when the animal was injected. Identify all the parts seen in the trunk vertebrae. The vertebrae in the tail region have a *haemal arch*, ventral to the centrum. This arch encloses two openings, a dorsal one for the *caudal artery*, and a ventral one for the *caudal vein*. The haemal arch is the homologue of what portion of the trunk vertebrae?

4. Caudal Vertebrae: Longitudinal Section. Make a dorso-ventral hemisection of a portion of the caudal vertebral column.

Identify all the parts. Observe the shape of the notochord as seen in this section. Are the ends of the centrum concave or convex? What is the relation of the vertebral articulations to the constrictions of the notochord?

5. Skeleton of the Pectoral Girdle and Fin. To skin the dogfish, make a median dorsal incision, passing to the right of the dorsal fin, extending from the level of the gills to the base of the caudal fin. Make a similar ventral incision, going around the cloaca. Exercise care not to cut the deeper structures, by making the incisions only skin deep. Remove the skin from the left pectoral fin and girdle. Do not remove the girdle from the specimen as the blood system may be injured by so doing.

Observe that the fin is movably articulated with the strong *pectoral girdle.* Expose the cartilages by carefully dissecting away the muscles, and examine the structure of the girdle. Are the opposite halves joined ventrally or dorsally? How many separate cartilages are included in each half of the girdle? The most dorsal portion is the *supra-scapula;* the scapular region is between the supra-scapula and the articulation of the fin; and the part ventral to the fin is called the *coracoid.*

The deeper part of the fin is supported by three basal cartilages, the *pro-*, *meso-* and *meta-pterygium.* The prefixes of the names indicate the positions of the parts. Distal to these cartilages are many smaller radial cartilages, and distal to these the fin is supported by horny dermal rays.

6. Skeleton of the Pelvic Fin. Skin and dissect the pelvic fin and girdle. What is the shape and position of the girdle? Is it attached to the vertebral column? There is only one basal cartilage. In the male a posterior elongation of this cartilage forms the support of the clasper.

7. Skeleton of the Caudal Fin. Observe that the vertebral column bends sharply upward in the caudal fin. The lower lobe is supported by short cartilages, with terminal dermal rays. This is a *heterocercal* tail, the two lobes being asymmetrical and the vertebrae continuing to the dorsal end of the tail.

C. Chondrocranium and Visceral Arches

1. The cranium of the dogfish, like its other skeletal structures, is formed entirely of cartilage. For this reason, specimens must be kept moist at all times. Moreover, they are extremely delicate and must be handled with the greatest care.

2. In development the cranium arises as five separate pairs of cartilages. One pair forms along the notochord, and is called the *parachordal cartilages.* What is the meaning of this term? Anterior to these is another pair, the *prechordal cartilages, or trabeculae.* The other pairs of cartilages arise around the sense capsules: (a) the *nasal* or *olfactory capsules* around the olfactory sacs; (b) the *optic capsules* around the eye; and (c) the *otic capsules* around the internal ear. With the exception of the optic capsules, which form the sclerotic layer of the eye, these separate cartilages fuse in the adult so that they cannot be exactly distinguished. However, they may be identified in a general way.

3. Orient the cranium so that the dorsal surface is uppermost. When this is done, the elongated structure (rostrum) at the anterior end will lie with its concave surface upward. Constant reference should be made to demonstrations of hemisected heads and to chondrocrania with the jaws and branchial arches attached. In working specimens, the jaws and arches are missing.

4. Dorsal Surface.

a. The *rostrum,* which supports the soft tissues of the snout, opens dorsally by the *anterior fontanel.* At the base of the rostrum the cranium widens abruptly.

b. On the anterior surface of the widened portion of the cranium, and below the posterior angle of the rostrum, are the thin-walled *olfactory capsules,* in which the olfactory sacs are enclosed. If these have been broken, refer to the demonstration specimens.

c. At the level of the olfactory capsules, immediately posterior to the anterior fontanel, is the median, unpaired opening, the *epiphyseal foramen.* This will be mentioned further under the discussion of the brain.

d. On the lateral surface, posterior to the olfactory capsule, is a large cavity, the *orbit.* Projecting into this cavity is some-

times found a mushroom-shaped structure, the *pedicel*, which in life supports the eyeball. The dorsal edge of the orbit is formed by an overhanging ledge, the *supraorbital ridge*. The anterior and posterior angles of the orbit are called the *pre-* and *post-orbital processes*.

e. In the mid-dorsal line of the posterior part of the cranium is a small depression containing two pairs of openings. The larger of these is for the perilymph, and the smaller for the endolymph ducts, both of which connect with the internal ear. Was there any indication of these ducts on the exterior of the animal? The depression with its openings is called the *endolymphatic fossa*.

f. On either side of this fossa is the *auditory* (*otic*) *capsule*, a region of heavy cartilage containing the internal ear.

g. On the posterior end of the cranium is a large opening, the *foramen magnum*. What is its function? Below and lateral to this on either side is an articular surface, the *occipital condyle*. These are for articulation with the first vertebra.

5. Lateral and Ventral Surfaces.

a. The ventral surface of the rostrum bears a *carina* or *keel*. What is the advantage of this structure?

b. On either side of the keel is an opening, the *rostral fenestra*. Through these openings one can look into the cavity of the cranium, which contains the brain in the living animal.

c. Again note the olfactory capsules. Probably the thin walls have been broken. When intact, the walls of this structure form an incomplete sphere, with a small external and a larger internal opening. Note that the latter connects the cavity of the capsule with the cavity of the cranium. Would you consider that Squalus has a good olfactory sense?

d. The ventral wall of the cranium is rather narrow between the orbits. It is here that a process from each half of the upper jaw lies in contact with the cranium.

e. The posterior portion of the ventral surface forms the *basal plate*. This is traversed by a median lighter-colored streak, caused by the notochord. With this in mind, distinguish the regions that arose from the parachordal, prechordal, and other cartilages.

f. The ventral half of the lateral surface of the otic capsule is

occupied by a depression in which the *hyomandibular bar* articulates.

6. Foramina. Locate the following foramina, and recall, or find in reference books, the function of the structures which occupy the openings.

a. The olfactory pit, for the olfactory nerve (Nerve I), has been noted in connection with the capsule.

b. In the orbit locate: (1) In the anterior-ventral region, the large *optic foramen* (Nerve II). (2) In the posterior ventral part, find the single foramen for Nerves V, VI, VII. (3) Directly in front of the preceding, is a small opening for Nerve III; and in the median dorsal part of the orbit is a very small opening for Nerve IV.

c. At the posterior end of the cranium are two very large foramina on either side of the foramen magnum. The mediad ones are for Nerve X, and the lateral pair are for Nerve IX. Where is the Eighth Nerve?

d. The *epiphyseal foramen* on the dorsal surface has been located. Lateral to this opening, piercing the supraorbital ridge, is a large foramen for the ophthalmic branch of Nerves V and VII as it passes from the orbit to the tissues of the head. Extending backward along the ridge is a row of small foramina for nerves and blood vessels.

7. Visceral Skeleton. The visceral arches may be seen to good advantage on demonstration specimens. They are of fundamental importance. Each visceral arch is made up of several pieces of cartilage. In Squalus and most other Elasmobranchs there are seven arches, although in some genera there are more.

a. The most anterior of the visceral arches has become highly modified to form the *jaws*. The upper jaw, or *pterygo-quadrate bar*, has a small process extending into the mediad portion of the orbit. It is articulated posteriorly with the lower jaw, or *Meckel's cartilage*.

b. The second, or *hyoid arch*, is also highly modified. The dorsal portion, extending between the cranium and the posterior end of the pterygo-quadrate bar, is the *hyomandibular*. The ventral portion, consisting of two parts on either side, is the *hyoid* proper. It extends ventrally, anteriorly and mediad to join its mate from the opposite side.

c. The remaining five arches function as gill supports, and are called the *branchial arches*. The gill slits are, therefore, between the bars of cartilage. This relationship will be seen clearly during the dissection of the vascular system.

d. Note especially how the upper jaw is attached to the cranium. In the Elasmobranchs it is not fused, but is simply suspended by the hyomandibular. The previously noted process of the upper jaw slides freely, and acts as a guide to limit side motion. Thus, both jaws are movable, the upper having less freedom than the lower.

8. Add foramina, and label the structures in the outlines:

a. *Dorsal* view of the chondrocranium.

b. *Lateral* view to show the relation of the jaws, hyomandibular, and hyoid to the cranium.

9. Discussion. The chondrocranium is not limited to the Elasmobranchs, but is found in the embryos of all the classes of vertebrates. That of the Dogfish is used because it is more easily available. It is more complete than that of the higher forms, since these usually do not have dorsal walls, except for a narrow arch in the posterior region of the skull. In all vertebrates, except the Elasmobranchs, the skull is derived from two sources: (a) a part arises as an ossification of the chondrocranium which has previously been formed, and (b) the remainder from bones that are formed separately and become attached to the outside of the chondrocranium. Classification of bones in a study of the skull is based on this difference in origin.

A knowledge of the general features of the visceral skeleton is necessary for a clear understanding of structures to be studied in connection with the evolution of the skull. Later we shall follow the evolution of the pterygo-quadrate bar and Meckel's cartilage, showing the addition of sheathing bones to them, and changes in these added bones; and also the evolution of the hyomandibular into a part of the auditory apparatus of the higher forms.

Thus, in the Dogfish, we have an indication of the structures of the primitive ancestors of the vertebrates which have given rise to those found in the higher forms. These evolutionary changes will be followed later in some detail.

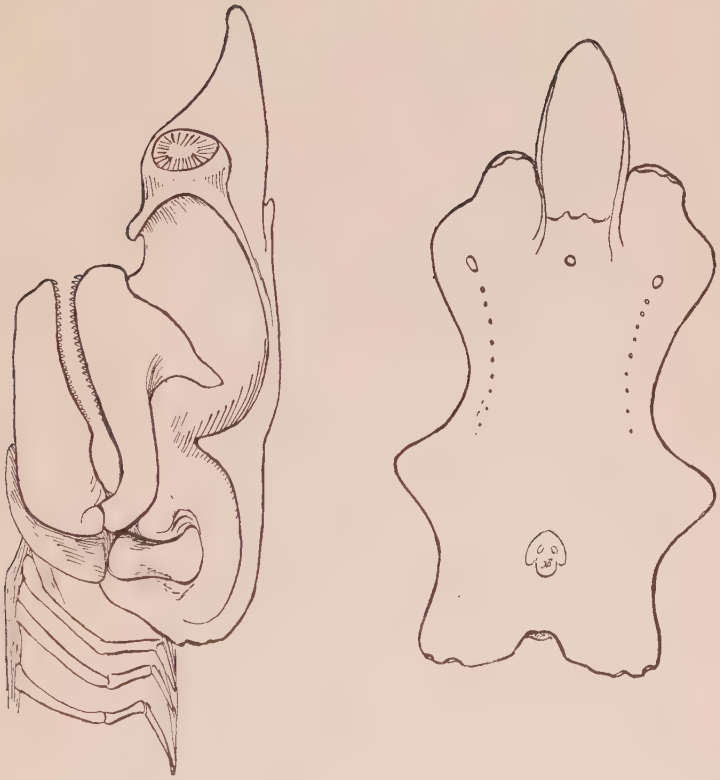

PLATE 4. Dorsal and lateral views of the dogfish chondrocranium. The lateral view shows the jaw and hyoid cartilages. Label the drawing.

D. Musculature

1. Skin the right side of the fish from the posterior border of the gill slits to the end of the tail. To do this, connect the dorsal and ventral incisions with a lateral one anterior to the pectoral fin, and beginning at the ventral intersection work upward and backward, pulling the skin from the muscles. This can usually be accomplished without the use of a knife. If the muscles at the lateral line tear, begin dorsally and work downward to this point.

2. Body Muscles. Observe the arrangement of the muscles of the trunk. Observe that the zigzag bands of muscles, or *myomeres*, extend from the mid-dorsal to the mid-ventral line. Note the relation of the myomeres of the two sides. What was the shape of the myomeres in Amphioxus? What are the important differences between the condition of Amphioxus and that of Squalus? Along the middle of the side of the animal is a white line extending longitudinally. This is the septum that divides the dorsal *epaxial* from the ventral *hypaxial* portion. Other septa, the *myosepta*, separate the myomeres, and it is to these that the muscle fibers are attached. What is the direction of the muscle fibers in a typical myomere? Where the tail of the animal was cut off, look at a cross-section of the muscles and note that the myomeres are cone-shaped, giving a "cone-in-cone" arrangement.

3. Muscles of the Pectoral Fin. On the left side of the body, where the superficial muscles were cut away, observe that the metameric arrangement of the muscles is present in the fin region, although covered by other muscles. As the fin serves as a balancer only, its function and musculature are very simple.

a. Ventral Surface: The *depressor-protractor* is the only muscle to be located. It arises from the girdle near the midline of the ventral side of the body. Locate its attachment on the fin, and determine its function.

b. Dorsal Surface: The *levator-retractor* originates on the scapula, together with a superficial mass from the body musculature, and spreads distally over the dorsal surface of the fin. Move the fin and determine the action of this large muscle mass.

4. Muscles of the Pelvic Fin.

a. Ventral Muscles: Two groups of muscles will be found, one extending from the body to the fin; the other limited to the

fin. The former is the *adductor* muscle and draws the appendage to the body. It is attached to the posterior side of the girdle, and the inner side of the basal cartilage of the fin. The *depressors*, which draw the distal portion of the fin downward, are a group of muscles, each bundle corresponding to a cartilaginous ray. These bundles arise from the basal cartilage and insert on the distal ends of the ray.

b. Dorsal Muscles: Pull the fin upward and observe the *abductor* muscle which arises from the trunk and inserts into the covering of the muscles of the fin. These latter muscles are arranged in a manner similar to the depressors of the ventral surface, and have a function antagonistic to them.

E. Digestive System

1. Just to one side of the mid-ventral line make an incision from the pectoral to the pelvic girdles, opening the body cavity. Locate the *lateral veins* on the inner surface of the abdominal wall. Now make a transverse incision at both ends of the first cut, extending it only to the lateral veins. This will permit the muscles of the body wall to be folded back.

2. Observe the following internal structures:

a. The *peritoneal cavity*, or *coelom*, with its smooth lining, the *somatic layer* of the *peritoneum*. Closely adhering to all the organs is a similar layer, the *splanchnic layer* of the *peritoneum*. The two layers, somatic and splanchnic, are connected by the mesenteries which attach the visceral organs to the body wall. Portions of the splanchnic layer extending between the organs are called *omenta*, or, in some cases, *ligaments*.

b. The *liver* is the large dark organ extending from the pectoral girdle half-way to the pelvic. Note its attachment to the ventral body wall by a short heavy mesentery, the *falciform ligament*. There are two large lobes of the liver, the *right* and the *left*, with the small *cystic* lobe between them. The latter contains the *gall bladder*. Find the *bile duct*, which extends from the gall bladder to the duodenum, and enters the latter slightly caudad to the bend.

c. Under (dorsal to) the liver, and partially enclosed by its lobes, is the J-shaped *stomach*. The larger part is the *cardiac*, and the smaller the *pyloric portion*. At the end of the latter

notice a constriction, the *pylorus*, which is the seat of a sphincter muscle controlling the passage of food into the intestine.

d. The major part of the intestine may be called the "small intestine." It is divided into two parts: (1) a very short portion, the *duodenum*, extending from the pylorus to (2) a much larger region characterized by rather evenly spaced circular blood vessels. The latter part, sometimes called the *ileum*, contains the *spiral valve*, a spiral fold of tissue that greatly enlarges the absorptive area.

e. Just posterior to the end of the small intestine is a very slight enlargement known as the *colon*, which in the mammals forms the large intestine. Posterior to this swelling is the *rectum*, which opens into the cloaca by the *anus*.

f. Dorsal to the rectum is the "rectal gland", an elongated cylindrical structure suspended by a separate mesentery. Its function is unknown.

g. At the bend of the pyloric stomach is a dark "heart-shaped" organ, the *spleen*. This is not a part of the digestive system, but is an organ connected with the vascular system.

h. At the bend of the duodenum is a flat, circular, whitish organ, the *ventral lobe* of the *pancreas*. This location is characteristic of the organ. The *dorsal lobe* is much more elongate than the ventral, and will be found extending along, and dorsal to the duodenum and the pyloric stomach. The *pancreatic duct* may be found by picking away the pancreatic tissue near the posterior margin of the ventral lobe. Trace it into the intestine.

3. Open the stomach by making an incision from the anterior limit of the cardiac region to the pylorus. Insert a long dull instrument into the mouth. Where does it reappear? The connection between the mouth and the stomach is the *esophagus*. Wash out the stomach and observe the character of the walls. What is the function of the ridges? How does the size of the cavity, or *lumen*, of the cardiac compare with that of the pyloric portion of the stomach? Can you explain this difference?

4. Cut open the pylorus and duodenum. How do the walls of the latter compare with those of the stomach? Note the muscular walls of the pylorus.

5. Slit open the walls of the small intestine to expose the spiral valve, which should be washed in a gentle stream of water. Be careful not to destroy the large blood vessels that are attached to this portion of the intestine. Immerse the animal in water and study the valve. What is the course of food? Do the blood vessels that encircle the walls of this part of the intestine have any relation to the septa of the valve? What is the significance of this fact? Is there any functional similarity between these septa and the folds of the wall of the stomach? Of what physiological advantage are they? Is the valve concerned mainly with absorption or with secretion? The stomach?

6. Cut off the end of one of the lobes of the liver and study its structure. Note its spongy, fibrous texture. This is important, as this appearance is characteristic of liver tissue.

7. Draw: A ventral view of the digestive system. In order to do this, some of the organs, such as the liver, should be displaced to one side. Before drawing, arrange the organs so that they may all be seen. The internal morphology of the cardiac and pyloric portions of the stomach, the pylorus, duodenum, and ileum should be shown accurately by drawing them as if seen in longitudinal section. The outline provided gives the detail of the mouth and cloacal regions, which cannot be dissected at this time.

F. Circulatory System

1. Paragraphs two to seven inclusive are designed to give a general survey of the vascular system. More detail is given after the student has first obtained a working knowledge of the various systems and their relationships to one another.

2. Study the following general description of the course of the blood: Starting at the *heart,* just anterior to the pectoral girdle, the blood passes through the *afferent branchial arteries* to the *gills,* where the vessels break into *capillaries,* very small vessels with extremely thin walls. After passing through the gills, the blood is re-collected by *efferent branchial arteries,* which unite to form the *dorsal aorta.* This vessel carries the blood posteriorly to the visceral organs and the muscles of the body. As it passes down the mid-dorsal line, it gives off several branches; some large unpaired ones to the viscera, and many smaller paired ones to the body

PLATE 5. Outline of coelomic cavity and gills of Squalus (Dogfish). The digestive and respiratory tract can be filled in and labelled. The upper end of the esophagus is shown as it leaves the pharynx. The pharyngeal openings of the gill slits are illustrated.

wall. Some distance anterior to the cloaca, the aorta dips into the vertebral column and continues into the tail as the *caudal artery*. Recall its position in the tail vertebrae. In the muscles and viscera the arteries again break into capillaries, and the blood is re-collected by the *veins*. Remember, however, that the blood is always contained within vessels, and there is no sharp break between small arteries and veins and the capillaries. The veins of the posterior region carry blood to the heart by three main routes:

a. Blood in the muscles may be collected by three veins, the two *lateral abdominal* (or simply "lateral") *veins*, and the *ventral cutaneous*. These veins pass along the body wall, partially embedded in the muscles, and empty into the heart.

b. Blood is carried from the tail region by the *caudal vein*. This splits to form the two *renal portal veins*, which pass into the kidneys where the vessels break into capillaries. The blood is collected from the kidneys by the *posterior cardinal veins* and carried to the heart.

c. Blood from the viscera (stomach, intestine, etc.) is collected and carried by the *hepatic portal vein* to the liver, where the vessel breaks into capillaries. This blood is then carried to the heart by the *hepatic veins*.

Note that in two of these three routes the veins break into capillaries before the blood is finally emptied into the heart. This is an important point as will be seen later. This description applies to blood that passes down the dorsal aorta to the posterior part of the body. However, some of the blood that passes into the gills is carried *anteriorly* by the *carotid arteries*. The blood that thus passes to the brain, muscles of the head, etc., is returned to the heart by means of two pairs of veins, the *anterior cardinals* and the *jugulars*.

3. With this general description in mind, proceed in accordance with the following directions:

a. Extend the median ventral incision through the pectoral girdle and the region immediately anterior to it, thus opening the *pericardial cavity*, a portion of the coelom cut off to contain the heart. Identify the thick-walled *ventricle*, and dorsal to it the thin-walled *auricle*. This extends to either side of the ventricle, and may appear to be paired. Posterior to the

auricle is the very thin-walled *sinus venosus,* which is extended laterally as the *ducts of Cuvier.* What is the course of blood in these structures?

b. Extending anteriorly from the ventricle is the elongated, muscular *conus arteriosus.* This continues forward as the *ventral aorta,* which divides to form the *afferent branchial arteries.* Do not dissect out the ventral aorta at this time.

c. Recall that the blood is collected from the gills by the *efferent branchial arteries,* and that these join to form the *dorsal aorta.* Find the latter on the mid-dorsal line, just posterior to the pectoral girdle. Trace it posteriorly and find the following large unpaired arteries that are given off: (1) the *coeliac artery* (coeliac axis) to the stomach, intestine, liver and pancreas, (2) the *anterior mesenteric* arises near (3) the *gastrosplenic.* The anterior mesenteric artery is usually the more anterior, and supplies the left side of the ileum; the gastrosplenic goes to the spleen, pancreas, and loop of the stomach. The order of these two vessels is occasionally reversed. (4) The *posterior mesenteric* leads to the rectal gland. Find where the dorsal aorta dips into the vertebrae to continue as the *caudal artery.* In well injected specimens, small *parietal arteries* may be seen extending from the dorsal aorta to the body wall, and small *renal arteries* to the kidneys.

4. Systemic Veins. By this name we designate those vessels which empty into the heart. On the dorsal surface of the heart, locate the *sinus venosus.* It has already been noted that the sides of this are extended laterally as the *Cuvierian ducts.* Open both the sinus and the ducts of Cuvier by a transverse ventral incision. By means of the bristle-probe, locate the following openings and the vessels belonging to them:

a. The ducts are continuous posteriorly with the *lateral veins.* Trace these as far posteriorly as possible. Find the *subclavian vein,* draining the pectoral fin and entering the lateral vein immediately posterior to the pectoral girdle. The blood from the pelvic fin enters the lateral vein by means of the *femoral vein.* The lateral veins finally unite posterior to the cloaca.

b. A large opening on the posterior wall of each Cuvierian duct leads into the *posterior cardinal vein.* Trace these along the mid-dorsal line. It will be found that they originate from the

very elongate *kidneys*, which lie on the dorsal wall covered by somatic peritoneum.

c. On the anterior wall of each duct of Cuvier is the small opening of the *inferior jugular*. Note its location, but do not dissect it out.

d. Often, lateral to these, are two larger openings, those of the *anterior cardinals*. More frequently, however, these veins empty into the postcardinals rather than directly into the ducts. Again note the position, but do not dissect the veins at this time.

e. On the posterior wall of the sinus is a small opening (sometimes two) of the *hepatic veins*. Trace these posteriorly into the liver. In doing so, it will be necessary to remove some of the liver tissue. When this is done, a large space, the *hepatic sinus*, will be found in the anterior part of each of the large lobes of the liver. What is the shape of these structures? Their function?

5. Hepatic Portal System. By a "portal" vein is meant one which breaks into capillaries before reaching the heart, the blood being re-collected from the capillaries and taken to the heart by a systemic vein. Running parallel to the hepatic artery and the bile duct, and enclosed in the same connective tissue sheath, will be found the *hepatic portal vein*. What portion of the viscera does it drain? How many main branches fuse to form it? What is the functional advantage of the distribution of this system?

6. Renal Portal System. Posterior to the cloaca find the *caudal vein*. Trace it anteriorly, and notice that it branches around the cloaca. In dissecting, be careful not to injure the cloaca or kidneys. After the caudal vein splits, the parts are called the *renal portal veins*. These carry blood to the kidneys. What veins carry the blood from the kidneys to the heart?

7. Afferent Branchial Arteries.

a. The *conus arteriosus* is continued anteriorly as the *ventral aorta*. Carefully cut away the tissue lying ventral to this artery. There are lateral branches from the aorta that must not be destroyed. For paragraphs seven and eight, use only one side of the animal, leaving the other intact for use under paragraph ten.

b. Expose and separate the gills by removing the skin and muscles on the *right* side of the head. Note the sacs or *gill pouches*, opening into the pharynx and to the exterior by the *internal* and the *external gill slits*. On either side of the pouch is a *half-gill*, or *hemibranch*. A complete gill is composed of the adjacent hemibranchs of contiguous pouches. Note the richly vascular *gill filaments*, of which the hemibranchs are largely composed. The two hemibranchs arise from the branchial arch and are separated by the *branchial septum*, which extends from the arch to the exterior. The gill pouches are numbered from anterior to posterior. The spiracle is considered as the first, so the five similar pouches are the second to the sixth, inclusive. Do all the pouches have two hemibranchs?

c. The ventral aorta passes forward, giving off the *afferent branchial arteries*, which carry unaërated blood to the gills for aëration. There are three afferent arteries given off on either side. The most posterior leaves the aorta close to the pericardium, the most anterior at the termination of the aorta, and the other about halfway between these two. These arteries pass into the septa. Do all of them divide? How many hemibranchs are supplied by each artery? Trace the arteries along the base of the gills and determine their exact relation to the filaments.

d. Make a diagram showing these arteries, their branches, both large and small, and their relation to the gills and gill filaments. *Be sure that this diagram is correct before going further*, as the work on the efferent arteries destroys this dissection.

8. Efferent Branchial Arteries.

a. Expose the mouth cavity by making an incision just to the right of the mid-ventral line, cutting through the jaw, muscles, and pectoral girdle, and laying back the flap thus formed. Identify the internal opening of the spiracle. Find the short esophagus. Notice the internal gill slits, protected by small cartilaginous projections, the *gill rakers*. Is the axis of the gill pouch at right angles to the axis of the body? Carefully expose the *efferent branchial arteries* by removing the mucous membrane from the roof of the mouth and clearing away the connective tissue.

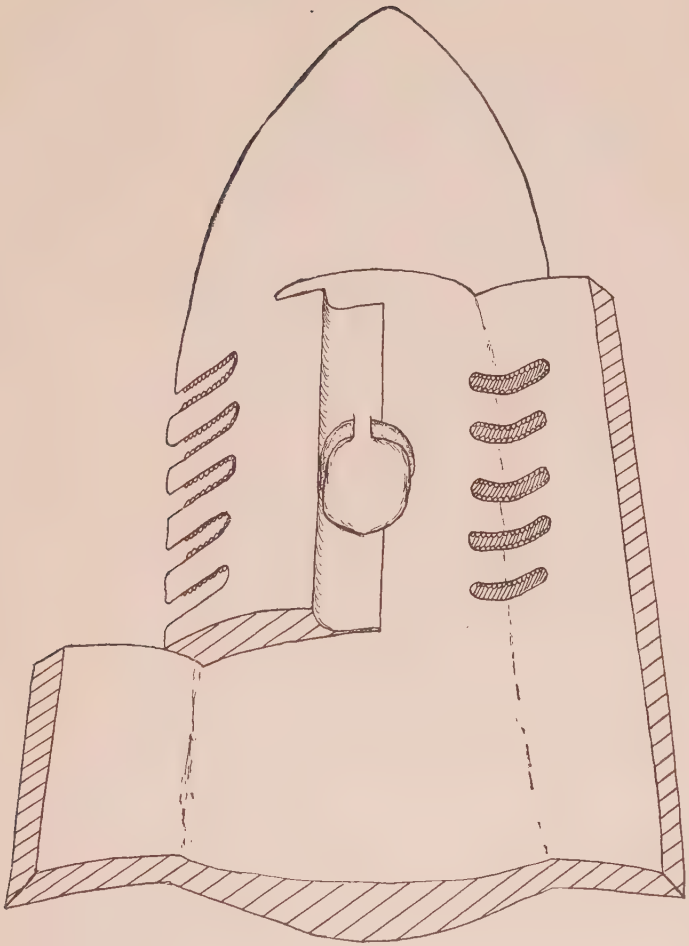

PLATE 6. Drawing of the anterior end of Squalus. The body wall of the left side is laid back; the right side of the pharyngeal region is left in place, with the heart indicated. Draw in the branchial arteries, the afferents on the right side (of the animal) and the efferents on the left.

b. Trace the vessels away from the mid-line to where they disappear, dorsal to the cartilages of the branchial arches. To remove these cartilages, carefully separate the cut end from the surrounding tissues. Then grasp the end, and loosen the cartilage toward the mid-dorsal line, thus revealing the efferent artery.

c. Trace the artery toward the gill. Note that each vessel arises as a fusion of two, the small *pre-trematic* from the hemibranch on the anterior face of the gill pouch, and the larger *post-trematic,* which comes from the hemibranch on the posterior surface. Have all the pouches both these vessels? Is there any connection between the pre- and post-trematic of a single pouch? Of adjacent pouches? Note the small vessels that come from the gill filaments. From how many hemibranchs does each efferent branchial artery collect blood? How is the blood carried away from the hemibranch of the sixth gill pouch?

9. Arteries of the Head.

a. At the dorsal angle of the second branchial arch, note an artery running anteriorly on the roof of the mouth. This is the *common carotid.* After a short distance, it bends toward the mid-line. At the bend there is given off an artery that penetrates the cartilage. This is the *external carotid,* which runs outward to the eye region, to the lower jaw and to the snout. The main vessel, now called the *internal carotid,* passes to the mid-line where it anastomoses with the vessel from the other side. These then break apart, forming an X-shaped connection. The vessels then penetrate the cranium to the brain.

b. At the middle of the pre-trematic branch of the first efferent branchial artery, find a branch running anteriorly. Note that this bends sharply dorsally in the general direction of the spiracle. Turn the animal over and remove the skin around and posterior to the spiracle. Carefully shave off some of the cartilage posterior to the opening and find a continuation of the same vessel, the *hyoidean* artery. Trace it to the spiracle and notice the small branches given off to the rudimentary gill filaments. This artery is then continued as the *ventral carotid,* passing into the cranium in the posterior-ventral

region of the orbit, and, when inside, fusing with the internal carotid. This artery need not be followed after it leaves the spiracle.

c. An extremely fine vessel may be found extending from the carotid to the first efferent branchial artery. This unimportant branch is sometimes called the "vertebral artery". It is mentioned only to prevent confusion and may be ignored.

d. Find the small *coronary artery* that arises from the ventral end of the efferent loop around the third gill pouch. The main branch of this artery runs posteriorly, and furnishes blood to the walls of the conus arteriosus, heart, and pericardium.

10. Veins of the Head. In the Cuvierian ducts again find the openings of the inferior jugular and the anterior cardinal. Trace the veins forward on the uninjured side of the head. What is their distribution?

11. Arteries from the Dorsal Aorta. As before, find the dorsal aorta in the region of the pectoral girdle. Work out the following branches of this vessel:

a. Between the points where the aorta is joined by the third and fourth efferent branchial arteries, the *subclavian* arteries are given off to the pectoral fins. Each subclavian gives off a small branch, the *lateral* artery, which passes along the body wall at the level of the lateral line. More distally the subclavian gives off the *ventral abdominal* artery, which passes posteriorly between the mid-ventral line and the lateral artery. After giving off this branch, the subclavian, now called the *brachial*, passes into the fin.

b. The coeliac artery, near its origin from the dorsal aorta, sends two branches to elongate whitish structures suspended to the dorsal body wall. These organs are the *gonads* (*ovaries* or *testes*) and the vessels are the *genital* arteries. The coeliac then splits into two main branches: (1) the *gastro-hepatic*, which again divides into the hepatic (to the liver) and the *gastric* (to the cardiac stomach); and (2) the *anterior intestinal* supplying the pyloric stomach, duodenum, pancreas, and right side of the ileum.

c. The distribution of the *anterior mesenteric* and the *gastro-splenic* arteries should be worked out in detail.

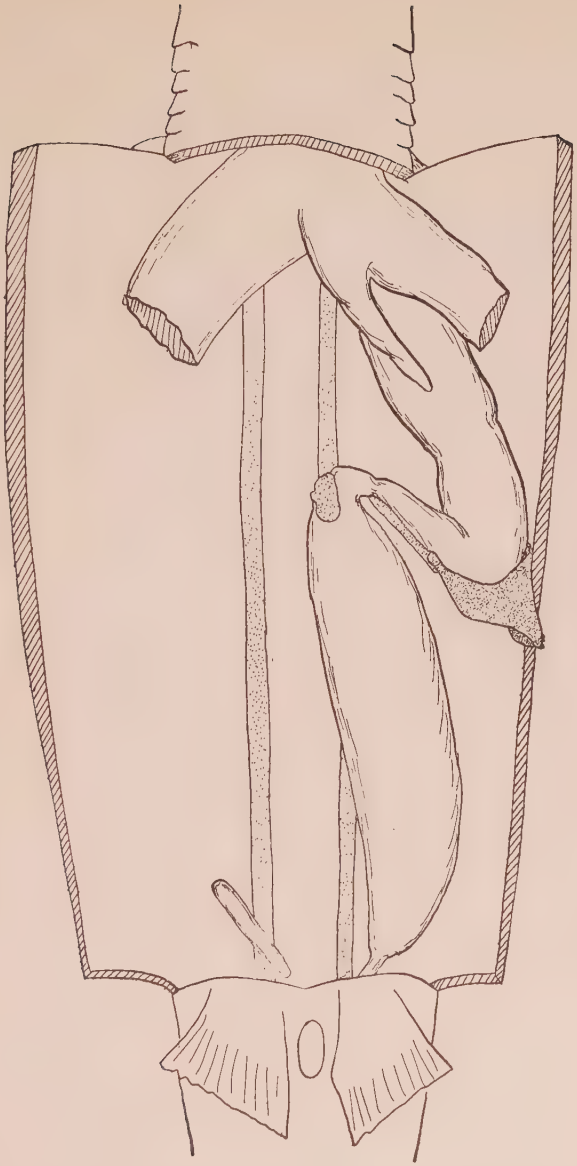

PLATE 7. Outline of coelomic cavity of Squalus, with a diagrammatic drawing of the viscera. Draw in the blood vessels of the body, showing their position on the viscera. The branchial arteries should be shown on a different page.

d. The *posterior mesenteric* artery goes to other organs than the rectal gland. What are they?
e. Review the distribution of the *parietal* and the *renal* arteries. Are the parietal arteries metameric?
f. Close to the cloaca the dorsal aorta gives off the *femoral* arteries to the pelvic fins. Do not dissect them, as the structures around the cloaca would be ruined by so doing.

12. Structure of the Heart. Remove the heart with as much of the sinus venosus and the ventral aorta as possible. Make a sagittal section through the conus arteriosus and the heart. Wash out the injecting mass and coagulated blood that may be present. Note the difference in the thickness of the walls of the sinus, auricle, ventricle and conus. Find the opening from the sinus into the auricle and the one from the auricle into the ventricle. The latter is guarded by two valves. When there is a back pressure from the ventricles, these valves close and prevent the flow of blood in any direction except anteriorly. On the walls of the conus notice the series of *semilunar valves.* What is their shape? Number? Mechanics?

13. Drawing. Using the outlines provided, make a complete and accurate drawing of the circulatory system. Be careful to show accurately the relative size of the various vessels. Where vessels dip beneath organs, indicate their course with dotted lines. Place small arrows beside the vessels to show the direction of the flow of blood. Indicate any vessels that you were told not to dissect, but label them "diagrammatic", as they have not been seen.

G. Urinogenital System

1. The excretory and reproductive systems are so closely allied both in development and in structure, that they are studied together as the urinogenital system. In the embryo there is an undifferentiated stage when the sexes are practically alike. Those ducts that are present in the adult female, but absent in the male, at one time are present in both sexes. Very often the ducts that later degenerate are seen in laboratory specimens as vestigial structures. Remember that in all studies of the urinogenital system *both sexes must be studied.*

2. The Male.

a. The *kidneys* are elongate, strap-shaped organs, lying outside the somatic peritoneum, and extending along the mid-dorsal line the entire length of the body cavity. Each is divided into two portions: an anterior narrower portion, the *cranial mesonephros*, which apparently has no excretory function; and the posterior larger *caudal mesonephros*. Embedded in the tissue of the latter portion is an *accessory mesonephric duct*, which carries waste products to the cloaca. This tube runs parallel to the Wolffian duct, and opens close to the openings of the latter. (Often this posterior part of the kidney, because of this duct, is called metanephros, but this is unjustifiable.)

b. The *testes* lie dorsal to the liver, and close to the mid-line. Each is suspended by a mesentery, the *mesorchium*.

c. On the medial edge of the kidney find the white convoluted *Wolffian duct*. In young specimens there will be few convolutions. Do not confuse this duct with a paired strand of connective tissue that is found very close to the mid-line. Trace the Wolffian duct anteriorly to the region of the testes. Hold the animal so that the light passes through the mesorchium. Notice the fine tubules leading from the testis into the cranial mesonephros (sometimes called the *epididymis*). These tubules are the *vasa efferentia*, which carry spermatozoa from the testis to the Wolffian duct. Do not confuse the tubules with the larger blood vessels also found in the mesorchium.

d. Open the cloaca by inserting one blade of a pair of scissors into the rectum and cutting through the tissues ventral to it. If it is found to be necessary later, the rectum may be removed. Do not injure the *urinogenital papilla*.

e. Note the enlargement of the Wolffian ducts just anterior to the papilla. These are the *seminal vesicles*, and are probably simply reservoirs for the storage of sperm.

f. On the papilla find the terminal, median *urinogenital pore*. Within the papilla is a cavity, the *urinogenital sinus*. With your finest scissors open this, and with the aid of a hand lens, locate the openings of the Wolffian and accessory mesonephric ducts.

g. Vestigial *Müllerian ducts* are sometimes present, lying parallel to the Wolffian ducts.

3. The Female.

a. The *ovaries* lie dorsal to the liver. In sexually immature animals the ovaries are no larger than the testes of the male, but have a nodular appearance. In the mature female the ovaries are very much larger. Each ovary is suspended by a mesentery, the *mesovarium.*

b. Dorsal to the ovary is a white tube, the *Müllerian duct,* which arose in development by a splitting of the pronephric duct. There are no connections in the mesovarium between the ovary and this duct. Trace the duct around the anterior end of the liver to where it joins its mate from the other side. This junction is found in the falciform ligament, ventral to the liver. The two ducts have a common funnel-shaped opening, the *ostium,* facing posteriorly into the coelom. How do the eggs get from the ovary into the oviduct?

c. Trace the Müllerian ducts caudad. In mature specimens there is a slight enlargement, the *"shell gland"*, and then the duct returns to its former size. About half its length is greatly enlarged to form the *uterus.* If this is noticeable, open it to look for embryos. These, if present, will have attached to them a large yolk sac, by which they are nourished during their life in the oviduct and for a time after birth.

d. Dissect out the *urinary papilla* as described for the male urinogenital papilla. The openings of the oviducts lie just anterior to the papilla.

e. The *kidney* is similar to that of the male. However, the cranial portion is not a part of the genital system, but a vestigial kidney. Find the Wolffian and accessory mesonephric ducts, and their outlets into the *urinary sinus.*

4. Discussion. The first portion of the embryonic kidney to arise is the *pronephros,* which develops anterior to the later portion, and covers only a few segments. It is in connection with this part of the kidney that the longitudinal *pronephric duct* is formed, connected anteriorly with the tubules of the kidney and posteriorly with the exterior.

The kidney of the adult, the *mesonephros,* develops posterior to the pronephros, extends over many more segments, and differs from it somewhat as to its detailed structure. A new duct is not

formed for carrying away its waste products, but its tubules grow into the pronephric duct already formed. This, however, has previously split lengthwise. The portion into which the tubules of the mesonephros extend is now called the Wolffian duct, and the other portion, having no connection with the kidney, is the Müllerian duct. The pronephros now degenerates, and with it that portion of the Wolffian duct that lies anterior to the mesonephros. It should be noted that it is only in the Elasmobranchs that the Müllerian duct is formed by a splitting of the pronephric duct. In all the higher forms, this duct develops entirely separately from the other duct.

Thus, in the embryo of both sexes, two pairs of ducts are formed. In the meantime, the gonad (ovary or testis) has developed. The tubules of the anterior part of the kidney (cranial mesonephros) in the male lose their renal character, become much elongated, and grow along the mesorchium into the testis. Here they connect with other small tubules already formed, thus producing a series of continuous ducts leading from the testis, through the mass of the anterior end of the kidney, into the Wolffian duct. These elongated tubules of the anterior end of the kidney are the *vasa efferentia*. In the female, the anterior region loses its renal character, but there is no pronounced elongation of the tubules, and no connections are made with the gonad.

The accessory mesonephric duct is a special modification, and is formed by renal tubules growing posteriorly instead of emptying into the Wolffian duct. In this respect, the kidney of the dogfish is specialized, but in its other characteristics it is considered to be primitive. The origin of the Müllerian duct, for instance, is supposed to be much more primitive in the Elasmobranchs than in the higher forms.

H. Brain

1. Dissection. Remove the skin from the top of the head, clearing away the muscle and connective tissue until the cartilage of the skull is exposed. Begin at the endolymphatic ducts and shave away the cartilage as far as the nasal sacs, thus exposing the brain. When the epiphyseal foramen is reached watch for the *epiphysis*, a thin strand of nervous tissue rising from the brain. Only a very general observation of the brain will be made at this time, detailed study being reserved until a direct com-

parison can be made with the brains of higher forms. (See Part XII.)

2. Dorsal Surface of the Brain.

a. At the anterior end of the brain two diverging cords, the *olfactory tracts*, extend forward to the *olfactory sacs*. At their distal end these nerve tracts pass into the spherical *olfactory bulbs*, which receive the stimuli giving the sense of smell. These tracts arise from the *rhinencephalon*, or *olfactory lobes* of the brain.

b. Dorsal and posterior to the rhinencephalon are the *cerebral hemispheres*. These are separated from the olfactory lobes by only a shallow groove.

c. Immediately posterior to the cerebra is a depressed region, the *diencephalon*, which is very narrow in the dogfish. It contains a plexus of blood vessels which causes it to become discolored in preserved specimens. On this portion is the *epiphysis*, or *pineal body*, which was observed when the chondrocranium was opened. In higher forms this organ has a glandular function; but in some amphibia and reptiles that are now extinct it seems to have functioned as a sensory organ, the "pineal eye".

d. Posterior to the diencephalon are the large, paired, *optic lobes*.

e. Covering the posterior part of the optic lobes is the oval *cerebellum*, the most prominent part of the brain.

f. Behind the cerebellum the brain becomes narrowed, forming the *medulla oblongata*. From the medulla arise the paired *corpora restiformis* which extend forward lateral to the cerebellum. The medulla passes insensibly into the spinal cord, the foramen magnum being the line of division between the cord and the brain.

3. Ventral Side of the Brain.

a. Remove the brain from its case. Cut the optic nerves close to the eyeball, and the spinal cord at the foramen magnum. Clear the membranes away, and lift the brain upward and forward.

b. Under the diencephalon lie the optic nerves which fuse at this point to form the *optic chiasma*.

c. Immediately posterior to the chiasma lie the two oval *mammillary bodies*, and between them the narrow *hypophysis*.

The latter arises from the diencephalon and extends backward over the thin-walled saccus vasculosus, lying behind the mammillary bodies.

4. Discussion. Embryologically the brain arises as an enlargement of the spinal cord. Two constrictions appear in the brain, dividing the structure into three vesicles: The *forebrain* or prosencephalon; the *midbrain*, or mesencephalon, and the *hindbrain* or rhombencephalon. Later, other divisions appear. The forebrain gives rise to the rhinencephalon, the cerebral hemispheres, and the diencephalon. The midbrain remains undivided and develops into the optic lobes. The hindbrain becomes divided into two major parts which form the cerebellum and the medulla with their outgrowths.

The student should again review the cranial nerves and their foramina in the skull, for in the study of the latter frequent reference will be made to the nerves. Under the section on the chondrocranium the ten cranial nerves were mentioned, this number being typical of the fish and amphibia. In the higher groups, twelve are present. For a study of the evolution of the skull it is also necessary to be thoroughly familiar with the major divisions of the brain, the epiphysis and the hypophysis.

I. Cross-Sections

1. After a study of the dogfish as a whole the student should be able to locate the region of any cross-section, the structures contained in the section, and the relationships of the structures to other sections. In order to get a grasp of the relationships, all the sections of the animal should be studied. The work will be left largely to the student's own initiative, the following suggestions and questions referring to the sections that should be drawn.

2. Section through the Eyes. What portions of the chondrocranium are sectioned? What part of the brain? Observe the structure of the eye. What is the large nerve that comes from the ventral portion of the brain?

3. Section through the Spiracles. Observe the structure of the spiracle, its lining membrane, and its entrance into the pharynx. Identify the cartilages ventral to the chondrocranium. From its

location, identify the structure buried in the cartilage on either side of the brain. What blood vessels are present?

4. Section through the Gills. Locate the ventral aorta. How many branches has it? Are any afferent or efferent branchial arteries present? How do you account for the number of gills which are present in the section?

5. Section through the Heart. Note the location of the heart in relation to the esophagus. Identify the parts of the heart. What veins are present? Just dorsal to the angles of the esophagus are the two large sinuses of the anterior cardinal vein. Study the structure of the lateral line.

6. Section through the Abdominal Region. Identify all the visceral organs that are present. Do you find the liver, gonads, spleen, pancreas, kidneys, Wolffian duct, Müllerian duct, pyloric and cardiac stomach, duodenum, ileum, rectum, rectal gland, haemal arch? If they are not in this section, would they be found in sections that are more anterior or more posterior?

7. Section through the Tail Region. What is the arrangement of the muscles? Name the parts of the vertebra. Locate the caudal artery and vein.

PART III

CLASSIFICATION OF VERTEBRATES

A. Method of Classification

1. Nomenclature. Living organisms are divided into plants and animals. Each group is then divided into great divisions, or *phyla*, a phylum including only animals which have certain fundamental characteristics common to all. The phylum is split into *classes* and the class into *orders*. The order is subdivided into *families;* the family into *genera;* and the genus into *species*. The classification, then, shows the biologist's idea of the closeness of the relationship between forms, and the group is made on the basis of similarity in structural characters, not upon similarity of appearance nor number of animals. Thus, animals which can hardly be distinguished in external appearance are in different orders; and the same order may contain forms which are utterly dissimilar in appearance. Again, one order may contain hundreds of genera, and another order be set up for a single species. It is well for the student to remember that classification at best is an arbitrary division, and that no two taxonomists agree on all points.

2. The following classification of man will give an idea of the widening range of similarities as the group narrows. After the ordinal characters of the vertebrates are learned this should be reviewed with the idea of tracing the relationships and also the wide range of forms included together.

Phylum—Chordata
Sub-phylum—Euchordata
Division—Vertebrata
Class—Mammalia
Order—Primates
Sub-order—Anthropoidea
Family—Hominidae
Genus—Homo
Species—sapiens

3. In writing scientific names a binominal nomenclature is used, giving the genus and species. The genus is written with a capital letter, the species with a small letter, thus: Homo sapiens. The family, order, and class are always written with capital letters.

B. Classes of the Chordata

1. Chordata. The phylum includes a group of animals which range from burrowing, worm-like animals up to the birds, man and the whales. They are placed together due to three distinctive characters which are found nowhere else in the animal kingdom: (1) a *notochord,* an elastic, gelatinous rod surrounded by sheaths, around which the vertebrae are laid down; (2) a hollow, *dorsal nerve cord;* and (3) *branchial* (*gill*) *pouches,* which are present in the embryos of all vertebrates, but which never function in the three higher groups.

The Chordata may be divided in several ways, depending on the authority's opinion as to the closeness of relationship between the separate groups. The authors believe that Amphioxus is more closely related to the true vertebrates than to the lower Chordates, and that the latter form two widely separated divisions. On this basis the following classification has been accepted, dividing the Chordata into three Sub-phyla:

Sub-phylum I. *Hemichordata:* Small, worm-like, burrowing animals with a structure commonly regarded as a notochord. The entire group consists of only a few genera, Balanoglossus and its immediate allies; and several forms not closely related but which do not fit into any other known group.

Sub-phylum II. *Urochordata:* The Tunicates or Sea-squirts. Sessile marine forms in which the adult is so degenerate that chordate affinities would be unknown but for a study of the larval history. The tadpole-like larvae have a well developed notochord in the tail region which is lost in the adult

Sub-phylum III. *Euchordata:* Amphioxus, an acraniate form, and all the true vertebrates. Amphioxus is often referred to as a "vertebrate" though it has no vertebrae. The group is clearly divided into two sections:

Division 1. *Acraniata:* Chordates without a cranium or skull. Amphioxus and a few closely related genera.

Division 2. *Vertebrata:* The craniate vertebrates. These have a more or less well developed cranium and verte-

brae. The brain is complex; the blood has red blood corpuscles; and most of them have appendages.

2. Classes of the Vertebrates.

Class 1. *Cyclostomata:* Lampreys and Hagfish, animals with round mouths and no jaws; horny, ectodermal teeth; no bone or dermal denticles; a single, median olfactory opening; an unconstricted notochord with very minute cartilaginous vertebrae; and a complete lack of lateral appendages.

Class 2. *Pisces:* The fishes, including Elasmobranchs and the bony fish. They have functional jaws with teeth; scales homologous with dermal denticles; and primitively two pairs of appendages.

Class 3. *Amphibia:* Frogs, Toads, and Salamanders; animals which pass through a gill breathing tadpole stage and later develop lungs. The first group of land vertebrates to appear in geological history. They have a smooth slimy skin.

Class 4. *Reptilia:* The Snakes, Lizards, Alligators and Turtles. Air breathing forms with ectodermal scales. They hatch from large-yolked eggs; the young never have functional gills, and they are born with the adult form. During embryonic life they have a fluid filled covering, the *amnion*, which distinguishes Classes 4, 5, and 6 from the earlier groups.

Class 5. *Aves:* The birds; vertebrates with feathers, with the forelimb useless for walking. Huxley described birds as "glorified reptiles". Recent birds have lost their teeth, but fossil birds were as well supplied as their reptile ancestors.

Class 6. *Mammalia:* Animals with milk glands and hair. They are warm-blooded. The class includes primitive egg-laying mammals, mice, pigs, men, whales, etc.

C. Laboratory Identification of Types

1. Lamprey.

a. The lamprey (Petromyzon marinus) is a cyclostome, and belongs to the most primitive group of the craniates. Many of its structures are highly specialized for its pseudo-parasitic habits; but the fundamental structures are very primitive and its larva links it with Amphioxus.

b. External anatomy: The body is eel-like in shape with little differentiation of regions. Observe the skin with its great

number of mucous glands, the absence of paired appendages, and the dorsal and caudal fins. The fins are supported by cartilaginous fin rays.

In the head region note the *buccal funnel*, surrounded with fleshy papillae. Inside note the yellow, horny teeth. At the bottom of the funnel is the mouth closed by the *tongue*, which also bears teeth. This is a rasping organ, not a true tongue, and has been thought to be the homologue of the lower jaw of higher animals. On either side of the head are the indistinct *eyes*, covered with a layer of transparent skin. At about the same level as the eyes is a dorsal, median opening, the *naso-pituitary* aperture.

The *gill clefts* are laterally placed, beginning just behind the eye. How many are there? The *anus* is in the median ventral line at the junction of the trunk with the tail. The latter occupies about one-fourth of the length of the animal. The *urinogenital papilla* lies with the anus in a slight depression. Compare the condition in Petromyzon with the urinogenital and anal openings of the bony fish and the salamander.

c. Sagittal section of Petromyzon: Locate the *notochord*, lying under the brain and nerve cord. It is a semi-transparent rod of tissue surrounded by brownish notochordal sheaths. The vertebral skeleton of cyclostomes is extremely rudimentary. The vertebrae are minute paired cartilages which do not fuse. The chondrocranium is unroofed, being an open trough in which the brain rests. Notice particularly the anterior limit of the notochord. This condition is typical of all vertebrates. Compare the condition in Amphioxus. Recall the axial skeleton of Amphioxus and Squalus, and note the intermediate position of Petromyzon. If the student wishes to study the skeleton small adults of Lampetra can be stained and cleared. (See Appendix II.)

Dorsal to the notochord is the nerve cord and brain, a whitish structure. At the anterior end of the brain is the dark *nasal capsule*, in which are located the olfactory sense endings. Observe the sac which surrounds it, and trace it dorsally to the naso-pituitary opening on top of the head. Next, follow the sac ventrally, past the olfactory bulb, to where it ends as a blind sac at the end of the notochord.

(In other Cyclostomes it opens into the pharynx.) This sac is considered the homologue of the anterior lobe of the pituitary gland.

In the pharynx are the internal openings of the gill pouches, which are sac-like in the Cyclostomes. The esophagus may be found dorsal to the pharynx, passing posteriorly into the straight stomach-intestine. Trace the latter to the anus.

Note the gonads, the testes being small white structures; the ovaries (during the breeding season) are greatly overgrown with dark eggs. Observe that the gonads have no ducts leading to the outside. The long white kidneys lie along the mid-dorsal line. Near the urinogenital papilla may be found the urinogenital sinus, an enlargement of the fused Wolffian ducts. There is an opening on either side through which the reproductive cells pass from the coelom to the outside. Compare Amphioxus and Squalus.

The outline gives the relationships of the structures and should be completed and labelled.

2. Perch or Herring.

a. Either may be used as a type of the bony fish. The more primitive Elasmobranch has been studied, and should be compared with this specimen.

b. The body is typical of aquatic animals in its fusiform shape, but is not so well adapted for swift motions in the water as is the dogfish. The fins are easily identified by analogy to the dogfish, except the anal which is a median ventral fin posterior to the anus. The structure of the caudal fin should be carefully noted. This is a *homocercal* type of tail. Can you determine the relation of the vertebral column to the fin?

c. The exoskeleton of the perch is composed of overlapping scales, homologous with the dermal denticles of the dogfish and the bones which cover the head of the bony fish. The latter have sunk below the skin, and form the roof and sides of the skull.

d. The mouth is anterior (compare the dogfish). The nostrils are paired, and like those of the dogfish are blind sacs. Are there lids to the eyes?

e. Attached to the skull is a heavy plate of bone covering the gills externally. This gill cover, or *operculum*, opens poste-

riorly to form an exit from the gills. Raise the operculum and observe the gills. Do the branchial septa extend to the exterior? The relationship of the two hemibranchs is clearer in this animal than in the Elasmobranch. Probe through the gills to the mouth to show the communication of the gills with the pharynx. During respiration the water is taken in through the mouth, over the gills, and out through the gill openings.

f. Observe the urinogenital papilla and the anus. Is there a cloaca? Which opening is anterior?

3. Tadpole.

a. The tadpole of the Frog (Rana) is used with the other types to show the larval, gill-breathing stage of the amphibia, one of the basic differences between the Amphibia and the Reptilia. The metamorphosis is never sudden, and in the later stages there are both functional gills and lungs.

b. Note the general aquatic body shape, the tail being about two-thirds of the entire body length. The skin is typically amphibian, with numerous pigment spots. The tail has a well developed, metameric muscular system, with a wide fold dorsally and ventrally and is the locomotor apparatus of the animal.

c. In the head region note the sucker-like mouth, the nasal pits, and the large eyes. There is little demarcation between the head and trunk.

d. On the left side, in the mid-body region, observe the *spiracle*, the sole outlet of the gills. In the early tadpole the gills were external. An operculum developed which soon united with the body wall, internal gills developed and the external gills shrivelled. "At this time the tadpole is to all intents and purposes a fish." (P&H)

e. At the juncture of the body with the tail find the anus, its opening being pushed to one side by the developing tail. The hind legs have probably made their appearance. The fore limbs are present, but hidden by the operculum. Compare a frog to understand the changes at metamorphosis. As the appendages develop the lungs increase in size and the gills disappear. The tail is gradually absorbed into the body and the animal comes out upon land, the metamorphosis being complete.

4. Salamander.

a. The salamanders are tailed amphibia, the name being a popular one, and not limited to the family Salamandridae. Amblystoma may be used as a type, but comparison should be made with the other Amphibia, particularly the newt (Triturus) which has land and water phases.

b. Note the body shape, the flattened head, the long tail and the position of the legs in walking. In body proportions the salamander resembles closely the primitive, extinct Amphibia.

c. Observe closely the smooth, slimy skin, which is one of the distinguishing characters of the amphibia. This is a ready means of identification.

d. In the head region are the paired nostrils. These open into the mouth and serve as breathing organs in addition to the olfactory function. The eyes are well developed.

e. A cloaca is typical of the amphibia.

5. Necturus.

a. Compare Necturus, a primitive, water-living form, with the salamander. In many characters the former is larval rather than adult, and by many biologists is considered a permanent larva.

b. Note the three external gills. There are also accessory lungs.

c. The tail folds are correlated with its aquatic habitat.

6. Lizard.

a. The lizard is used as a reptilian type, for in general body proportions it is typical of the generalized reptile form. The reptiles do not pass through a gill-breathing stage, but begin life as miniature adults.

b. Note particularly the covering of ectodermal scales. This is a typical reptile character. Feel the body, and examine the scales with a hand lens. There are few skin glands, the reptile skin being very dry.

c. Observe the claws on the end of the digits, and the position of the legs in relation to the body. The body is raised from the ground in walking, an adaptation to rapid motion on land.

d. Note the external nostrils, the eyelids, cloaca, the membrane covering the middle ear, and the rounded contour of the tail.

7. Bird.

a. In the laboratory any genus may be used. The pigeon or sparrow are usual types.

b. Observe the covering of feathers, a diagnostic character of the birds.

c. In the head region note the horny beak entirely lacking teeth. Locate the eyes, the nostrils at the base of the beak, and the ear aperture. Compare the position of the ear-drum in the bird and lizard.

d. The fore limbs are specialized for flying, the bones being fused, with the loss of most of the digits.

e. Observe the adaptations for a bi-pedal mode of walking.

f. The tail is very short, and in life has long tail feathers attached. A cloaca is present.

g. The legs have scales, an ectodermal structure homologous with the scales of the reptiles.

h. Skin glands are almost lacking.

8. Mouse.

a. The mouse or rat (Mus) is used as a typical primitive mammal.

b. Observe the covering of hair, as distinctive of mammals as feathers are of birds. Around the mouth several long tactile hairs may be seen. The tail is covered with scales.

c. In the head region note the well developed lips; the external nares, and the external ear, or pinna. The last is limited to the mammals.

d. Open the mouth and observe the teeth, which are specialized for a gnawing function. Note that the back teeth and front teeth differ in structure, a *heterodont* condition. Compare the number and type of the teeth with the human dentition.

e. Along the ventral body wall are the small mammae or milk glands. They are present in both sexes, though non-functional in the males.

f. The limbs are held under the animal, the entire leg being in the dorso-ventral plane. Compare the walking position of the salamander, lizard and rat.

g. Note the region of the anus and urinogenital opening, called in the mammal the *perineal* region. In the female the urinogenital opening is just below the anus, bounded by two emi-

nences, the labia majora. In the male identify the testes which are held in the scrotum, the homologue of the labia majora of the female. The penis is median-ventral in position, and will be withdrawn into the body; the prepuce, or surrounding skin, being all that is visible externally.

D. Orders of the Vertebrates

1. The orders given include only those referred to in most courses, inclusion for discussion in two or more standard texts on the subject being a criterion of selection. The classification has been greatly simplified to avoid the complicated grouping used by specialists. For instance, the order Teleostei has been split by one authority into thirty-two separate orders. Though this involved classification is too difficult for beginning students, it must be kept in mind that a standardized nomenclature is necessary in any science. The types given should be studied in texts or from demonstrations. Orders or types which are now extinct are marked with an asterisk.

2. Pisces.

Sub-class: *Elasmobranchii*, the cartilaginous fishes.

Order 1. *Cladoselachii**, shark-like Elasmobranchs in which the pectoral and pelvic fins had much wider bases of attachment than in existing forms. Cladoselache*, the type form from the Upper Devonian period, had many cartilaginous supports for the fins; and it was in this group that placoid scales first appeared.

Order 2. *Selachii*, includes many extinct forms, and all the recent types. Sharks, skates, and rays.

Sub-class: *Teleostomi*, the bony fish.

Order 1. *Chondrostei*, the most primitive living bony fish, including the sturgeons and others. The chondrocranium remains unossified, the outer dermal bones being loosely attached. There is a persistent notochord in the vertebral column; a heterocercal tail; and a spiral valve. The body is partly covered by bony plates. Acipenser is the type. Note the position of the mouth, and the similarity to the sharks.

Order 2. *Holostei*, fish in which the vertebrae are bony; the skull (including the chondrocranium) is ossified; the tail

is heterocercal or almost homocercal; and there is a spiral valve. Lepidosteus is covered with rhomboidal scales which do not overlap each other; the elongated jaws contain sharp teeth; the tail is almost heterocercal. Amia (the Bowfin) is a specialized Holostean with overlapping scales and an almost homocercal tail.

Order 3. *Teleostei*, fish with well ossified skeleton, more specialized than the Holostei. The most primitive have a slight spiral valve. The tail is homocercal. The order comprises the vast majority of living fish, a very heterogeneous collection, including minnows, herring, tarpon, and the deep-sea fish. Compare a sturgeon, the gar-pike (Lepidosteus), and several teleosts. Which appears more primitive, the herring or the perch?

Order 4. *Crossopterygii*, in which the pectoral fins consist of a fleshy lobe, surrounded by dermal rays. The swim-bladder is paired, vascular, and arises as a ventral outpocketing of the gut. There are spiracles in the skull. The larvae have external gills. It is from this group that the Amphibia are supposed to have evolved. This order, with the Chondrostei and Holostei are often called "ganoids", due to the composition of the scales. Little else connects the Crossopterygii with the other two. Polypterus lives in the Nile valley, with another genus, the only living representatives of a once large group. Sauripterus* is an extinct genus with a limb skeleton closely resembling that of the early Amphibia.

Sub-class: *Dipnoi*, the Lung-fishes. These were formerly supposed to be the ancestors of the Amphibia. They have lungs (vascular swim-bladders) and gills; the larvae have external gills. There are three genera, in Australia, South America, and Africa.

3. Amphibia.

Order 1. *Stegocephala**, the most primitive Amphibia, now extinct. They had tails, a bony armor of dermal plates, and skulls closely resembling the fossil Crossopterygians. Capitosaurus* is a generalized type, the skull being shown in Part V, C.

Order 2. *Apoda*, burrowing, legless, Amphibia. Though

highly specialized for burrowing, the skull and minute dermal plates are generalized characters.

Order 3. *Urodela*, recent, tailed amphibians. Includes the salamanders, newts, Necturus, and many other forms. Some urodeles have lost one or both pairs of limbs. Cryptobranchus, an American form, has only internal gills. The Japanese form of Cryptobranchus (Megalobatrachus) is the largest living amphibian, reaching six feet in length. The Mexican Axolotl is a permanent larva of a salamander, Amblystoma tigrinum, which metamorphoses when fed thyroid.

Order 4. *Anura*, the tailless Amphibia, includes the frogs and toads.

4. Reptilia.

Sub-class: *Anapsida*, reptiles with the roof of the skull solid, not perforated by fenestrae (see Part V, D.).

Order 1. *Cotylosauria**, early, primitive reptiles, with many resemblances to the Stegocephala. Seymouria* is described later.

Order 2. *Chelonia*, the turtles, tortoises, and terrapins. The body is covered with bony plates, outside which is the typical reptilian ectodermal scales.

Sub-class: *Synapsida**, reptiles with a single pair of fenestrae in the temporal region of the skull.

Order 1. *Theromorpha**, primitive, carnivorous reptiles. Dimetrodon* (described later) has a skull typical of this group.

Order 2. *Therapsida**, reptiles which show the widening of the fenestra, the increase of the brain case, the beginning of heterodont dentition (differentiation of molars, canines and incisors), and many other mammal-like characters. They are supposed to be the reptilian group from which the mammals evolved. Ictidopsis* is described later. Cynognathus* was the "dog-jawed" reptile.

Sub-class: *Diapsida*, reptiles with two pairs of fenestrae in the skull roof, one lateral and one dorsal.

Order 1. *Dinosauria**, extinct reptiles covering a vast range of adaptation. It includes the largest land animals known.

Order 2. *Crocodilia* are Alligators, Crocodiles, Gavials; reptiles with bony plates under the heavy ectodermal scales. The alligator is described later.

Sub-class: *Parapsida*, reptiles with a single pair of dorsal fenestrae, including the snakes and lizards.

Order 1. *Squamata*, including the lizards and snakes, which are usually placed in two sub-orders. Lizards have eyelids; a fusion of the halves of the lower jaw; and usually have legs. Snakes have no eyelids; lack legs (except for rudiments in Boa, etc.), and the ventral surface is covered with wide scales, or scutes. The halves of the lower jaw are movable.

5. Aves.

Sub-class: *Archaeornithes**, fossil birds with long, reptile-like tail, the feathers being fan-shaped on either side. They had teeth, and digits useful in climbing. *Archaeopteryx** is the type, known from two remarkable fossils.

Sub-class: *Neornithes*, birds in which the tail is shortened. The fossil specimens have teeth, which the recent ones have lost. Birds are divided into *Carinates*, or flying birds, with a large keel on the breastbone for the attachment of flying muscles; and *Ratites*, or running birds, with a smooth breastbone. The latter group includes the ostrich, emu, kiwi, etc.; the carinates include all the flying type, pigeons (Columba), crows (Corvus), geese (Anser), storks (Ciconia).

6. Mammalia.

Sub-class: *Prototheria*, egg-laying mammals. The mammary glands are devoid of teats, there is a cloaca, and the skeleton has many reptilian characteristics. The egg has a large yolk and a tough shell, the embryo hatching in the same manner as a reptile. The group is found only in New Zealand, Australia and the adjacent islands.

Order 1. *Monotremata*, the only order, includes two genera. Ornithorhynchus, the Duck-billed Platypus, has bird-like, horny jaws, with embryonic teeth which are lost. The legs are held in the reptilian position. Echidna is the Spiny Anteater, and is adapted for burrowing, and has large spines. These animals are excessively primitive, even the temperature being inconstant, differing from

the typical mammals, which are completely "warm-blooded".

Sub-class: *Metatheria*, the marsupials, are mammals developing eggs with very little yolk. The young are born alive, though in a poorly developed condition. Most marsupials have a pouch into which the young crawl and become attached to the teats. The group is limited to Australasia and America.

Order 1. *Marsupialia*, the only order, includes a wide range of animals. The American opossum (Didelphys) is skeletally almost identical with the ancient Cretaceous mammals. In Australia, where there was no competition from placentals, the marsupials have developed many adaptations, paralleling many of the orders of placentals. Kangaroos, the marsupial wolf (Thylacinus), and Perameles are included.

Sub-class: *Eutheria*, mammals which develop minute eggs, but nourish the embryo within the uterus until it assumes the form typical of the race. Embryonic tissue develops a placenta which attaches to the wall of the uterus, and through which dissolved food and oxygen pass by osmosis. There is no connection of the blood streams. Placental mammals.

Order 1. *Insectivora*, a primitive group, with sharp cutting teeth. Their brains are poorly developed. Included are the moles, shrews and hedgehogs, most of which are burrowing.

Order 2. *Chiroptera*, the bats, have insectivorous teeth, and are close to the Insectivora. They are highly specialized in the development of exceedingly long digits, webbed by a leathery membrane. The order includes the fruit eating and a few blood sucking (Vampire) bats.

Order 3. *Rodentia*, gnawing animals, with the front incisors modified into chisel-like teeth. The brain is poorly developed. The order includes the rats, beavers, porcupines, and rabbits.

Order 4. *Edentata*, a group of toothless, or almost toothless, mammals, which are usually divided into three orders. Making them a single order is a purely artificial convenience. The American forms are the sloths, armadillos, and ant-eaters, with numerous fossil types. Armadillo is interesting for its bony plates enclosing

the body. Manis, from Africa, is covered with large scales, hairs coming out between them.

Order 5. *Carnivora*, or flesh eating mammals, with long canine teeth for tearing, and usually premolars modified for cutting. The brain is well developed. Two suborders are often given ordinal rank: Fissipedia, including the land carnivores, cats, dogs, hyaenas, etc.; and the Pinnipedia, aquatic forms, including the walrus, seals, and sea-lions.

Order 6. *Primates*, mostly arboreal types, with well developed brain. Lemurs, monkeys, apes and man are included. Lemurs are primitive relatives of the anthropoids, some bearing little resemblance to the higher forms. The monkeys are clearly divided into the Old World and New World, separated by a number of anatomical characters. The anthropoid apes, orang, chimpanzee, and gorilla, are highly specialized Old World forms. The last two are closely related, and not far distant from man. Pithecanthropus * is a now extinct man, remarkably like the anthropoid apes. Homo sapiens is the existing species of man.

Order 7. *Cetacea*, whales, porpoises, etc., usually large animals highly modified for aquatic life. The whales are divided into two groups, toothed and toothless whales. The latter have an epidermal strainer of "whale-bone" in their mouths. The teeth, when present, are all conical in shape and often quite numerous. This homodont condition is secondary.

Order 8. *Artiodactyla*, are even-toed ungulates, or herbivorous mammals. The axis of the limb passes between the third and fourth digits of the manus and pes. The order includes cows, sheep, deer, pigs and hippopotami.

Order 9. *Perissodactyla*, the odd-toed ungulates. The axis of the limb passes through the third digit of the hind and front feet. Horses, zebras, rhinoceri are examples. The horse has only a single digit left, the others sometimes appearing in the embryo.

PART IV

STRUCTURE OF FUNDAMENTAL TISSUES

A. General Discussion

1. Anatomy is divided into (a) *gross* anatomy, the study of visible structures by dissection; (b) *microscopic* anatomy (Histology) which is accomplished by cutting the tissue into thin sections and studying with a microscope; and (c) *developmental* anatomy (Embryology) which is the study of the development of the organism. Histology and Embryology are usually given as separate courses, but some knowledge of both is necessary for an understanding of the body.

Tissues are classified by a similarity of cellular structure and development. The body is divided into organs and tissues, each organ being composed of several different tissues. Thus an artery is composed of epithelial, or lining, tissue; muscular, contracting, tissue; and connective, supporting tissues. In addition each artery is innervated by nervous tissues, and is nourished by blood tissues. Five types of tissue are recognized.

2. Fluid (Blood) Tissues. Fluid tissues are those which transport oxygen and nourishment to other parts of the body. The structure of blood is discussed under the Vascular System.

3. Epithelial Tissues. Those which cover or line other tissues. Epithelial cells assume different shapes:

a. *Squamous,* flat, tile-like structures.
b. *Cuboid,* cells approximately as deep as they are wide.
c. *Columnar,* long cells with the small surface exposed.

Epithelia may be simple, a single layer thick; or stratified, several layers thick. A surface covering may contain all shapes of cell.

4. Muscular tissues, the contracting tissues of the body, are mesodermal in origin. Histologically three types are recognized.

a. *Smooth,* or involuntary, muscle. These fibers surround the viscera and blood vessels and are not under voluntary control.

b. *Striated*, forming the skeletal muscles. These are normally under voluntary control, react rapidly, and are identified by transverse bands of dark and light substance.

c. *Cardiac*, forming the muscles of the heart. This type is normally involuntary but striated, and in structure resembles both smooth and striated muscles.

5. Nervous tissues, which are the coördinators of action. As these tissues are difficult to study and do not often complicate the study of organs, they are discussed with the Nervous System.

6. Connective tissues, which are the supporting structures of all organs and other tissues. They are composed of cells with a predominance of intercellular substance, the latter determining the physical character of the tissue. Connective tissues show a close relation to each other in their ability of one form to be closely connected with, or be transformed into, another form. All types have a common embryological origin in a loosely arranged portion of the mesoderm, the *mesenchyme*. The fibers and other intercellular substances are secreted by (or develop from) the primitive cells. Connective tissues are classified as:

a. *Connective Tissues Proper*. This tissue is sub-divided into:

(1) *Embryonal*, a primitive tissue rarely found in the adult form, but common in the embryo.

(2) *Fibrillar*, which includes the loose or areolar (subcutaneous), and formed tissue (tendons and aponeuroses). The fibers are longitudinally striated.

(3) *Elastic*, found in connection with the fibrillar tissues, and composed of elastic fibers which are homogeneous in appearance.

(4) *Reticular*, which is similar to and often continuous with fibrillar tissue. This is found as a supporting structure for all organs and glands.

b. *Cartilage*, composed of cells embedded in a firm, dense ground substance. The cells occupy cavities, or lacunae, in the matrix. Cartilage may be mixed with connective tissue fibers, the latter determining the cartilage type.

(1) *Hyaline* (or clear) cartilage, lacks fibers, and the intercellular substance appears homogeneous. It is the most common variety and is found in the nasal, laryngeal,

tracheal and costal cartilages, as well as the articular surfaces of joints.

(2) *Fibrous* cartilage is composed mainly of fibrillar connective tissue. The cells are few, the tissue being dense and tough. It is found in the intervertebral discs and the lining of several joint surfaces.

(3) *Elastic* cartilage resembles hyaline, but differs in that it is shot through with many elastic fibers. It is found in the external ear, Eustachian tube, and other small cartilages.

c. *Bone*, a form of connective tissue where the matrix is rendered hard by the deposition of calcium carbonates and phosphates. These salts are intimately combined with the organic matrix, so that either may be dissolved out without destroying the histological structure of the bone. The structure of bone and cartilage is discussed under the endoskeleton.

B. Laboratory Study of Tissues

1. Epithelial Tissues. Epithelia are best studied in sectioned tissues, where the epithelial cells show in side view. Top view studies may be made with preparations of epidermis. The shed skins of newts or snakes make excellent demonstrations.

a. Epithelial cells from mouth. Scrape the inside of the cheek with a dull instrument and mount a drop of the saliva under a cover slip. The lining cells are large irregular cells of the *squamous* type. A thin smear may be made, allowed to dry, and stained with 1% methylene blue for three minutes. Wash in running water and study.

b. Skin of a tadpole. Either a frog or newt tadpole may be used. Scrape the tail of the animal with a slightly dull knife, float the fragments out on a few drops of normal salt solution placed on a slide, and cover for study. Study first as living tissue. The nuclei are large and the cell boundaries indistinct, but a clear region will show the essential structures. Scattered throughout the specimen will be large irregular pigment spots, the melanophores, which need not be studied. The specimen may be stained by placing a drop of methyl blue (or green) at the edge of the cover slip and drawing the stain through by placing a bit of filter paper on the opposite side of the cover glass.

c. Section of the Mammal Stomach. The slide will include the entire stomach wall, with the lining epithelium deeply stained and appearing as a wavy line. The waves are caused by closely packed tubular glands, the surface membrane being continuous into the pits. The epithelium is of a *simple columnar* type. Under high power note the elongated cells with ovoid or spindle-shaped nuclei, placed near the bottom of the cell. The end of the cell toward the cavity of the stomach is clear, since these are secreting cells, and the distal half is mucus-filled.

d. Esophagus section. The esophagus is lined with a deeply stained, fairly smooth layer of epithelium, of a *stratified* (compound) type. The cells at the bottom, near the connective tissue base, are almost cuboid, flattening at the lumen into squamous type; and the tissue is called stratified squamous epithelium. The number of layers, strata, increase near the junction with the stomach. If the section is cut through the juncture of the esophagus and stomach, the shift from a stratified to a simple epithelium can be observed.

2. Muscular Tissues. Muscle cells may be studied by teasing the cells apart. (See Appendix I.) Such demonstrations can be studied from the following descriptions of sectioned tissues.

a. *Smooth Muscle* from the intestine. The slide used for study of epithelium may be used. The muscles surround the stomach and intestine, therefore they will be found on the opposite side of the section from the epithelial layer. With the usual histological staining (haematoxylin) the muscle fibers will appear reddish blue, and will be separated from the epithelial coat by colorless or yellowish connective tissue. There are two layers of smooth muscle surrounding the gut, the outer being longitudinal, the inner circular, their antagonistic action causing peristalsis. In a longitudinal section of the stomach wall the circular group will have the fibers cut in cross-section, while the outer group will show the spindle shape of the individual fibers. Study the longitudinal fibers and note (1) the spindle shape of the cells, and (2) the single nucleus centrally placed. Smooth fibers are much smaller than the striated.

b. *Striated Muscle.* A longitudinal section of any skeletal muscle may be used. It is impossible to get a section of an entire

fiber, as individual fibers may be four or five inches long. The fiber has many nuclei and is called a *syncytium*, a fusion of cells within one membrane. The fiber is divided longitudinally into slender *myofibrils*, and each myofibril is divided into alternate discs of light and dark substance. These discs run through the entire fiber, giving the transversely striated appearance from which the name is derived. Select a fiber which has become more or less separated from the others, and note (1) the nuclei lying near the surface; (2) the light and dark bands; and (3) the myofibrils, which cause a faint longitudinal striation.

c. *Cardiac Muscle.* Heart muscle is striated and involuntary. Both transverse and longitudinal striations can be seen, though less distinct than in skeletal muscle. The fibers send off branches which anastomose with other fibers. This indicates a syncytial structure, but as there is a single, centrally placed nucleus in each "cell"; and as one cell is easily separated from the others, cardiac muscle has many resemblances to smooth muscle. Note (1) the fibers; (2) the slighter branches fusing with an adjacent cell; (3) the centrally placed nucleus; and (4) the dark bands separating the different cells.

3. Connective Tissues. Connective tissues form the supporting structures of the body and are distributed throughout every organ and system.

a. *Subcutaneous, Areolar,* tissue of the rat. Subcutaneous tissue is classified as fibrillar, though elastic fibers and fat tissues are abundant. From a freshly killed rat remove with forceps a small bit of tissue from beneath the skin. That lying nearer the muscles will be less loaded with fat and easier to study. Mount on a microscope slide in normal salt, and with needles tease the fibers apart until a thin sheet is formed. Note (1) the broad, wavy *white fibers,* the typical fibrillar tissues; (2) the small *yellow elastic fibers* which often branch and anastomose; (3) the faint connective tissue and blood cells; (4) fat droplets, which are round globules. Demonstrations can be easily made to differentiate the fibers. (See Appendix I.)

b. *Tendons from a Rat's Tail.* Pinch through the skin of a rat's tail half an inch from the end, break the vertebrae apart, and slowly pull. The long tendons of the tail can be pulled out

unbroken, and should be immersed in normal salt solution. Cut off an inch of one of the tendons and study unstained. This is unmixed white fibrous, or fibrillated, tissue. Note (1) the clear white color; (2) the parallel fibrillae in the fibers, which do not branch or anastomose; (3) the transparent nuclei which spread the fibrillae apart.

c. *Ligamentum nuchi* (the neck ligament) of Rabbit. (See Appendix I.) Tease a fragment of the ligament apart and note (1) the small rounded fibers; (2) the branches anastomosing with other fibers; and (3) the twisted, recurved ends of the fibers where they are broken. The last is due to the elasticity of the fiber causing it to contract sharply when broken. These tissues relieve the strain on the muscles as they do not become fatigued from repeated contraction.

d. *Section of the Intestine.* Between the epithelium and muscles note the yellowish fibrillar tissue. The fibers pass into the muscles, completely surrounding each bundle of fibers, and also form the base upon which the epithelium rests.

e. *Reticular tissue of gland.* A section of a lymph node or gland will show the exceedingly minute fibers forming an interlacing network throughout the gland. In a lymph node the reticular tissues are continuous with the fibrillar tissue surrounding the node. This supporting structure can be determined with any histological stain, though Mallory's brings it out with particular clearness. (See Appendix I.)

PART V

ENDOSKELETON

A. Structure of Bone and Cartilage

1. Cartilage. The simplest cartilage to obtain and study is hyaline. Both unstained and stained specimens can be studied to advantage. Methods for preparing cartilage will be found in Appendix I.

a. *Stained Cartilage.* Observe the lightly stained, homogeneous *matrix*, or ground substance, which composes the greater part of the structure. This is a secretion of the *cartilage cells.* At irregular intervals, usually in groups of two or four, will be found open spaces or *lacunae*, which in living cartilage contain the cells. The matrix adjacent to the lacuna will usually be more deeply stained. Lining the lacuna is the *cell capsule.* The cell body is usually shrunken in fixed tissues, but can be distinguished around the dark nucleus.

b. *Fresh Cartilage.* Mount a thin slice of cartilage in normal salt solution. The microscope will have to be carefully focussed, as the structures are not differentially stained. Locate the matrix, the lacunae, and the faint cells. Notice that the cell completely fills the lacuna. What is the appearance of the nucleus? How do you account for the grouping of cells, usually in pairs? Does cartilage appear to be vascular?

2. Bone. Histologically there is one type of bone; but embryologically two varieties are recognized: (1) *replacement* bone, which develops within, or replaces, the cartilage skeleton of the embryo; and (2) *dermal*, or *membrane*, bone which develops in membranous connective tissues. "Dermal" is derived from the fact that such bone develops in the dermis, the deeper layer of the skin. Membrane bone is probably homologous with the dermal denticles of the shark. In the Chondrostei replacement bone is almost lacking, but membrane bone is abundant. In higher

vertebrates the cartilaginous skeleton is largely replaced by bone, though all vertebrates have some cartilage left. The gradual replacement of cartilage by bone, and the developmental difference between dermal and replacement bone can be studied in stained, cleared embryos. (For technique see Appendix II.) The development of bone by *osteoblasts*, bone building cells, and the tearing down of the tissues by *osteoclasts*, "bone breakers", should be studied in the text.

Bone studied in the laboratory is either *decalcified* by removing the salts with acids; or *dry bone*, the organic matter being destroyed by decomposition or heating. Either will show the same histological structure. (For directions for making dry bone slides see Appendix I.) Dry bone will be described as it is more diagrammatic and more easily made by the student.

a. First study the slide under low power. The lacunae and other spaces will appear black, due to the refraction of light through the enclosed air. Select one of the large dark spaces with concentric rings about it. This is a *Haversian system*. The central space is the *Haversian canal*, which extends longitudinally, branching and anastomosing freely with other canals. Each usually transmits an artery and vein. The rings of matrix are the lamellae, which are concentric cylinders around the canal. Between the lamellae, and helping to define them, are the dark *lacunae*, or cell spaces. In the living tissue a bone cell occupies each. Between the Haversian systems observe the *interstitial lamellae*, which are short and do not surround canals. These are the remains of older systems which have been partially destroyed by osteoclasts.

b. If the section includes the periphery near the connective tissue covering, or *periosteum*, lamellae will be seen which are not arranged in Haversian systems. These lamellae completely surround the bone, being laid down immediately underneath the covering. As the bone grows in diameter these *perichondral lamellae* are gradually destroyed and replaced by Haversian systems. These lamellae are partly responsible for the interstitial lamellae. Replacement bone is often classified as (1) *perichondral*, arising next the perichondrium; and (2) *endochondral*, the inner part, composed of systems. Which layer of perichondral bone is youngest? Which lamella of a Haversian system is youngest? After

a bone is formed, where does growth in length take place? Why does not the adult mammal continue growing?

c. Using high power, study a Haversian system. The same structures as seen in paragraph "a" will be found, and can be studied in detail. Focus on a single lacuna and observe its shape. Arising from it in all directions will be extremely minute branching canals, the *canaliculi*. These ramify in all directions through the bone, anastomosing with those from other lacunae. Processes from the cells extend into these spaces, and by some are thought to unite with processes from other cells. Oxygen and nourishment are carried from cell to cell by means of the canaliculi.

B. Evolution and Development of the Skull: Discussion

1. The vertebrate skull represents a rather intricate course of evolutionary history. If we accept the elasmobranch condition as representing a primitive arrangement, the early skull was composed entirely of cartilage and the upper and lower jaw were only loosely a part of the skull. This simple condition was soon changed by the much closer association of the upper jaw with the cranium, and the addition of bones on the outside of the chondrocranium. In some living animals (Chondrostei) this latter condition is seen. In these animals a sheath of heavy dermal bones protects the head externally, the underlying chondrocranium remaining unossified. In these cases the external dermal bones are clearly seen to be formed as fusions of the scales, or dermal denticles. In more advanced forms the chondrocranium itself becomes ossified in various parts. The extent to which this ossification takes place became increasingly great as higher forms evolved, resulting in an inseparable fusion of the two types of bone, which cannot be distinguished except by their embryological origin.

2. Embryologically the chondrocranium is present in all true vertebrates. Where a bony skull is present in the adult, the chondrocranium is usually incomplete dorsally, the anterior part being merely an open trough. Posteriorly is a bridge, the *synotic tectum*, forming a complete ring around the foramen magnum. External to the chondrocranium are formed *dermal* or *investing bones*, which are not preceded by cartilage. These not only cover the brain

case where there was no cartilage dorsally, but also tend to invest the cartilage bones. The more important dermal bones that are formed on the dorsal surface are the nasal, lacrimal, prefrontal, frontal, postfrontal and parietal bones. Ventrally are the pre-vomer and palatine bones. In addition, the pterygo-quadrate cartilage (the primitive upper jaw) becomes encased in a series of dermal bones: the premaxilla, maxilla, jugal, quadrato-jugal, and squamosal. Meckel's cartilage (the primitive lower jaw) also becomes sheathed. These bones are the dentary, splenial, coronoid, angular, and surangular.

3. The chondrocranium arises as five independent pairs of cartilages, which later come into close association: the parachordal, the prechordal or trabecular cartilages, the otic, optic and olfactory capsules. The ossification of these parts into *cartilage* or *replacement bones* is given below. Bear in mind that in the lower forms, such as the amphibia, only small parts of this chondrocranium will be ossified, the major part remaining cartilage. In the higher forms, such as mammals, little cartilage remains in the adult.

a. There are four groups of bones that are derived from the pre- and parachordal cartilages. The first two groups mentioned below come from the latter, and the last two from the former.

(1) Occipital complex: Composed of the median basioccipital, located below the foramen magnum; the median supraoccipital, located dorsal to the opening; and the paired exoccipitals, at either side.

(2) Posterior sphenoid group: These form that portion of the ventral surface that lies immediately anterior to the basioccipital. The bones of this group are the median basisphenoid, and the lateral paired alisphenoids.

(3) Anterior sphenoid group: These bones are anterior to the preceding group, and are composed of the median presphenoid, and the paired lateral orbitosphenoids which are found in the orbit.

(4) Ethmoid group: This group, on the ventral surface just posterior to olfactory capsules, is composed of the median mesethmoid, and the lateral paired ectethmoids.

b. That part of the chondrocranium that arises around the sense organs contributes cartilage (replacement) bones as follows:
   (1) Around each *otic* capsule the cartilage ossifies into several bones. There may be five separate bones, or some of them may have become fused. Those most commonly found in the higher vertebrates are the proötic, epiotic, and opisthotic.
   (2) The optic capsule does not form a part of the skull of the adult but forms the sclerotic layer of the eye which is a tough membrane in most cases, ossified in some.
   (3) The olfactory capsule develops bones which become added to the ethmoid group. These are the lateral ethmoids, and a part of the turbinals. The latter are scroll-like bones found in the nasal cavity.

c. The visceral arches also become ossified, forming replacement bones.
   (1) The pterygo-quadrate bar (primitive upper jaw) loses its jaw function, this being taken over by several membrane bones. The ossified middle portion of this cartilage becomes the pterygoid; and the posterior part the quadrate, which is the incus of the mammal. The anterior portion is lost, and its position is filled with a membrane bone, the palatine.
   (2) Meckel's cartilage ossifies only in the posterior part, forming the articular bone, which becomes the malleus of the mammal. The anterior part either remains as a cartilaginous core of the jaw or disappears entirely.
   (3) The hyomandibular becomes ossified, and in the forms above the fish becomes a part of the auditory apparatus. The remainder of the hyoid arch may or may not become ossified, and, together with parts of the more posterior arches, forms the hyoid apparatus.

4. Thus it is apparent that the skull arises from two sources, not only during evolution, but also embryologically. These two sources should be kept in mind during the work on skulls, and the two types of bone, replacement and dermal, should be clearly distinguished.

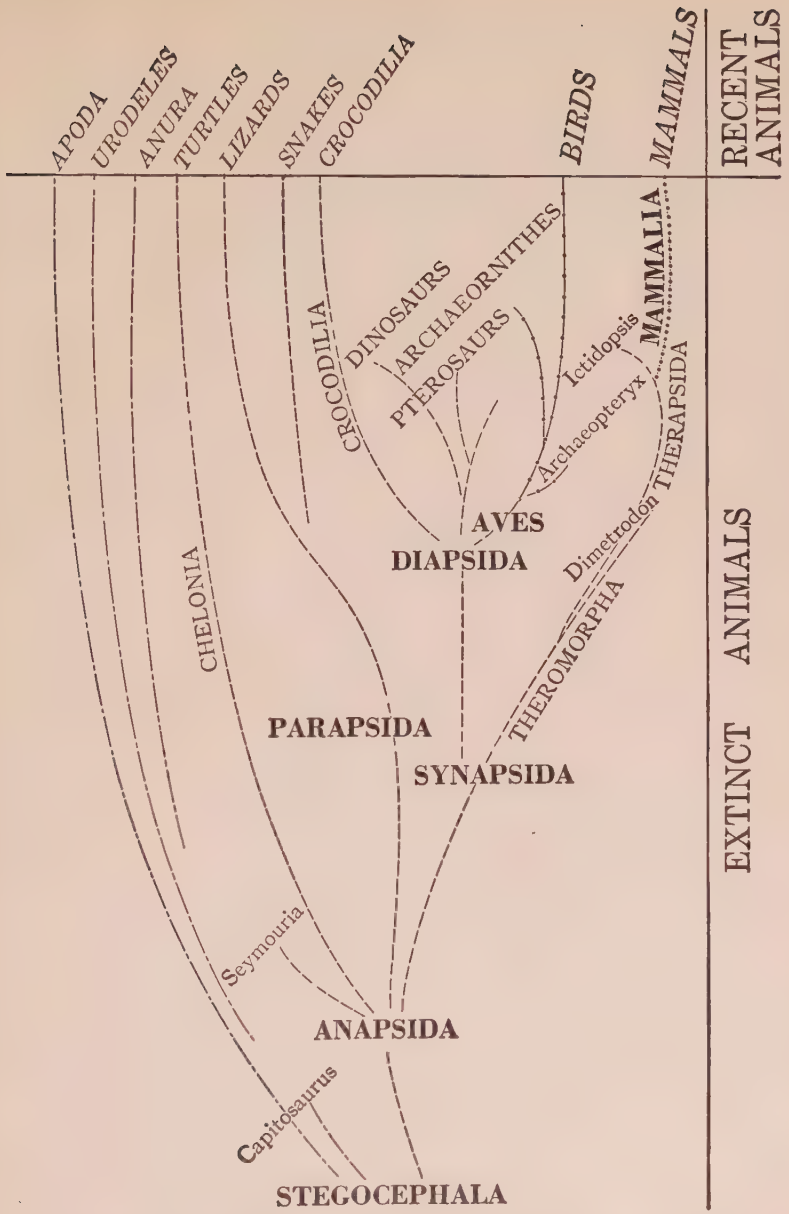

PLATE 8. Phylogenetic Tree of the Vertebrates. The drawing is included to give the student an idea of the relationships of the classes of the vertebrates. Amphibia are shown by long and short dashes; reptiles by short dashes; birds with dots and dashes; and mammals with dots. Fossils of particular interest are included. The fish are not shown. The Stegocephalian stem probably evolved from the Crossopterygian fish.

C. The Amphibian Skull

1. Skull of Capitosaurus. This animal is a member of the now extinct group of primitive amphibia, the Stegocephala, known only from fossil remains. The type of skull is quite typical of the early amphibia, and may be thought of as belonging to an animal that was closely related to the ancestors of recent Amphibia. A diagram of the skull of this animal is provided. Label the bones, carefully observing their relationships. The bones are described for only one side of the skull, but unless otherwise stated are paired.

a. The drawing is a dorsal view, but the posterior end of the skull is shown.

b. Note the general shape of the skull. It is slightly pointed anteriorly, but posteriorly is broad. The skull is very flat, the distance from the dorsal to ventral surfaces being not more than one fifth as great as the width of the skull at its widest point. In the posterior margin of the skull is a pair of indentations, the *otic notches*, over which the tympanic membrane was stretched. The otic notch was characteristic of the earliest amphibia and reptiles.

c. Anteriorly is a pair of openings, the *external nares*, through which the nasal passages passed. Posterior to the middle of the skull is a larger pair of openings, the *orbits*, the seat of the eyes in the living animal. The eyes were markedly dorsal in position. In the median line immediately posterior to the orbits, is a small opening, the *parietal foramen*. This is one indication that a third eye was originally present, perhaps homologous to the epiphysis that was seen in the dogfish brain. At the posterior limit of the skull is an opening, the *foramen magnum*, through which the nerve cord passed out from the brain. This is properly not a part of the dorsal surface, but the posterior surface. To either side of this opening is a swelling, the *occipital condyle*, against which the first vertebra of the vertebral column articulated.

d. Follow the bones around the margin of the skull. The most anterior, mediad to the external naris, is the *premaxilla*. Posterior to this is the *maxilla*, a long bone forming the greater part of the margin of the skull. The shorter bone posterior to this is the *quadrato-jugal*, so called because it lies between

two bones called the quadrate and jugal. The *quadrate* forms the posterior end of the lateral margin, and extends into the otic notch. It is with this bone that the lower jaw articulates.

e. The posterior surface of the skull is composed of replacement bones. Dorsal to the foramen magnum is a very narrow strip of bone, the median *supraoccipital.* This is much larger than appears from the drawing, and extends beneath the paired bones on the dorsal surface. Lateral to the foramen magnum, and bearing an occipital condyle, is the *exoccipital.* Beneath the opening is the median *basioccipital.* From what part of the chondrocranium are these bones formed?

f. Next follow the bones lying against the mid-dorsal line. These in order are the premaxilla that has been previously noted, the *nasal,* the *frontal,* the *parietal,* and *dermal supraoccipital.* The latter, as its name implies, is a membrane bone and should be distinguished from the supraoccipital, which largely lies beneath it.

g. Bounding the antero-lateral side of the orbit, and lying lateral to the frontal, is the *prefrontal.* Lateral to the anterior part of this is the smaller *lacrimal.* This bone abuts laterally against the maxilla.

h. Lateral to the orbit is a large bone, which forms but a small part of the margin of the orbit. This bone, the *jugal,* posteriorly lies against the quadrato-jugal.

i. The posterior margin of the orbit is formed by two bones. The more median one, situated in part between the orbit and frontal, is the *postfrontal.* The more lateral one, lying against the jugal, is the *postorbital.*

j. Lateral to the parietals, and forming a part of the margin of the otic notch is the *supratemporal.* Posterior to this, forming the posterior angle of the dorsal surface of the skull, is the *tabulare.* Lateral to the supratemporal, between it and the quadrato-jugal, is the *squamosal,* a bone that became increasingly important.

2. Skull of Necturus. This animal is a water-living Urodele. Although in many respects the body of this animal is quite primitive, the skull is definitely specialized. Many bones have been lost, and bones that were important in earlier forms are reduced

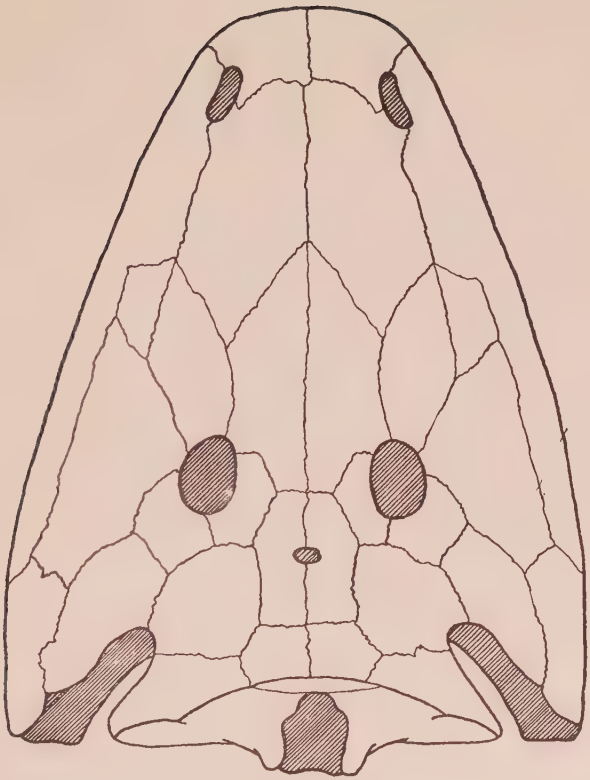

PLATE 9. Dorsal view of the skull of Capitosaurus. The openings and the otic notch are shaded.

to an unimportant size and position. Due to the shifts of bones, the external and internal nares are not present as openings in the skull. The nasal passage, connecting the nostrils with the mouth cavity, passes through soft tissues instead of through the skull. In these, and other features that the student will discover for himself, the skull is specialized. The object of this work is to determine the changes that mark the course of evolution from the primitive ancestors to the modern descendants.

a. Note the shape of the skull. It is very flat, pointed anteriorly and broader posteriorly. The brain cavity occupies only a minute part of the skull.

b. Along the mid-line of the dorsal surface are the premaxillae, frontals and parietals. The *premaxilla* is a minute, ∧-shaped bone, one process passing laterally to form a slight notch between this bone and those posterior. This notch probably represents the *external naris*. Posteriorly the premaxilla is pointed, slightly overlapping the next bone, the *frontal*. This extends two-thirds the length of the skull. Posteriorly it is pointed and pulls away from the mid-line. The *parietal*, forming the posterior part of the dorsal surface, extends into the space at the mid-line left by the posterior part of the frontal, and also sends forward a projection lateral to the frontal. The anterior edge of the parietal, then, is V-shaped, with the pointed end of the frontal fitting into the cavity of the V. Just posterior to the end of the frontal, the parietal widens and becomes heavier.

c. Lateral to the widest part of the parietal, a long slender bone forms the lateral margin of the skull and extends laterally as it passes anteriorly. This bone, the *squamosal*, is fused with the quadrato-jugal and supports the very small *quadrate* on the ventral surface of its anterior tip. The quadrate forms the articulation with the lower jaw.

d. It should be remembered that the lack of the maxilla and nasal bones is a rather unusual specialization.

e. On the ventral surface the major part of the teeth are borne by the *pre-vomers*. Each of these bones has a posterior projection, and laterally curves upward to make contact with the frontal. The greater part of the ventral surface is composed of a single bone, the *parasphenoid*.

f. Lateral to the parasphenoid is a long bone which is in contact

with the pre-vomer anteriorly and with the quadrate posteriorly. This bone, the *pterygoid*, forms as an ossification of the pterygo-quadrate cartilage, or primitive upper jaw. Although it can be seen from the dorsal surface, it is properly a part of the ventral surface.

g. The posterior end of the skull is composed mainly of the *exoccipitals*. These bear the *occipital condyles* for articulation with the vertebral column. The remainder of the synotic tectum does not become ossified, so that the dorsal portion which would form the supraoccipital, remains cartilaginous. The ventral part, or basioccipital, is crowded out by the development of the exoccipitals.

h. The part of the chondrocranium anterior to the synotic tectum also remains unossified. Several parts of this can be seen externally. Stretching across the space between the parietal, quadrate, and pterygoid bones is a sheet of cartilage that is a remnant of the primitive pterygo-quadrate.

i. Lateral to the posterior end of the parasphenoid are two small bones, one in front of the other, separated by a small amount of cartilage. The bones are formed as an ossification of the otic capsule, a part of which remains as the cartilage separating the bones. The anterior one is the *proötic* and the posterior the *opisthotic*.

j. What bones of the skull have been lost? What openings? What bones have markedly changed their relative size? What bones bear teeth?

k. The lower jaw is composed of the unossified *Meckel's cartilage*, covered for most of its length by a sheath of membrane bones. The largest of these, the *dentary*, extends along the lateral surface and bears most of the teeth. Along the middle of the inner surface of the posterior half of the jaw is a bone that passes onto the outer surface at the posterior end of the jaw. This bone is the *angular*. The surface that articulates with the quadrate of the upper jaw is formed entirely of cartilage, and is the posterior end of Meckel's cartilage.

l. An outline of the skull is provided to which the student can add structures and labels.

3. Skull of Cryptobranchus. This animal is another water-living Urodele, but reaches a much larger size than does Necturus.

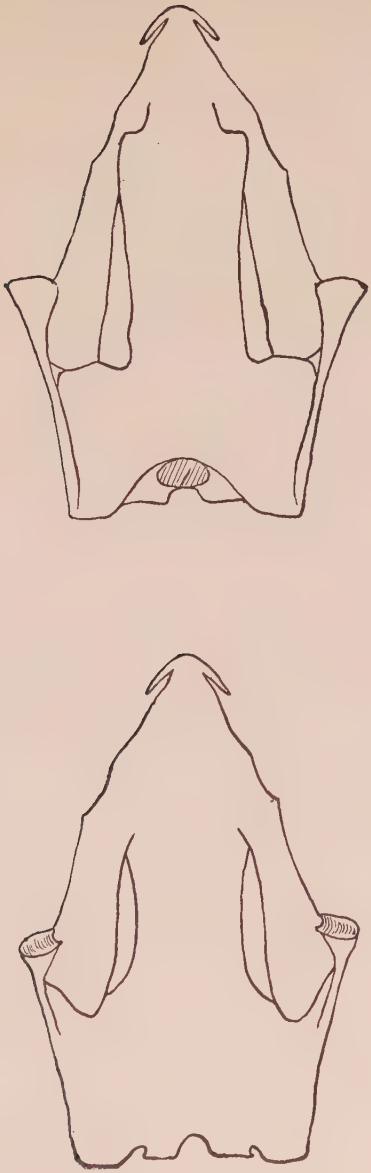

PLATE 10. Necturus skull. Necturus is a urodele amphibian. The dorsal view is above. The skull is partly cartilage, which should be indicated. Fill in the sutures and label.

Its skull, like that of Necturus, is specialized, but differs from Necturus in having a less extensive loss of bones and having a somewhat more completely ossified chondrocranium.

a. Note the general shape of the skull. The anterior end is markedly semicircular in shape with the lateral margin interrupted posteriorly. The back of the skull is broad, and formed of heavy bone. Mediad to the end of the bones forming the antero-lateral margin is a large space unoccupied by bones of either the upper or lower surface. Just posterior to this opening is a broad flat bone that is properly a part of the lower surface, although it is seen dorsally, and which will be described in connection with the ventral surface.

b. In the anterior part of the skull is a pair of openings, the *external nares*. By looking at the side of the skull, an opening will be seen just posterior to each external naris. This lateral opening is the *internal naris*. Each nasal passage passes from the outside through these two openings in the skull, and connects with the anterior part of the mouth cavity. In the mid-line of the posterior surface of the skull is the *foramen magnum* for the passage of the nerve cord. Look into this and note the small size of the brain cavity.

c. The semicircular anterior margin of the dorsal surface is formed of two bones on either side. The more median is the *premaxilla*, and the more lateral bone, having a free distal end, the *maxilla*. Do both bones bear teeth? Are all the teeth of the upper jaw borne by these two bones?

d. Back of the premaxilla, and bounding the median part of the posterior margin of the external nares, is the small *nasal*.

e. The lateral part of the posterior margin of the external naris is formed by the *frontal*. This very narrow bone swings to the mid-line posterior to the nasal, and continues in this position to a point nearly two-thirds the length of the skull.

f. Lateral to the anterior half of the frontal is a parallel bone, the *prefrontal*.

g. Posterior to the end of the frontal, and extending to the foramen magnum, is the *parietal*. This bone sends a process anteriorly, lateral to the frontal, as far as the prefrontal. Lateral to this anterior process is a narrow bone, the *postorbital*.

h. Extending laterally from the posterior part of the parietal is the *squamosal.* Distally this bears the small *quadrate,* the latter forming the articulation with the lower jaw.

i. The posterior surface of the skull is formed by the *exoccipitals* which surround the foramen magnum. The supraoccipital never ossifies and is present in the living animal only as a small cartilage. The *occipital condyles,* smooth projections for articulation with the first vertebra, are formed on the exoccipitals.

j. The anterior part of the *ventral* surface is formed by the paired *pre-vomers.* These bear teeth along their anterior edge. The internal nares open lateral to these bones.

k. Posterior to these is the large median *parasphenoid.* Lateral to this bone is the wing-like *pterygoid* that was seen from the dorsal surface. This, together with the quadrate, develops as an ossification of the primitive upper jaw or pterygoquadrate cartilage.

l. Just anterior to the squamosal on the dorsal surface is a large opening under the parietals. This is for the passage of the optic and other nerves. Posterior to the squamosal and pterygoid, on the lateral surface, is another large opening. On looking into this opening, small bones will be seen within and just anterior to the external opening. These are the *otic bones,* ossifications of the otic capsule of the chondrocranium. The external opening may be called the *external auditory meatus.* In various parts of the skull small round openings or foramina may be seen. These are for the passage of various nerves and blood vessels, and can be studied to better advantage in connection with the mammal skull.

m. The lower jaw is composed of a sheath of membrane bones surrounding Meckel's cartilage which remains unossified except in its posterior part. The largest bone, and the only one bearing teeth, is the *dentary.* Along the greater part of the mediad surface is the *coronoid.* At the very posterior tip of the jaw, on the ventral surface, is the *angular.* Above this is a small ossification of Meckel's cartilage, the *articular* bone, which, as its name implies, articulates with the upper jaw.

n. An outline is provided to which the student can add structures and labels.

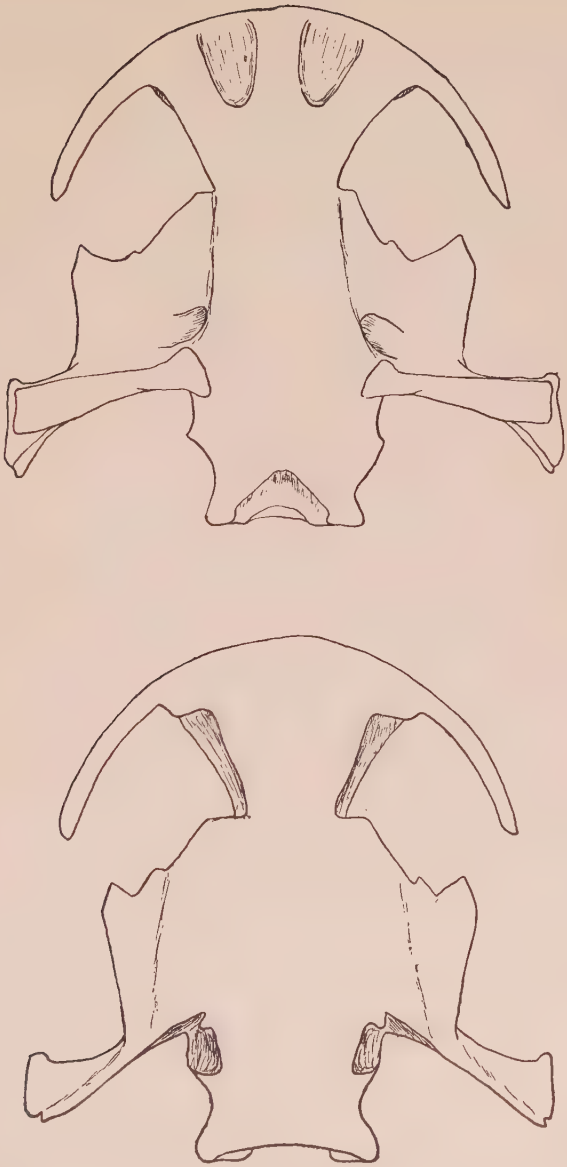

PLATE 11. Cryptobranchus skull. Cryptobranchus is a recent urodele amphibian with a highly modified skull. Fill in and label.

D. The Reptile Skull

1. The reptiles, during the course of evolution, underwent great variations in the skull, changes which early marked the reptiles into four major groups. The class then developed modifications in all directions. The wide differences of skull structure of modern groups, for example between the turtles and the snakes, is an end-product of these variations. In the study of the reptilian skull, drawings of two fossil forms are given, and two modern representatives, turtle and alligator, are described. The snake and lizard skulls are omitted because of their extreme degree of specialization. Of the living reptiles, the turtle probably has a skull that is most nearly primitive, while the snakes have the most specialized. That of the alligator, in regard to specializations, is about half-way between these two.

2. Skull of Seymouria. This animal is one of the earliest known reptiles, and its skull shows many resemblances to that of the early amphibia from which it was evolved. Note the increasing depth of the skull. Label the bones and openings, both dorsal and ventral views, by comparing it with the amphibian skulls. Seymouria is an *Anapsid* reptile still retaining the otic notch. A new bone appears in this skull. It is a small bone lateral to the parietal foramen. It is called the *inter-temporal* and lies surrounded by the *parietal* medially, *postfrontal* anteriorly, *squamosal* laterally and the *supratemporal* posteriorly. The *quadrate* lies in the same relative position as it did in Capitosaurus. The lower jaw contains the anterior *dentary* which bears teeth, the *angular* forming the ventral posterior part, and above this the *surangular* and *articular*. The last bone barely shows in the drawing.

3. Skull of the Turtle. The turtles are the only living members of the *Anapsida*. The skull has become specialized in the development of a large opening on the posterior surface.

a. Note the general shape. The depth of the skull has become more pronounced. Turn to the posterior end of the skull and notice that the brain case, as seen through the foramen magnum, is still small, and that the great increase in depth is due to the development of a dome-like expansion of the outer bones. The cavity between the wall of the brain case and the outer bones is filled with muscles.

b. Anteriorly are the *external nares*, and on the sides of the skull are the large *orbits*. The *foramen magnum* has already been noted. Beneath the foramen is the single *occipital condyle*. How many do the amphibia have? Notice that it is made up of processes from three bones. Lateral and ventral to the foramen magnum is an opening on either side. This opening, the *external auditory meatus*, connects with the ear. On the ventral surface the smaller anterior openings are the *internal nares*. Compare the position of these with those of Cryptobranchus or Necturus. Posterior to these is a pair of much larger openings, the *palatine vacuities*, through which muscles pass.

c. The bones along the mid-line of the dorsal surface are the *premaxillae*, *prefrontals*, *frontals*, *parietals*, and the median *supraoccipital*. In many species the last is prolonged posteriorly into a spine.

d. Bounding the ventral side of the orbit is the *maxilla*. Posterior to this, and also contributing to the margin of the orbit, is the *jugal*. Posterior to the jugal is the *quadrato-jugal*, abutting posteriorly against the smaller *quadrate* which furnishes the articulation with the lower jaw.

e. Forming the postero-dorsal angle of the orbit is the large *postorbital*, and posterior to this, between the parietal and quadrate, is the *squamosal*.

f. The posterior surface of the skull is composed of the median supraoccipital already mentioned, the two *exoccipitals*, and the median *basioccipital*. The last three enter into the occipital condyle.

g. On the ventral surface of the skull again locate the internal nares. Anterior to these is a very narrow strip of bone in the mid-line, a single *pre-vomer* representing a fusion of the original pair. Lateral to this, surrounding the nares, are the paired *palatines*. Posterior to the palatines, forming the narrow region between the palatine vacuities, are the *pterygoids*. These send processes to the extreme posterior limits of the skull. In back of the pterygoids, and between their posterior processes, is a median bone, the *basisphenoid*. It abuts posteriorly against the basioccipital. Which of these bones are replacement? Which membrane?

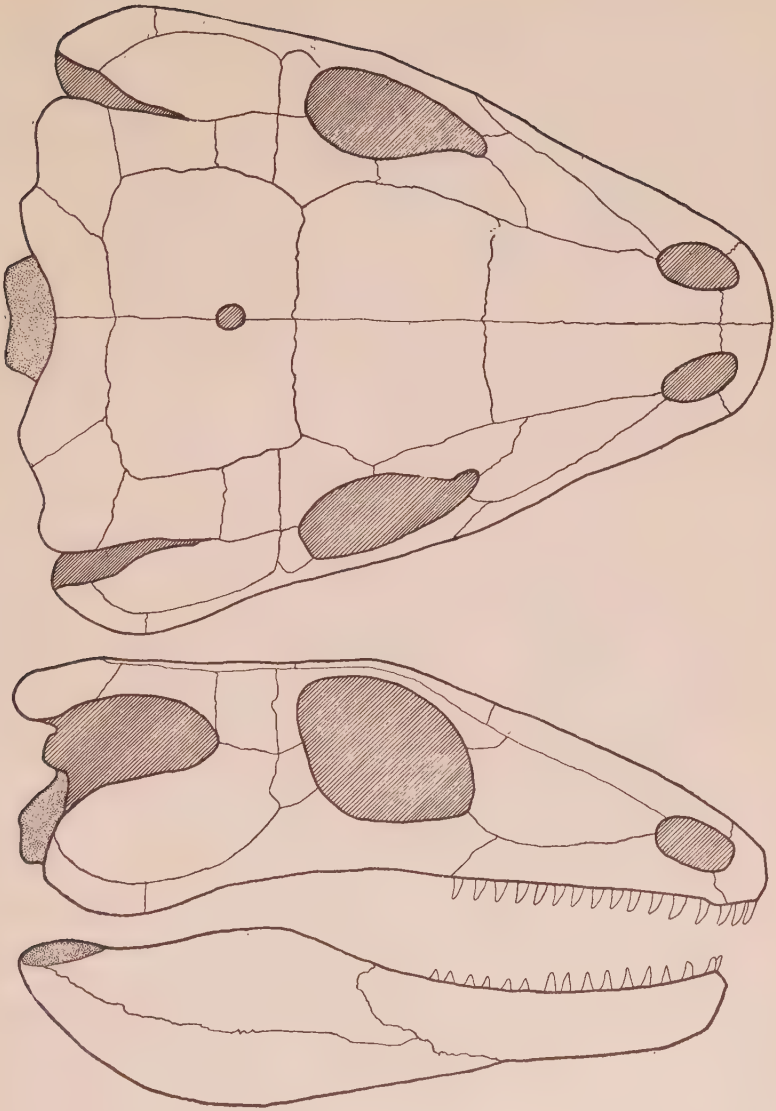

PLATE 12. Skull of Seymouria. Dorsal and lateral views. The openings are shaded. The occipital region and the articular bone are stippled

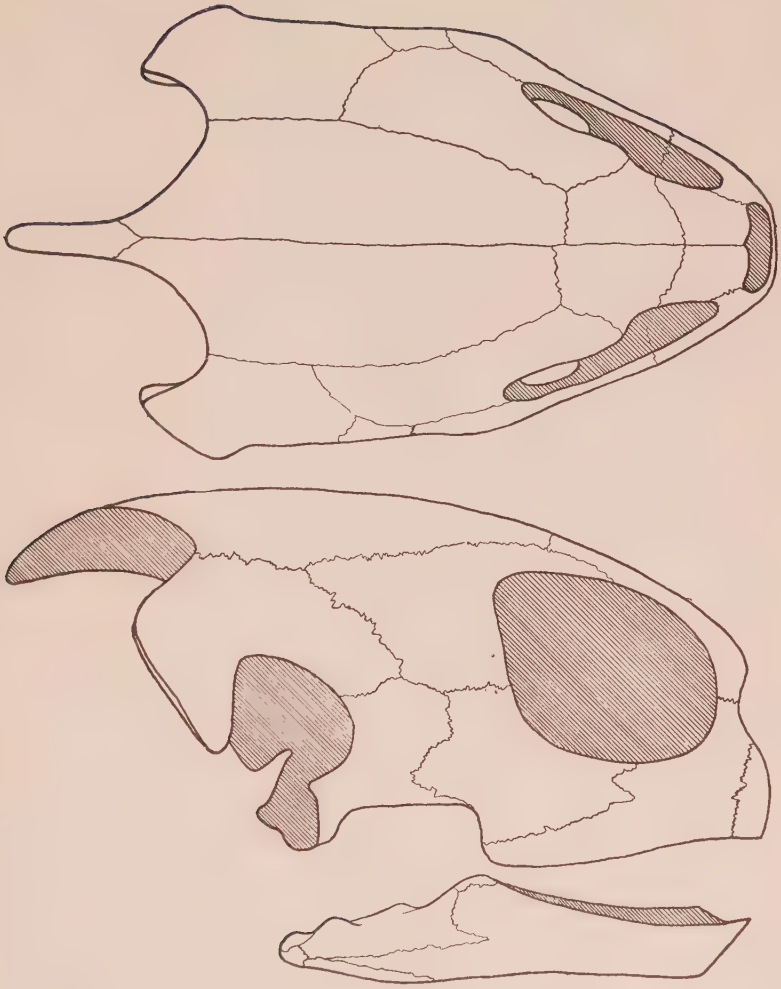

PLATE 13. Skull of the sea turtle. Label all structures. The turtle is a recent anapsid reptile. The openings and some depressions are shaded.

h. On the posterior surface of the skull, a small bone will be seen lying between the exoccipital and quadrate. This is one of the otic bones, the *opisthotic*, and contains the internal ear. By looking into the orbit, another bone of similar size, the *proötic*, will be seen just anterior to the opisthotic.

i. The lower jaw has a large *dentary*. Does it bear teeth? Note the upward projection in the posterior half of the jaw. The medial surface of this is formed of the *coronoid*, the lateral surface by the *surangular* and *dentary*. The ventral part of the medial surface is formed by the *angular*. The articular surface is on the *articular* bone. Dorsal to the angular is a separate bone, the *pre-articular*, the evolutionary history of which is not fully understood.

4. Skull of Dimetrodon. This is a *Synapsid* reptile, and therefore more closely related to the line leading to the mammals than is Seymouria. Compare the two skulls. Is there any reduction in the number of bones? The opening posterior to the large orbit is the *lateral temporal fenestra*. This opening arose between what bones? The dorsal surface of the skull is somewhat depressed, so that the bones along the mid-line do not show well in a lateral view. The bone forming the dorsal part of the bar between the orbit and the temporal fenestra is the *postorbital*. Just dorsal and anterior to this is the small triangular *postfrontal*, which abuts anteriorly against a lateral projection of the *frontal*. The quadrate, although present, does not show, as it is under the posterior lateral side of the skull. As usual it articulates with the lower jaw, which is essentially like that of Seymouria. With this information the student should encounter no difficulty in labelling the drawing.

5. Skull of Alligator. The alligator is a recent specialized *Diapsid* reptile. Besides identifying the bones determine its similarities and differences to Seymouria and Dimetrodon. Decide from which of these two types of skull it is more likely to have been derived, and why.

a. Note the general shape of the skull. Locate the *external nares*. Posterior to the very large orbits are two pairs of openings, the temporal fenestrae. The dorsal pair, located on the flat upper surface of the skull, are the *dorsal temporal fenestrae*. On the lateral surface, separated from the orbit

by a thin column of bone, is the triangular *lateral temporal fenestra*. Under an overhanging ledge of bone between the dorsal and lateral fenestrae is a smaller opening, the *external auditory meatus*. At the very anterior end of the ventral surface is a small opening in the mid-line, the *anterior palatine vacuity*. Towards the posterior part of this surface are two very large somewhat elongated openings, the *posterior palatine vacuities*. Through the latter pair of openings muscles pass from the skull to the jaw. In the mid-line posteriorly are two openings, the *internal nares*, separated only by a very thin septum. How do they differ in position from the internal nares of other forms that have been studied? What is the advantage of their position? What bones were involved in their shift of position? Just posterior to the nares, on the posterior surface of the skull, is a small median, unpaired opening for the *Eustachian tube*. This connects with the middle ear, and helps to equalize pressure on the two sides of the tympanic membrane or "ear drum". Locate the *foramen magnum* and the *occipital condyle*. How many bones enter into it? What bones surround the foramen?

b. Along the mid-dorsal line of the skull are the *premaxillae*, the long *nasals*, the unpaired *frontal* (paired in the embryo), and, between the dorsal fenestrae, the *parietal* which is also a fusion of two.

c. The lateral margin of the dorsal surface is formed by the large *maxilla*, which extends posteriorly to the middle of the orbit; the long *jugal*, which extends past the lateral temporal fenestra; the narrow *quadrato-jugal;* and the *quadrate*, which articulates with the lower jaw.

d. The anterior part of the orbit is bounded by two rather small bones. The more medial of these, abutting against the frontal, is the *prefrontal*. The more lateral one, perforated by a small opening that may be seen by looking into the orbit, is the *lacrimal*. The opening in this bone is for the *naso-lacrimal duct*, connecting the eye with the nasal cavity.

e. Lateral to the parietal are two bones on either side. The more anterior one, bounding the anterior margin of the dorsal temporal fenestra, is the *postorbital*. This is continued ventrally to form a part of the small column separating the orbit from the lateral temporal fenestra. Posterior to

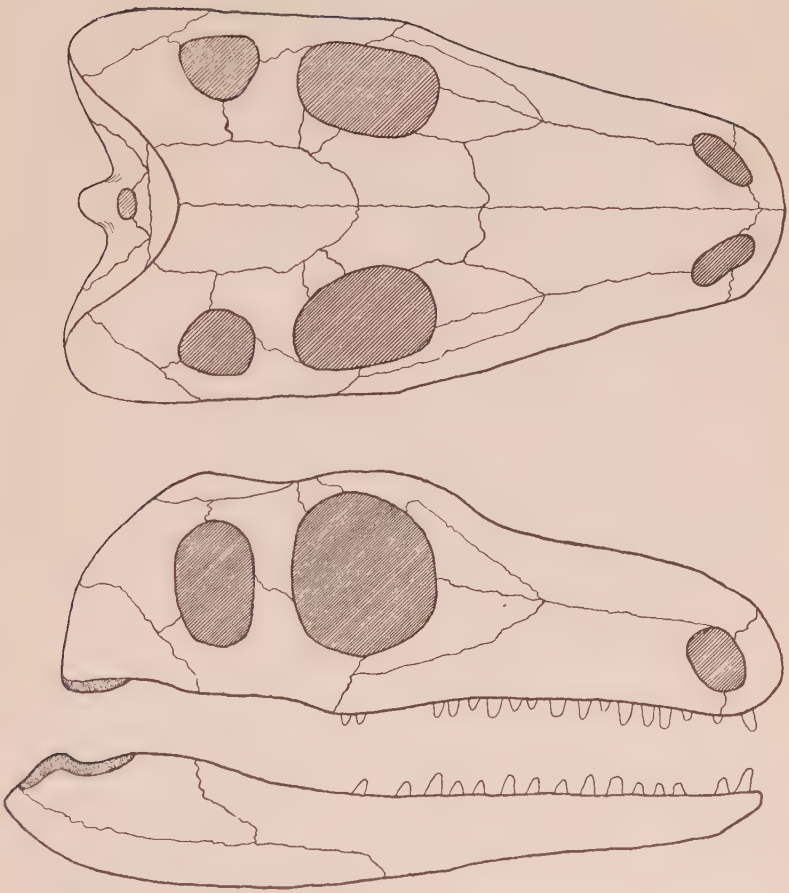

PLATE 14. Skull of Dimetrodon, dorsal and lateral views. The openings are shaded, and the quadrate and articular bones are stippled.

this, forming the ledge of bone overhanging the external auditory meatus, is the *squamosal.*

f. On the posterior surface of the skull the foramen magnum is surrounded by the *supraoccipital,* which does not come in contact with the foramen, the two *exoccipitals,* and the *basioccipital.* The last forms the greater part of the condyle.

g. On the *ventral surface* the premaxillae and maxillae, bearing the teeth, meet in the mid-line. Posterior to these, forming the region between the two large palatine vacuities, are the *palatines.* Posterior to these the *pterygoids* bend markedly ventrally. To them are attached the most powerful jaw muscles. Extending from the lateral edge of the pterygoid to the jugal and forming the posterior margin of the large palatine vacuity is the *transpalatine* or *ectopterygoid.*

h. Note the very small brain cavity, which does not extend further anteriorly than the posterior part of the orbit. The bones of the brain cavity will not be studied. Just anterior to the brain case, however, is a septum-like bone partially separating the two orbits. This bone, the *basisphenoid,* in the living animal has a cartilaginous continuation that does completely separate the two orbits. The *otic* bones are difficult to identify and the *ethmoids* remain mostly unossified.

i. The lower jaw is composed of six bones on either side. Note the two large openings in the jaw. The one on the external surface is the *external mandibular foramen,* and the one on the inner surface the *internal mandibular foramen.* They both serve for the attachment of powerful jaw muscles. The main bone of the jaw is the *dentary* which bears all the teeth. Is there any difference in the attachment of these teeth and those of the amphibia? On the medial surface of the jaw, at the anterior angle of the external mandibular foramen, is a small flat crescent-shaped bone, the *coronoid.* Beginning just underneath the anterior border of this bone, the very flat splint-like *splenial* extends forward almost to the symphysis of the jaws. The angle of the jaw, ventral and posterior to the external foramen, is formed by the *angular.* Above the foramen is a separate bone, the *surangular.* Applied to the medial surface of the posterior ends of the angular and surangular is a heavy compact bone, the *articular,* which articulates with the quadrate of the upper jaw. What is

the difference in origin between this and the other jaw bones? Posterior to the articular surface is an elongation of this bone to which is attached the pterygoid muscle of the jaw.

E. The Mammal-Like Reptile and Mammal Skulls

1. The mammal-like reptile, *Ictidopsis,* which will be used, is one of the Therapsida, the group that gave rise to the mammals. This group is intermediate between the primitive reptiles and the mammals. The Theromorpha, to which Dimetrodon belongs, was mammal-like in a few characters, but not to the extent of the Therapsida. Another member of the Therapsida that is often mentioned in the literature is Cynognathus ("dog-jawed") which is similar to Ictidopsis.

2. Skull of Ictidopsis. Note that the temporal fenestra has become greatly increased in size, and that the bones bounding the margin of the skull ventral to this opening have been lifted above the line of the teeth. Later compare this with the mammal. Note that the teeth are becoming modified in the different parts of the jaw. This *heterodont* condition is typical of mammals. Compare it to the *homodont* teeth of the typical reptiles, in which all are essentially similar. The lower jaw is becoming modified. The *dentary* has developed an ascending process that extends up into the temporal fenestra. The more posterior bones of the jaw are reduced in size, although the *articular* bone still moves on the *quadrate.* Compare this condition of the lower jaw with that of the mammal. What have been the evolutionary changes between the other fossil reptiles and Ictidopsis in regard to loss of bones, reduction or increase in size of bones, the teeth, the fenestra, the lower jaw, the shape of the skull?

3. The Mammal Skull, External View.

a. The following description is based on the *cat* skull. Where the structures vary markedly from the *rabbit* skull the condition in the latter is also described.

b. First identify the *orbit* and *zygomatic* or *cheek arch.* The space above the posterior part of this is homologous to the lateral temporal fenestra. How did it evolve from the reptiles? Locate the *external nares.*

c. Identify the membrane bones of the roof of the skull. Roofing the nasal apertures are the *nasals;* next posteriorly are the

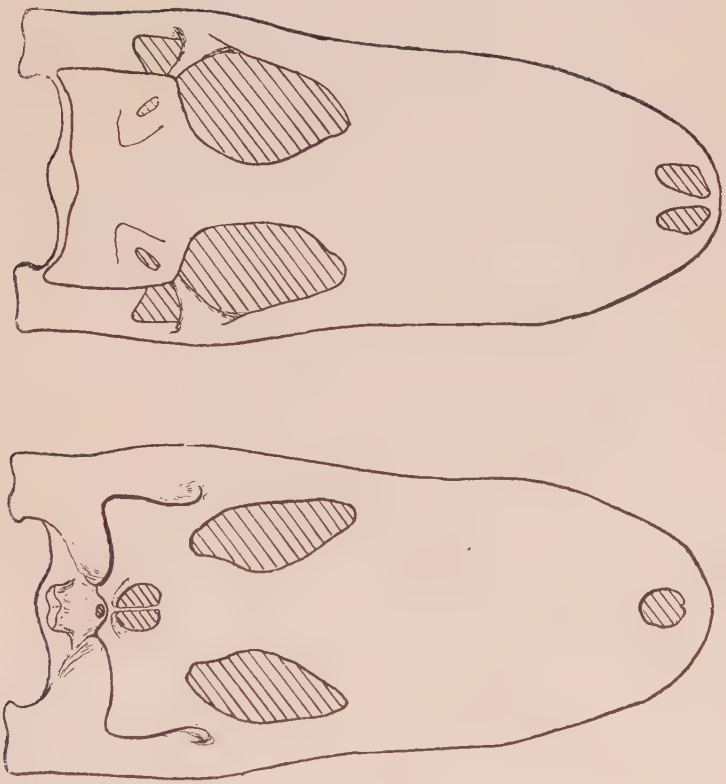

PLATE 15. Alligator skull, dorsal (upper) and ventral (lower) views of skull. The alligator is a diapsid reptile. Fill in sutures, and label the bones and fenestrae.

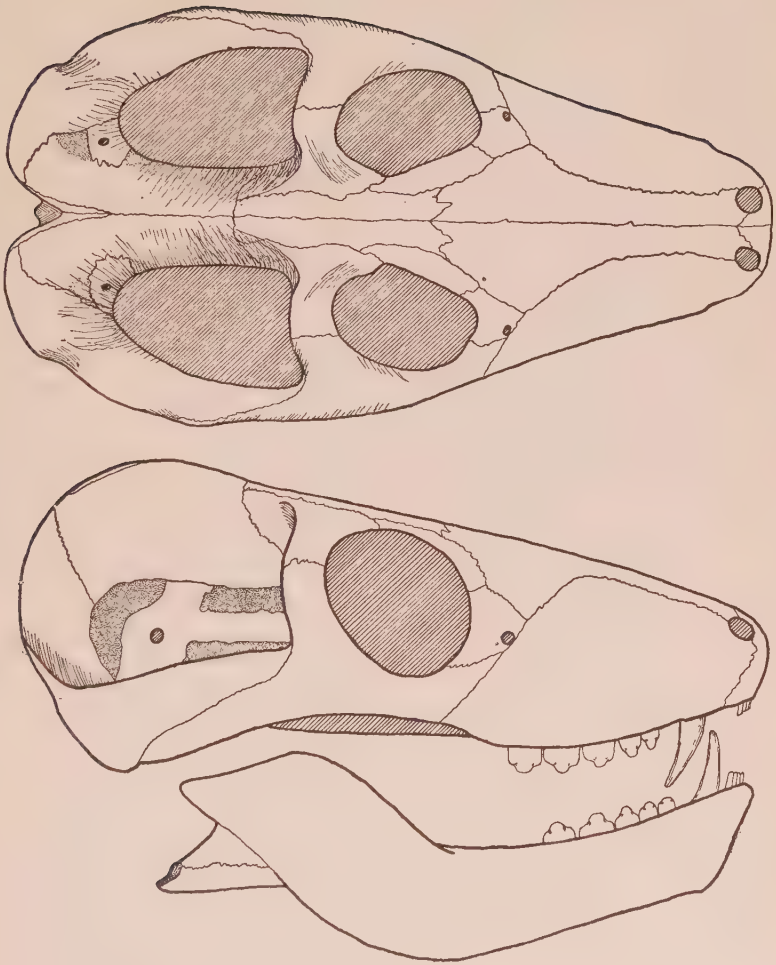

PLATE 16. Skull of Ictidopsis, dorsal and lateral views. The openings are shaded. The stippling at the end of the lower jaw indicates the articular bone.

frontals and last the *parietals*. Between the posterior parts of the last a small triangular bone, the *interparietal*, is sometimes seen in young animals. This is a fusion of the dermal supraoccipitals. In the rabbit the nasals are larger than in the cat, due to the anterior elongation of the skull.

d. The upper jaw is composed of the *premaxilla* and the *maxilla*. In the cat the latter forms most of the face, while in the rabbit the premaxilla is large and forms the anterior half. The maxilla of the rabbit is highly fenestrated.

e. The jugal forms most of the zygomatic arch, a process from the squamosal completing it posteriorly and the maxilla contributing slightly at the anterior end. The squamosal forms the side of the skull. It is a part of the *temporal complex*, a fusion of several bones of the embryo. Immediately behind the *glenoid fossa*, into which the lower jaw articulates with the squamosal, observe the large spherical *bulla*. In the rabbit the dorsal portion of this is marked by a funnel-shaped projection. The *mastoid process* lies against its lateral surface, and the *jugular process* against the posterior. These serve for the attachment of muscles.

f. In the cat the orbit is partly closed off by an ascending process of the jugal and a descending process of the frontal. How does this differ from the postorbital bar of Ictidopsis? In the rabbit there is no division of the orbit from the temporal fenestra.

g. Within the orbit, on the anterior surface, identify the *lacrimal* bone perforated by the *naso-lacrimal duct* which connects the eye with the nose. In the RABBIT this is dorsal to a rounded protuberance that houses the roots of the posterior teeth. The *orbitosphenoid* occupies the middle region of the orbit, perforated by the *optic foramen* for the optic nerve. In the CAT this opening is the most anterior of a row of four in the posterior part of the orbit. In the RABBIT it is a large opening about the middle of the orbit. The limits of the orbitosphenoid in the rabbit are not very clear, as there is a partial fusion with other bones. The *alisphenoid* is located in the posterior-ventral angle of the orbit. It partially encloses the large foramen just posterior (ventral in the rabbit) to the optic foramen, and includes two smaller ones directly in back of these. It sends a wing-like process dorsally between

the squamosal and frontal. In the RABBIT it sends a flattened extension ventrally and laterally, forming a part of the *pterygoid process.*

h. At the back of the skull is the *occipital complex.* In young animals this consists of four separate bones, the paired *exoccipitals,* and the median *supraoccipital* and *basioccipital.* In the mammal what bones bear the occipital condyles for articulation of the skull with the vertebral column? Which in the reptile? How many condyles has the mammal? Reptile? Amphibian?

i. *Ventral surface* of the CAT skull. Identify the *internal nares.* They are about in the middle of the surface, and the openings are directed posteriorly. Anterior to the basioccipital identify the median *basisphenoid.* The alisphenoids extend laterally from it. The *presphenoid* lies just anterior to the basisphenoid. The *pterygoid* abuts laterally against this bone, and projects ventrally on either side as a thin ridge terminating in a spine. The *palatines* form the posterior part of the hard palate, between the pterygoids and the maxilla. The *vomer,* a fusion of the pre-vomer and parasphenoid of lower forms, is a median bone anterior to the presphenoid, and may be seen by looking into the internal nares. It bears a ventral ridge that partially divides the nasal cavity.

j. *Ventral surface* of the RABBIT skull. Identify the *internal nares.* These are in the posterior part of the deep groove. Anterior to the basioccipital is a median bone, the *basisphenoid,* that extends sharply dorsally. It is perforated by a median opening, the "pituitary foramen", a hole in the base of the sella turcica. This will be seen in a sectioned skull. Anterior to the basisphenoid is the median *presphenoid.* The two bones are separated by a small space that is filled with cartilage in the living animal. The presphenoid abuts laterally against the orbitosphenoids. The anterior part of the roof of the mouth of the rabbit is not closed, but has a large opening into the nasal cavity, a condition called the *open palate.* The bridge of bone extending across the roof of the mouth between the two sets of back teeth is composed of: (1) The *maxilla* in the anterior part; and (2) the *palatines,* posterior to the two small openings. The latter extend posteriorly and dorsally, each forming (1) the ventral part of the

orbit and, (2) passing mediad to the maxilla, the anterior part of the pterygoid process. The *pterygoid,* although not present as a separate bone, forms the posterior extension of the "palatine". The *vomer* lies just anterior to the presphenoid, and is a small delicate bone with a low ventral ridge extending into the nasal cavity. It arose as a fusion of the pre-vomer with the anterior part of the parasphenoid.

k. Look through the foramen magnum and observe the sieve-like *cribriform plate* which marks the anterior limit of the brain cavity. This bone is a part of the ethmoid complex. The openings transmit the olfactory nerves. In the rabbit, due to the bend in the skull, this cannot be seen through the foramen but can be seen in sectioned skulls. Within the nasal passage are scroll-like turbinals, which arise from the ethmoid and maxillary bones. These can be seen in the CAT only through the nares and in a sectioned skull. In the RABBIT they may be seen through the openings in the palate.

l. Observe the teeth. The general rules for naming the teeth are as follows: In the *upper jaw* the teeth on the premaxilla are the *incisors.* The first tooth on the maxilla is the *canine.* If a tooth posterior to the canine is preceded by a *milk* or *deciduous* tooth it is a *premolar;* if it is not preceded, it is a *molar.* In the *lower jaw* the anterior teeth are the incisors, the tooth that fits immediately in front of the canine of the upper jaw being the canine. For the posterior teeth the rules for the upper jaw hold. The incisors and canines, as well as the premolars are preceded by deciduous teeth. The CAT has three small incisors on each side of the upper jaw, separated from the single canine by a small space, or diastema. There are three premolars, the first being very small. A single small molar is present. The lower jaw differs from the upper in having two premolars and a well developed molar. If the jaws are fitted together it will be noted that the large third premolar of the upper jaw and the large molar of the lower jaw move closely by one another like the blades of a pair of shears. Teeth that are thus modified for cutting are called carnassial teeth. The *dental formula* of the cat may be written $I\frac{3}{3}$, $C\frac{1}{1}$, $P\frac{3}{2}$, $M\frac{1}{1}$. In the RABBIT the incisors are large and chisel-like, being adapted for gnawing, the canines are absent, and the premolars and molars have flat but ridged

surfaces adapted for grinding. The primitive formula for placental mammals is $I\frac{3}{3}$, $C\frac{1}{1}$, $P\frac{4}{4}$, $M\frac{3}{3}$. In the rabbit it is $I\frac{2}{1}$, $C\frac{0}{0}$, $P\frac{3}{2}$, $M\frac{3}{3}$. With what are these changes correlated? What is the functional advantage of the diastema in the rabbit?

m. The main foramina of the CAT skull are as follows:

(1) *Infraorbital.* This is surrounded by the maxilla, and is situated at the base of the anterior portion of the zygoma. It carries part of the maxillary branch of Nerve V.

(2) *Anterior palatine.* This is on the anterior ventral surface between the maxilla and premaxilla. It carries the nasopalatine branch of Nerve V, and the nasal artery.

(3) *Sphenopalatine.* It is the larger of the two most anterior foramina in the orbit.

(4) *Posterior palatine.* These are small openings in the palatines. They are located about one-fourth the distance forward from the posterior end of the hard palate. Each connects with the smaller foramen lateral to the sphenopalatine.

(5) *Olfactory.* These are the numerous openings previously observed in the cribriform plate.

(6) *Optic.* This is in the orbitosphenoid, and conveys the optic nerve.

(7) *Sphenoidal fissure* (Lacerum anterius). This is a large foramen between the orbitosphenoid and the alisphenoid. It carries Nerves III, IV, VI, and part of V.

(8) *Rotundum.* The more anterior opening in the alisphenoid, carrying part of Nerve V.

(9) *Ovale.* This is just posterior to the foramen rotundum, also in the alisphenoid. It also carries a branch of Nerve V.

(10) *Lacerum medium.* Between the bulla and basisphenoid, for the passage of the internal carotid artery.

(11) *Internal auditory meatus.* On the internal surface of the bulla for passage of the eighth nerve.

(12) *Canalis facialis.* Seen on the internal surface opening almost with the internal auditory meatus. It carries part of the seventh nerve.

(13) *External auditory meatus.* The opening on the outside of the bulla, connecting the external and middle ear.

(14) *Stylomastoid.* Just posterior to the external auditory meatus and between the bulla and the mastoid process. It conveys a part of the seventh nerve.

(15) *Jugular* (Foramen lacerum posterius). Mediad to the bulla, and between it and the basioccipital. It is occupied by Nerves IX, X, XI, and the jugular vein.

(16) *Hypoglossal.* A small opening in the outer part of the jugular foramen. It passes through the exoccipital. It carries the twelfth (hypoglossal) nerve.

(17) *Condylar.* This can be seen within the foramen magnum, perforating the upper part of the inner surface of the condyle. It carries a branch of the jugular vein.

n. The main foramina in the RABBIT skull are as follows:

(1) *Infraorbital.* This is a small inconspicuous opening in the middle of the lateral surface of the maxilla. It is located dorsal to the first premolar. It carries part of the maxillary branch of Nerve V.

(2) *Anterior palatine.* This is represented in this skull by the large anterior open area of the roof of the mouth.

(3) *Sphenopalatine.* An opening mediad to the rounded mass of bone in the anterior part of the orbit. It carries branches of Nerve V.

(4) *Posterior palatine.* One end of the palatine canal which serves for the passage of a branch of Nerve V. The opening is in the roof of the mouth, between the palatine and maxilla. The posterior end of the canal is with the sphenopalatine.

(5) *Olfactory.* These are the openings of the cribriform plate that will be seen in a sectioned skull.

(6) *Optic.* The large opening in the middle of the orbit, carrying the optic nerve. It is in the orbitosphenoid bone.

(7) *Sphenoidal fissure* (Lacerum anterius). This is a large opening ventral and slightly posterior to the optic. It is homologous not only to the sphenoidal fissure of the typical mammal skull, but also includes the *foramen rotundum.* It carries Nerves III, IV, and VI, which pass to the eye muscles, and most of Nerve V.

(8) *Anterior sphenoidal.* This is the most anterior of the openings in the wing-like pterygoid process. It lies lateral to the sphenoidal fissure.

(9) *Middle sphenoidal.* This is immediately posterior and lateral to the previous.

(10) *Posterior sphenoidal.* This will be seen ventrally, mediad to the preceding. It is located lateral to the pituitary foramen which is in the basisphenoid. These sphenoid foramina transmit branches of the mandibular nerve, a branch of Nerves V and VII.

(11) *Lacerum medium.* This is an irregular opening on the ventral surface lying against the anterior face of the bulla. It is homologous not only with the lacerum medium of the typical skull, but also the *foramen ovale.*

(12) *External auditory meatus.* This, which has previously been noted, is the opening from the external to the middle ear. It is surrounded by a funnel-shaped tube of bone.

(13) *Internal* and *external carotid.* The internal opening empties into the lacerum medium. The external opening of the canal is on the median surface of the bulla. The carotid artery enters the skull through the external carotid foramen and passes out again through the internal opening.

(14) *Stylomastoid.* This is between the mastoid process and the bulla, at the point where the funnel-shaped bones surrounding the external auditory meatus leave the bulla. It transmits a branch of Nerve V.

(15) *Jugular.* This is a slit-like opening in the depression between the bulla and the occipital condyle. It transmits a branch of the jugular vein and Nerves IX, X, and XI.

(16) *Hypoglossal.* This is in the front of the dorsal portion of the condyle, directly posterior to the jugular foramen. It transmits the hypoglossal (Twelfth) nerve.

o. The lower *jaw* is composed of only one bone on each side, the *dentary.* The union at the front of the chin is the *symphysis* of the jaws. On the outer surface near the symphysis is the *mental foramen* transmitting a nerve and artery. On the posterior median surface locate the *mandibular foramen,* the

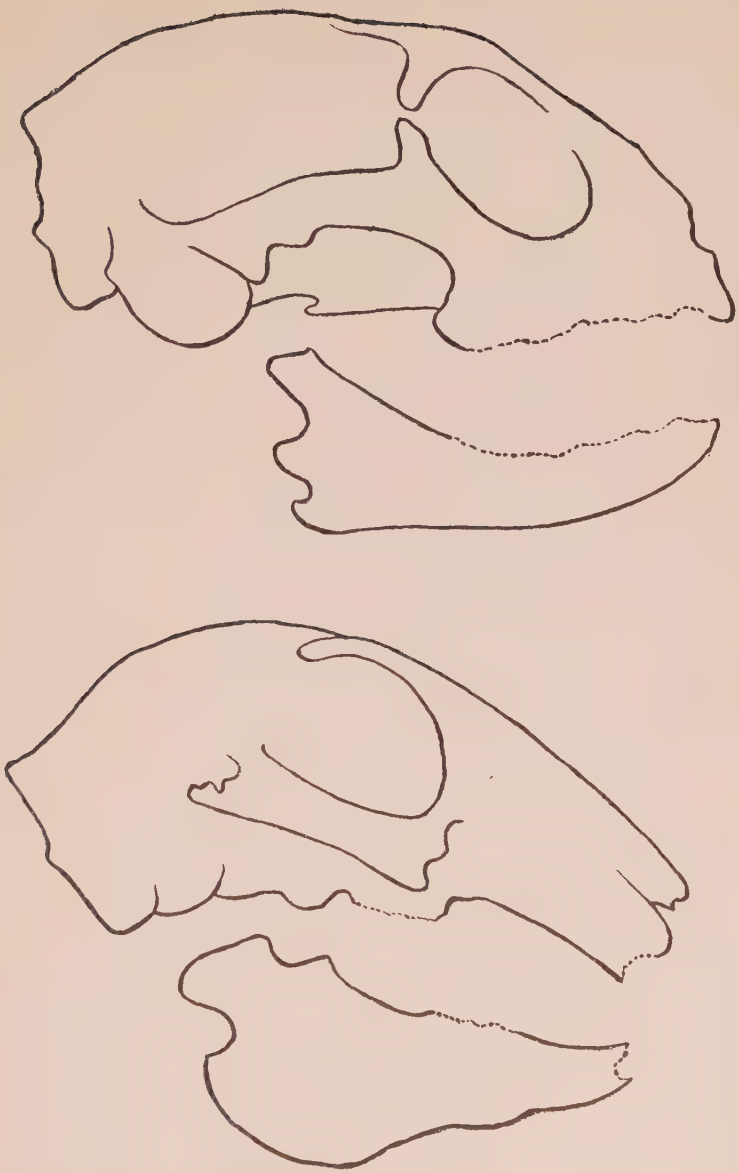

PLATE 17. Lateral views of the cat and rabbit. These are for comparison of the dentition and skull structure of two orders of mammals. The sutures, foramina, and teeth are to be added by the student.

point at which the artery and nerve enter the canal of the jaw. The process which arises dorsally on the dentary is the *ascending ramus* of the jaw. Posterior to this is the *condyle* for articulation with the squamosal.

p. In the outline fill in the sutures of the skull. Add the foramina and teeth in the skull and lower jaw.

4. Mammal Skull, Sagittal Section. These sections are made just to one side of the mid-line in order that the nasal septum may remain attached to one side and be separated from the other. Both sides should be seen.

a. The large *cranial cavity* is divided into three portions:

(1) The *cerebellar fossa*, enclosed dorsally, posteriorly and laterally by the occipital and temporal bones, and anteriorly by a pronounced ridge of bone, the *tentorium*. The latter is extended by a membrane in the living animal. Note the canalis facialis and the internal auditory meatus on the lateral wall of this fossa. What is the function of these openings?

(2) The *cerebral fossa*, extending anteriorly from the tentorium and comprising the greater part of the cranial cavity. It is covered dorsally and laterally by the frontal, parietal and temporal bones, and ventrally by the sphenoids. In the mid-line of the floor of this cavity, note the *sella turcica*, a saddle-shaped depression in the presphenoid. The pituitary body of the living animal extends into this cavity.

(3) The *olfactory fossa*, opening posteriorly into the cerebral fossa, and bounded by the frontals and cribriform plate of the ethmoid.

b. The *nasal cavities* are bounded dorsally by the nasals and a small part of the frontals. The two cavities are separated by a bony partition of the ethmoid. In the living animal this is continued by a cartilage into the external nostril, the two parts thus forming the *nasal septum*. Ventrally the bony part of this septum meets the *vomer*, an elongated bone lying dorsal to the maxillae and palatines. What bones does the septum meet dorsally? The vomer of the mammal is supposed to have been derived from the parasphenoid and pre-vomers of the lower forms.

c. The *turbinals* may be seen in that part of the skull that does not have a nasal septum.
   (1) The *ethmoturbinals* are the most posterior and largest, lying just in front of the cribriform plate. These are covered with olfactory epithelium in life.
   (2) The *maxilloturbinals* are smaller, lie just in front of the ethmoturbinals, and are borne on the maxillae. These turbinals function to strain and moisten the air. Note how they project into the cavity extending from the external to the internal nares.
   (3) The *nasoturbinals* are found on the inner surface of the nasals.
   How does their size compare to that of the others?

d. Various spaces or sinuses are present in the bones of the skull and may be seen in the section.
   (1) The *sphenoidal sinus* is the space in the sphenoid bones. This cavity is also called the "presphenoidal sinus". Why?
   (2) The *frontal sinuses* are present in the frontal bones.

e. *Draw* the hemisected skull. Show the turbinals in the drawing, indicating by dotted lines the extent of the nasal septum as seen in the other part of the skull.

F. Alligator Skeleton

1. The Alligator skeleton will be considered in a general manner, a detailed study of the skeleton being reserved for the mammal. Only such detail as is necessary for an understanding of the phylogenetic development of the Mammalia will be included. Review the study of the skull to make the description complete.

2. Vertebral Column.

a. The vertebral column consists of about sixty-five vertebrae; nine cervical, ten thoracic, five lumbar, two sacral, and a variable number of caudal.

b. The *cervical* vertebrae bear ribs that do not meet the sternum. The *atlas*, which articulates with the occipital condyle of the skull, has no centrum. The second vertebra, or *axis*, differs from the other cervicals in having a wide neural arch, and a very massive centrum, the anterior part of which is the *odontoid process*. The latter is formed by the attachment of the

centrum of the first vertebra to the centrum of the second. Are the two completely fused, or is a suture present?

c. The *thoracic* vertebrae differ little from the posterior cervicals except that the ribs of the anterior eight meet the sternum.

d. The *lumbar* vertebrae bear no ribs, and have shorter transverse processes than the thoracic, but otherwise are essentially like the posterior thoracic.

e. The *sacral* vertebrae are two in number, each with a pair of strong ribs firmly ankylosed to the centrum and neural arch. The distal ends of the ribs are united with the pelvic girdle.

f. In the caudal region note the simpler type of vertebrae and the *chevron bones* attached ventrally to the centra.

3. Ribs and Sternum.

a. Note the eight anterior thoracic ribs attaching to the sternum. In preserved specimens the distal, cartilaginous part may be lost. How many points of attachment are there between the rib and vertebrae?

b. The sternum is a simple cartilaginous structure drawn out posteriorly into two horns, the *xiphisternal* horns. Ventral to the cartilage and extending anteriorly is the *interclavicle*.

c. Posterior to the true sternum is a group of ventral ribs. These are not the homologue of the true ribs, but are of dermal origin and are developed from the ventral plates of the more primitive reptiles.

4. Pectoral Girdle and Anterior Limb.

a. The interclavicle is often included with the pectoral girdle. If it is left out, the Alligator girdle consists of only two bones, the *scapula* and the *coracoid*.

b. The scapula is a large bone, enlarged above where it is terminated by a cartilage, the *suprascapula*. The scapula is thickened below where it meets the coracoid, and with the latter forms the *glenoid cavity*, into which the humerus of the forearm fits.

c. The coracoid is firmly united to the scapula, forming half the glenoid cavity. It meets the sternum ventrally.

d. The *humerus* is the bone of the upper arm. Note the rounded protuberance just below the *head*, the *deltoid ridge*. Distal to the humerus are the *radius* and *ulna*, almost equal in size. The former lies on the preaxial or thumb side of the arm.

e. The *manus* consists of the *carpus* and the hand. The latter is supported by the *metacarpals*, terminating in the five digits.

5. Pelvic Girdle and Limb.

a. The pelvic girdle consists of the *ilium*, *ischium*, *pubis*, and a small unossified cartilage. Note the fusion with the sacrum, where the ilia unite with the vertebral column.

b. The *ischium* is the largest bone of the pelvis, joining the ilium at its proximal end and forming the *acetabulum* into which the femur of the leg fits.

c. The *pubis* is the most anterior bone, and is unique in being excluded from the acetabulum.

d. The *femur* forms the thigh of the posterior limb, and it is joined at the knee by the *tibia* and *fibula*. The tibia is the larger of the two and lies on the preaxial border.

e. The *tarsus*, or ankle, is specialized. The *metatarsal* bones are analogous to the metacarpals, but the fifth metatarsal is vestigial in the Alligator.

G. The Turtle Skeleton

1. Except for the skull, the skeleton of the turtle is very highly specialized. These specializations have been carried by this group for such a long period of time that it has been found difficult to determine exactly how they arose, since in the earliest known direct ancestors many of the characters were already present.

2. The "shell" of the turtle is composed of two parts, the dorsal *carapace* and the ventral *plastron*, which are connected on either side by a bony bridge. Overlying these bones is a horny layer, the so-called "tortoise shell" which is composed of ectodermal scales covering the underlying bone. This will not be considered during this study of the endoskeleton, but will be mentioned later in connection with the integument, or exoskeleton. The plastron is formed as an ossification within the dermis of the skin, and is in part homologous with the abdominal ribs of the alligator. Probably the interclavicle found in many reptiles, also enters into this structure.

3. Vertebral Column.

a. There are eight cervical, ten trunk, no lumbar, two sacral, and a variable number of caudal vertebrae.

b. The *cervical* or *neck vertebrae* are characterized by their great mobility, due to the presence of a "ball and socket" joint between them. The first cervical, or *atlas*, has no centrum. It is present in the embryo, but becomes attached to the second vertebra, or *axis*, as the *odontoid process*. What is the functional advantage of the mobility of the cervical vertebrae?

c. The ten *trunk vertebrae* are highly modified. The *neural arches* are expanded to form the median *neural plates* of the carapace. These may be seen dorsal to the vertebral column. Lateral to the median plates the carapace is formed of bone from two sources. The outer surface is formed of dermal bone, the inner from ossified expanded ribs from the second to ninth trunk vertebrae. The first and tenth ribs do not contribute largely, and are shorter than the other eight. The single head of the ribs may be seen articulating with the vertebral column almost between the vertebrae.

d. The *sacral vertebrae* are posterior to the trunk and are two in number. Their short ribs give attachment to the pelvic girdle. Although the sacral vertebrae are not attached to the carapace, they are firmly fused to the trunk vertebrae anteriorly, thus forming a rigid structure.

e. The caudal vertebrae remain primitive in structure although they are much smaller than the others. Neural and haemal arches are present. The most anterior of the caudal vertebrae is fused to the sacrum.

4. Pectoral Girdle and Anterior Limb.

a. The turtles are unique in that the pectoral girdle is internal to the ribs, instead of lying external to them.

b. The girdle consists of two bones on each side. The *scapula* is an L-shaped bone, with the longer arm stretching dorsally, the shorter extending posteriorly, with the glenoid fossa at the junction of the two parts. The posterior extension is called the *proscapular process*, and is often, probably incorrectly, called the precoracoid. The *coracoid* is the ventral bone of the girdle, extending toward the mid-line. It does not meet its mate from the opposite side. The *glenoid fossa*, a depression for articulation with the arm, is formed between the scapula and coracoid, with the latter forming only about one-third of the depression.

c. The *humerus*, the bone of the upper arm, is very much twisted and bent, allowing more freedom of movement than would otherwise be possible in the rigid shell. Of the two bones in the forearm, the *radius* and *ulna*, the former is the larger and and is on the preaxial border of the limb.

d. The *carpus*, or wrist, is composed of ten small bones. Distal to these are the metacarpals, or hand bones, which are much shorter than in most animals. On their distal ends they support digits. The number of separate elements or *phalanges* in the digits is reduced.

5. The Pelvic Girdle and Posterior Limb.

a. The pelvic girdle consists of three bones on a side, all three entering into the *acetabulum*, the depression for the articulation of the limb.

b. The dorsal bone of the girdle, attached to the sacrum, is the *ilium*. Ventrally the anterior broad *pubis* and the posterior narrower ischium meet their mates from the opposite side. They are separated from each other by an opening, the *obturator foramen*. Note the large opening surrounded by the sacrum dorsally, the ilia laterally, and the pubes and ischia ventrally. It is through this opening that the digestive and urinogenital tracts pass to the outside.

c. The head of the *femur*, or thigh bone, fits into the acetabulum. Distally this bone articulates with the *tibia* and *fibula*. The former is the more slender and is on the preaxial border.

d. There are six bones of the *tarsus* or ankle. Distal to these are the five reduced *metatarsals* supporting on their distal ends the phalanges of the digits. The number of phalanges in the digits has been reduced.

H. The Bird Skeleton (Pigeon)

1. Phylogeny. The skeletal evidence shows that the birds belong to the Diapsid group, more closely related to the Dinosauria than the Crocodilia, but paralleling both in development. They may be considered the most highly specialized living vertebrates, which sprang from the reptiles in the Triassic Period about the time when the earliest mammals evolved from the Therapsida.

2. The Skull of the Bird.

a. The brain case is very large, occupying the entire width of the skull posteriorly. At the orbit the skull narrows, and is continued as the elongated nasal region, and the *beak*. On the dorsal side identify the *parietals* and *frontals*, the latter articulating at the anterior border of the orbit with the *nasal* bones. The *maxillae* are lateral to the nasals, with the *premaxillae* forming the major portion of the toothless beak.

b. On the ventral side locate the *foramen magnum*, surrounded by the *occipital* bones, the *basioccipital* bearing the single *condyle*. The *basisphenoids* are covered by the *basitemporals*, which probably represent the posterior portion of the *parasphenoid*. The *otic capsule* is firmly ankylosed. At the level of the middle of the orbit find the *pterygoid* bones which meet in the mid-line, articulating with the outwardly projecting *quadrates*. From the quadrate a narrow bar extends forward to the beak. The bar is composed of the *quadrato-jugal*, the *jugal*, and a backwardly projecting part of the maxilla. The base of the beak is formed by the maxilla and the *maxillopalatines*.

c. On the lateral side identify any bones which were described above. On the anterior border of the orbit observe the large *lacrimal;* and in the posterior portion, the *alisphenoid*. The septum between the orbits is formed by the parasphenoid and the *mesethmoid*.

d. The lower jaw consists of the *articular*, and four dermal bones: the *angular*, *surangular*, *splenial* and *dentary*.

3. Vertebral Column.

a. The *cervical vertebrae* are fourteen in number, giving an extremely long and mobile neck. The last two bear double-headed ribs, the third to twelfth having vestigial ribs fused to the vertebrae. The *atlas* and *axis* are reptile-like, but have the elements fused.

b. The *thoracic vertebrae* are those which have the ribs attached to the sternum. There are five or six, five being the more typical number. If five are present, the first three are fused; if six, the second, third and fourth are fused. The one following the ankylosis is always free, and the last thoracic is fused to the *lumbar vertebrae*.

c. Beginning with the last thoracic, there are about twelve vertebrae fused into a single mass, which gives support to the pelvic girdle and functions as a sacrum. The five or six following the last thoracic bear no ribs, but have transverse processes united by an ossified ligament. There are two *sacral vertebrae*, and five *caudal vertebrae*, in the general fusion to form the sacrum. Therefore, due to the fusion, the bird sacrum is described as a *syn-sacrum*.

d. There are six free caudal vertebrae, ending in the *pygostyle*, which is a fusion of four or more vertebrae.

4. Ribs and Sternum.

a. The ribs are in two parts, the vertebral and sternal portions. Differing from most vertebrates, the sternal rib of the bird is composed of true bone. Springing from the posterior portion of the vertebral rib is a projection, the *uncinate process*.

b. The sternum is characteristic of the bird skeleton in being flattened into a broad plate of bone. The posterior border presents two notches. Ventrally the sternum is produced into a deep keel, *carina*, for muscular attachments. In the non-flying birds (Ratites) the carina is missing.

5. Pectoral Girdle and Anterior Limb.

a. The *scapula* is long and thin, and is attached at its ventral end by ligaments to the heavy *coracoids*. The latter project postero-ventrally to their attachment with the sternum. The *glenoid cavity* is formed by both the scapula and coracoid. In front of the coracoids is a V-shaped bone, the apex pointed ventrally, which is a fusion of the two *clavicles*.

b. The *humerus* is short and large, though the bone itself is very light in structure. At its proximal end it is pierced by the *pneumatic foramen*, and has a strong ridge for the attachment of the pectoral muscle. The *radius* is slender, the *ulna* is heavier. There are two free carpals, the others having fused with the metacarpus to form the *carpo-metacarpus*, consisting of two rods. On the preaxial border of the proximal end of the carpo-metacarpus is the *phalanx* of the first metacarpal. At the distal end of the heavier rod of the carpo-metacarpus, are two phalanges of the second metacarpal. At the distal end of the carpo-metacarpus, on the postaxial border, is a small phalanx of the third metacarpal.

6. Pelvic Girdle and Posterior Limb.

a. The huge border of the *ilium* becomes ankylosed with the entire syn-sacrum in the adult. As usual, it forms a part of the *acetabulum*, which is pierced by a foramen. From the acetabulum both the pubis and *ischium* extend backward, parallel with the ventral border of the ilium. The ischium is united with the ilium at its posterior end. The pubis is a slender bone, extending backward behind the ischium, and separated from it by the *obturator notch*. Neither pubes nor ischia meet in a symphysis. This is correlated with the large egg.

b. The *femur* is relatively short and strong. At its distal end it articulates with the *tibiotarsus*, which is a fusion of the tibia with the *calcaneus* and *talus*. The *fibula* is small, tapering at the distal end, and not reaching the ankle joint. Distal to the tibiotarsus is the fused *tarso-metatarsus*. The first metatarsal, bearing the *hallux*, is backwardly directed. The second, third and fourth are directed forward, and the digits of these are opposed to the hallux.

I. Vertebral Column, Ribs, and Sternum of the Mammal

1. In the description of the mammal the cat will be used as a type. Most of the differences between the cat and rabbit are simply in the size or proportions of various parts. These minor differences are correlated with the differences in muscular development between running and jumping adaptations. Where the differences are more pronounced, such as in the number of vertebrae, the rabbit condition will be mentioned.

2. The vertebral column of the mammal is so markedly divided into five typical regions (cervical, thoracic, lumbar, sacral, and caudal) that isolated vertebrae can be identified. As a typical vertebra from which to learn the structure, one of the thoracic will be used. The fourth will be described.

3. The nerve cord passes through the *vertebral foramen*, the longitudinal opening through the center of the vertebra. Forming the ventral side of the opening is the heavy *centrum*. Notice that the ends are nearly flat, differing from those of the lower forms. At either end is a thin flat plate of bone, the *epiphysis*, which may be

separated in young animals. The lateral and dorsal sides of the vertebral canal form the *neural arch* which terminates dorsally in the *neural spine*. Owing to the fact that the neural arch arises from only the cranial two-thirds of the centrum, when the vertebrae are articulated an opening is left in the arch, the *intervertebral foramen*, for the exit of the spinal nerve. Extending laterally from the base of the arch, are the *transverse processes*, which bear on the ventral face of the free end a smooth facet for the articulation of the tubercle of the rib. This is the *tubercular* facet. Dorso-laterad to the neural canal is a slight projection extending craniad, the *prezygapophysis*. On its dorsal face, looking dorso-mediad is a smooth oval area, the *cranial articular facet*, which articulates with the *caudal articular facet* of the vertebra immediately craniad. Locate the latter on the *postzygapophysis* at the caudal end of the vertebra. Its facets face downward to meet those of the more caudad vertebra, thus strengthening the joint, while permitting a slight rotary motion.

4. Cervical Vertebrae.

a. The first vertebra, or *atlas*, supports the head and is characterized by its wide transverse processes, a flat neural spine, and the lack of a centrum. On the cranial surface are the two surfaces for articulation with the occipital condyles. On the dorsal anterior surface are the foramina which admit the spinal nerve and the vertebral artery and vein. The blood vessels pass caudad, to enter the short *vertebrarterial canal* which goes through the transverse process.

b. The *axis*, or second vertebra, has a long neural spine and an anterior projection, the *odontoid process*. This was embryologically the centrum of the atlas which later fused to the axis. Laterally are the transverse processes, which are perforated by the vertebrarterial canal. In reality, the ventral part of the process is the rib, which ankyloses with the centrum and transverse processes in such manner as to leave the canal. The centrum has two articular surfaces for the atlas. The neural spine has postzygapophyses.

c. The five remaining cervicals are more or less alike, and the parts are easily identified.

5. Thoracic Vertebrae. In the cat there are thirteen of these, and in the rabbit twelve. The parts of the thoracic vertebrae can

be identified by the description of the fourth (Paragraph 3). There are slight differences, but they all have in common:

a. A *spinous process* projecting from the neural arch.
b. Two prezygapophyses with cranial articular processes.
c. Two postzygapophyses with caudal articular processes which face ventrad, or cranio-ventrad.
d. A centrum, wider laterally than dorso-ventrally.
e. Transverse processes.
f. Articular surfaces for the ribs. From the second to the tenth inclusive, there are two facets on each centrum, the rib thus articulating with two vertebrae. The first and the last three thoracic vertebrae differ slightly in this respect.

6. Lumbar Vertebrae. The seven lumbar vertebrae are heavy, with stout neural spines. The large transverse processes are directed craniad. These processes are actually a fusion of short ribs to the true transverse processes. They are larger in the rabbit than in the cat, as the large jumping muscles are attached to them.

7. Sacrum. The sacral vertebrae are united in the adult into one bone, the *os sacrum* or *sacrum*. The large lateral expansions of the first vertebrae are composed of sacral ribs and transverse processes indistinguishably fused, for the attachment of the ilia. In the cat there are three vertebrae in the sacrum, and in the rabbit four. In the latter the posterior two do not actually come in contact with the pelvic girdle.

8. Caudal Vertebrae. The caudal vertebrae vary in the different species of cat and there is a variation even in the common domestic variety. There are about twenty-two caudal vertebrae in the cat, and about fifteen in the rabbit. The neural spines dwindle to a ridge in the fourth vertebra; the transverse processes become less prominent from the third distally. Posteriorly the vertebrae become more and more simple, until at the end only the centrum remains. In the cat, small bones are present on the ventral side, attached to the cranial ends of the centra. They are the *chevron bones*, functioning as haemal arches, and are usually missing in prepared skeletons.

9. Ribs. Though not a part of the column, the ribs may be considered at this point. Each rib consists of a dorsal bony part and a ventral cartilaginous portion. In the CAT there are thirteen

pairs, the last four not articulating directly with the sternum. These are called "false ribs" but are not to be confused with the haemal or sub-peritoneal ribs to which this term is also sometimes applied. The last (13th) has no connection with the other ribs and is called the floating rib. In the RABBIT there are only twelve pairs of ribs. The last five are false ribs, and of these the last three are floating. The rib attaches to the vertebrae by two processes: a terminal *capitum*, or head, uniting with the centrum, and on the upper surface, the *tuberculum* which articulates with the transverse process. The latter diminishes and disappears on the last three ribs.

10. Sternum. The sternum of the CAT is composed of eight pieces, the *sternebrae*, lying in the ventral median part of the chest and serving for the attachment of the ribs. In the RABBIT there are only six sternebrae. The anterior pointed sternebra is the *manubrium*. The *xiphisternum* is the posterior process of the sternum, and ends in a flat cartilaginous portion. The sternebrae between these two parts form the *corpus sterni*, or body of the sternum, which bears most of the ribs.

11. Discussion. Embryologically a vertebra may be considered as having arisen from eight cartilages which form two incomplete rings around the notochord in each muscle segment. These cartilages are called *arcualia*, and are arranged in pairs. The two pairs forming the anterior ring are called the *cranio-dorsals* and *cranio-ventrals*. The posterior pairs are the *caudo-dorsals* and *caudo-ventrals*. All these names are based upon the position of the respective cartilages. Note that the myoseptum lies between the cranio-dorsals and ventrals of one segment, and the caudo-dorsals and ventrals of the next anterior segment. All vertebrae begin with these anlagen, but their fate in development differs.

In the caudal region of Amia, a Holostean fish, there are two centra to each muscle segment, only one of which has a neural and haemal arch. This is a condition where the anterior and posterior rings of arcualia fused independently of one another. In the Stegocephala a different condition is present. In Eryops, for example, the cranial arcualia have grown forward into the next anterior segment, crowding the caudal arcualia of that segment ventrally, where they form a triangular mass of bone,

the *intercentrum*. Thus the vertebra is in two closely associated parts, the centrum and neural arch having been derived from the arcualia of one segment, and the intercentrum from the other. Due to the anterior growth, the myoseptum is now lying against the sides of the vertebrae instead of between them. This condition progressed further in the Therapsida. In recent reptiles and some mammals the intercentra remain in the caudal region, where they form the *chevron bones* which function as a haemal arch. In the mammal, then, the neural arch is formed from the cranio-dorsal, the centrum from the cranio-ventral, the small chevron bones (if present) from the caudo-dorsals and ventrals. Due to the anterior growth of the cranial arcualia, the rib, which develops in the myoseptum, attaches to the side of the vertebra; and the articulations between the vertebrae are in the middle of the muscle segment.

J. Pectoral Girdle and Anterior Limb of the Mammal

1. The pectoral girdle of most mammals consists of four bones, the paired *scapulae* and *clavicles*. In prepared skeletons of the rabbit and cat the latter are usually missing, as they are very small. In the Primates the clavicles remain as an important part of the girdle.

a. The *scapula* is not articulated with the vertebral column, but is held in place by muscular attachments. It is triangular in shape, with three well-marked borders: the dorsal, or *vertebral;* the anterior, or *cranial;* the posterior, or *axillary*. On the outer surface identify the *spine*, which divides the scapula into two nearly equal regions, or *fossae:* the cranial being the *supraspinatus*, and the axillary the *infraspinatus fossa*. Near the ventral end of the spine is the *metacromion* process, extending laterally and posteriorly. The spine terminates in a pointed projection, the *acromion*, which is connected by fibrous tissue to the clavicle. It is much longer in the rabbit than in the cat. The *subscapular fossa* occupies the entire inner or medial surface. The ventral end, or *apex*, of the scapula is occupied by a depression, the *glenoid fossa*, into which the end of the humerus fits. A slight constriction dorsal to this, at the base of the spine, is the *neck;* and from the cranial side of this, hooking over the glenoid cavity,

is the *coracoid process*, the only remaining homologue of the coracoid of the reptiles.

b. The *clavicle* is a small bone, about an inch long, and has no direct connection with either the manubrium or the acromion.

2. Thoracic Limb.

a. The *humerus* is the bone of the upper arm, or brachium, articulating proximally with the glenoid fossa, and distally with the radius and ulna. It is divided into three parts, the *head*, the *shaft* and the *distal extremity*. Along the outer side of the proximal surface of the head is a ridge-like process, the *greater tuberosity*. On the inner side, projecting anteriorly from the head, is the *lesser tuberosity*. Between the two tuberosities is a deep groove on the anterior surface, the *bicipital groove*, in which lies the tendon of the biceps muscle. On the same side, extending distally from the greater tuberosity, is the *deltoid ridge* to which attaches the deltoid muscle. The distal extremity is marked by two lateral projections, the *lateral epicondyle* and the *medial epicondyle*. Immediately proximal to the latter is the slit-like *supracondylar foramen*. Through this passes a blood vessel in the living animal. The opening is not present in the rabbit. The humerus ends in two flat surfaces for articulation with the radius and ulna. The medial face, or *trochlea*, is for articulation with the ulna, and the outer, or *capitulum*, meets the radius. On the caudal side of the distal end is a deep cavity, the *olecranon fossa*.

b. The *radius* is the shorter bone of the forearm, and lies on the preaxial side. It articulates proximally with the capitulum, and distally with the carpus. Observe that it crosses obliquely over the ulna, placing the *pollex* (thumb) on the medial side of the arm.

c. The *ulna* has a long proximal process, the *olecranon*, forming the elbow. At the base of this projection is the semilunar notch for articulation with the trochlea. The *coronoid process* is on the distal side of the notch. At the distal end of the ulna are two processes, one for articulation with the radius, and the other articulating with the carpus.

d. The *carpus* is composed of seven bones in the cat, nine in the rabbit. In the latter the proximal row consists of four bones: the *navicular* and *lunatum*, articulating with the ra-

dius; the *triquetrum*, articulating with the ulna; and the *pisiform*, a sesamoid bone, lying on the ventral surface of the end of the ulna and not showing on the dorsal surface. In the CAT the navicular and lunatum are fused into a single bone, the *scapholunar*. The distal row of bones in the RABBIT are: the *greater multangular*, *lesser multangular*, *centrale*, *capitatum*, and *hamatum*. The first, second, and fourth are in association with the first three metacarpals. The last is large and gives articulation to fourth and fifth metacarpals, and partially to the third. The centrale is a small bone which primitively lies between the proximal and distal rows. The CAT is similar except that the *centrale* is missing.

e. Distal to the carpals are the five *metacarpals;* and distal to these the *phalanges*, or bones of the digits. Observe that the first (pollex) has only two phalanges while the other digits have three.

K. Pelvic Girdle and Posterior Limb of the Mammal

1. Pelvic Girdle. The pelvic girdle consists of three pairs of bones, firmly united with the vertebral column. In the adult the three are so inseparably fused that they are called the *innominate bone*. In the kitten or young rabbit the sutures are present, and embryologically three separate cartilages give rise to the ilium, ischium, and pubis.

a. The *ilium* is the largest and most dorsal, articulating with the vertebral column, and terminating dorsally in a ridge, the *crest* of the ilium. Ventrally the ilium extends into the *acetabulum*, the deep depression for articulation of the head of the femur.

b. The antero-ventral border of the innominate is formed by the *pubis*, which in the cat does not take part in the acetabulum, differing from the condition in the human. The part of the acetabulum adjacent to the pubis is from a separate ossification, the acetabular bone.

c. The *ischium* is continuous with the ilium, and forms the major part of the acetabulum, and the postero-ventral border.

d. Between the pubis and ischium, and ventral to the acetabulum, is a large opening, the *obturator foramen*, giving passage to the obturator nerve and muscles. In older animals the

pubis and ischium are firmly ankylosed with their fellows in the mid-ventral line to form the pubic and ischial symphyses.

2. Pelvic Limb.

a. The *femur* is the bone of the thigh, and is easily recognized by the spherical *head* with the depression for the ligamentum teres, which assists in holding the femur in place. Viewed from the caudal aspect the following structures may be identified: on the lateral side, opposite the head, is the large *greater trochanter*, separated from the head by the *trochanteric fossa*. In the RABBIT this is divided into two portions, the *first trochanter* hooking over the proximal end of the bone, and the *third trochanter* a large lateral projection. The distinct neck supports the head. The *lesser* (*second*) *trochanter* is on the postero-medial border, distal to the head. It is connected with the greater (first) trochanter by a slight ridge. With what is the greater development of these processes in the rabbit correlated? A slight ridge, the linea aspera, arises from the lateral side of the bone, extending distally and spirally. At the distal end of the femur are the lateral and medial *condyles* for articulation with the *patella* ("knee-cap"), a sesamoid bone.

b. The *tibia* articulates with the femur where the condylar surfaces are separated by a deep notch. Distally it extends to the tarsus. The proximal end of the bone is enlarged to form tuberosities, and between them, on the cranial surface, is the tubercle for the attachment with the patella ligament. Beneath the *external tuberosity* is the small facet for articulation with the fibula. At the distal end is a process, the *medial malleolus*.

c. The *fibula* of the CAT articulates proximally with the tibia, and distally with the tibia and tarsus. In proportion to its length it is the most slender bone in the body. In the RABBIT it is fused to the tibia, and is separate only along the proximal third.

d. The *tarsus* consists of seven bones in the cat, six in the rabbit. The largest, projecting backwards as the heel, is the *calcaneus*. Articulating with the tibia and fibula is the *talus*, or *astragalus*. Distal to the talus on the medial side is the *navicular*. The distal row of tarsals, beginning on the hallux

side, are the *internal, middle,* and *external cuneiforms,* and the *cuboid,* a large lateral element that is a fusion of the fourth and fifth tarsalia of the primitive vertebrate foot. In the RABBIT the internal cuneiform is missing. The *metatarsus* consists of five bones, of which the first is vestigial. The *phalanges* are present only on the four long metatarsals.

L. Comparison of the Vertebrate Skeletons

1. This exercise is for a review. The study of comparative anatomy is more important as a consideration of underlying similarities than minutiae of differences. During the course of evolution many structures are lost, and new ones added; but in embryological development there is great similarity throughout the vertebrates, and most of the skeletal elements can be traced throughout the Sub-phylum.

2. Skull.

a. The brain case can be compared by looking into the foramen magnum. Compare the relative sizes in the dogfish, reptile, bird and mammal. Observe that in the mammal the *calvarium* (brain case) is roofed by the dermal covering, due to the enlargement of the brain. The skull easily adjusts itself, therefore many skull changes are directly dependent on brain evolution. In mammals the brain occupies the major portion of the skull, which is shown particularly by the human.

b. The *fenestrae* make their appearance in the synapsid reptiles. Note that the dogfish has no dermal covering, and the muscles attach on the chondrocranium. In the turtle there is a dermal roof with the muscles attaching to the ossified chondrocranium and on the *underside* of the roof. In the alligator, fenestrae break through and the muscles pass through the roof and attach to the *dorsal* side of the dermal bones in addition to the attachments as found in the turtle. (Compare the drawings of the fossil reptiles in this respect.) In the Therapsida the fenestra widens, and the muscles are left attached on the zygomatic arch, and on the outer side of the skull. The mammal shows a greater widening of the fenestra. The bird skull is so light and specialized that the relationships are difficult to see except in carefully prepared specimens. What is the course of evolution of the fenestrae?

c. Density of skull bones in relation to adaptation should be noted. Aquatic animals as a rule have heavier skeletons and denser bones than land animals. The alligator in this respect is intermediate between the turtle and mammal. A group of turtle skulls including the sea-turtle and a land living tortoise illustrates the point in one order. The flying bird has an extremely light skeleton. Do large fenestrae lighten without weakening the skull?

d. Locate on the mammal skull the parietal, squamosal, lacrimal, and other dermal bones and trace their history back to the primitive reptile, noting the change in position and size. In the same manner trace the history of the replacement bones. Observe that there is actually little change in position or function.

e. The teeth should be compared. How are the teeth attached in Squalus? In the amphibian? The alligator teeth are set in sockets (*thecodont*) which is the same type as shown by the Therapsida and mammals. Observe the gradual development of the *heterodont* condition in Theromorpha and Therapsida. Compare Alligator. Both the turtle and bird have lost their teeth, a secondary adaptation found in other groups. If several types of mammal skulls are available, compare the adaptations within the group.

f. In the *lower jaw* note the relative size of the dentary bone. In typical reptiles there is little difference; in Theromorpha it is larger than in the alligator; the Cynodonts illustrate an increase in size with an ascending process. What is the condition in the mammal? Then follow the shift in size of the posterior elements. Note that in the Therapsids the posterior elements are so small that the dentary is almost in contact with the dermal elements of the skull. In the mammal the articular bone passes into the skull as an ear ossicle. This can be studied with cleared mammal embryos, showing the proximal end of Meckel's cartilage within the skull. (See Appendix II.)

2. Vertebral Column.

a. The processes on the vertebrae vary in the different groups. Recall that in the dogfish the centrum was not completely solid, but contained remnants of notochord; in land verte-

brates the centrum is solid and ossified. The dogfish processes consisted of a neural and haemal arch, the latter being the fused lateral processes. In the alligator the neural arch has two pairs of processes, one anterior and one posterior. In the tail region are the chevron bones, which have a homologue in the cat, but none in man. Observe in the mammal the more complicated pre- and postzygapophyses. Do these processes add to the strength or flexibility of vertebrae?

b. Count the number of cervical vertebrae in several Amphibia and Reptiles. Is the number constant? The Therapsid has six or seven, and seven is the typical number for mammals. Edentates may vary from this number, having more or fewer, and the Cetacea show a marked fusion of the neck vertebrae.

c. In the thoracic region notice the neural spines. With what adaptations are the high spines correlated? The bird has an almost complete fusion of these vertebrae. In what way is this an adaptation for flight?

d. The sacrum is usually limited to one vertebra in the amphibia; reptiles normally have two; the mammal has two, three or four true sacral vertebrae, though there may be a fusion of others to give strength; and the bird embryologically has two, but ankyloses with the ilium bring most of the posterior vertebrae into the syn-sacrum.

e. Caudal vertebrae are usually very primitive in structure, and very variable in number. The alligator uses his tail as a defensive organ, and has bony prominences to the tip for muscle attachments. Compare the structure of the caudals in the cat. What type vertebrae would you expect in the tail of a monkey with a prehensile tail?

3. Pectoral Girdle and Anterior Limb.

a. Compare the reptile and mammal scapulae. The spine of the mammal scapula is homologous with the anterior border of the reptile.

b. The *clavicles* are missing in the alligator and turtle, but present in the typical reptile. In the cat and rabbit it is minute, and in horses and deer it is missing. In arboreal forms, and groups in which the arms are moved in several planes, it is well developed.

c. The *coracoid* bones are well developed in most reptiles, birds, and Monotremes. In embryos of Marsupials the coracoid cartilage meets the sternum, but is left in the adult as a process of the scapula. In placentals the coracoid is only a process.

d. Compare the size and position of the *humeri*. The radii and ulnae are very similar, except that the mammal has a large olecranon process for the attachment of muscles. Note the differences in the metacarpals and phalanges. What is the position of the metacarpals in the reptile? The cat? How are the metacarpals and phalanges modified for flight in the bird?

e. Study the girdles and limbs as a whole. What is the position of the mammal legs in relation to the body? Observe how the weight of the reptile is carried on the girdle, and when the body is raised from the ground, how the "thrust" would be against the glenoid fossa. From this point it spreads against the coracoids and scapulae. Compare the cat. Where is the thrust of the weight? The cat has an underslung body, the weight being carried by the suspending muscles. Would this be possible with the leg position of the reptile?

4. Pelvic Girdle and Posterior Limb.

a. The *ilium* is the point of attachment between the vertebral column and the hind legs. Observe the size in the reptile, the bird, the cat, and man. How is this correlated with the weight carried on the hind legs?

b. The *ischium* is posterior in position in the vertebrates; and though the *pubis* arises anterior to the ischium, its growth is often backward. Compare the pubis in the reptile and bird. Both types of pelvis are found in the Dinosaurs, dividing them into two distinct groups.

c. Compare the strength, and perhaps fusion, of the tibia and fibula of the groups.

d. In the tarsus note the size of the bones. The muscles of the calf of the leg attach on the tarsal bones. Is the tarsus of the cat adapted for strong muscles?

e. The position of the foot varies in different groups. Man keeps his heel upon the ground, the *plantigrade* position. The cat

stands upon the ball of the foot, the *digitigrade* position, which is most efficient for springing. In animals which evolved upon dry or grassy plains, where a selective value was placed upon speed, the *unguligrade* position developed. The foot rests on the tips of the digits. This is found in the horse, deer and other ungulates.

PART VI

EXOSKELETON

A. Dermal Structures of the Skin

1. Dermal Denticle (Placoid Scale) of the Elasmobranch.

a. The embryology of the dermal denticle is very similar to that of the tooth. The greater part, the *dentine*, is derived from mesoderm, and the outer covering of *enamel* is from ectoderm. Integumentary structures which are derived partly or entirely from mesoderm are *dermal* structures. Structures which develop entirely from ectoderm are *epidermal*.

b. Hold a piece of skin (preferably cleared as in Appendix II) to the light and observe the enamel-covered spine projecting above the skin, and the *basal plate* which is embedded in the skin and supports the spine.

c. Under low power study isolated denticles (see Appendix II). The basal plate varies in shape in different parts of the body, and is markedly different in species. The *pulp cavity* is apparent as the cavity in the dentine, and projects up into the spine.

d. The dermal denticles are homologous with the scales of fish and the dermal plates of fossil amphibia, recent Coecilia, and many reptiles. The dermal plates are homologous with the dermal bones of the head.

2. Ganoid Scale.

a. Study a piece of the skin of the sturgeon (Acipenser) or the gar-pike (Lepidosteus).

b. In the sturgeon the plates are separated, lying in five rows. The striations radiating from the center should be noticed, and compared with the similar radiations in the skull of a young mammal.

c. The scales of Lepidosteus lie close together, forming a tile-like covering for the body. Acipenser, Lepidosteus, their allied genera, and Crossopterygii have the enamel replaced

by a cell-less ganoine arranged in lamellae on the surface. From this fact the groups are often classified as "Ganoids".

3. Cycloid Scales.

a. This is the earliest form of flexible, overlapping scales. It is found in a few ganoids and teleosts. Observe the scales from the Holostean fish, Amia. The scales are set in sockets in the skin, their projecting edges covering the more posterior scale, in a shingle-like manner.

4. Ctenoid Scales.

a. Ctenoid scales are typical of the majority of fishes, and differ in having the attached portion highly fluted. The arrangement has been noted under cycloid scales. This can be noted by comparing with the scales of a perch or other teleost in their normal position.

b. In the perch and similar fish the projecting part of the scale bears rows of small projections.

c. Under the microscope it will be seen that the scale is covered with concentric lines, supposed to be lines of growth.

B. Skin and Epidermal Structures

1. Discussion. All vertebrates are covered with "skin", composed of both dermal and epidermal parts, but all recent vertebrates have their skin complicated by dermal structures or by epidermal structures such as glands, scales, feathers or hair. The student should keep in mind the fact that the dermal structures studied are merely outgrowths of the underlying layer of the skin, just as the hair is an outgrowth of the ectodermal layer. In the following exercises the skin will be studied with its ectodermal growths.

2. Skin of the Frog.

a. Amphibian skin can best be studied in thin cross-sections under a microscope. The glands and blood supply can be observed by injecting a small frog with a gelatine coloring mass and mounting a fragment of the skin on a slide.

b. The *epidermis* consists of several layers of epithelial cells. The deeper *dermis*, or *corium*, can be identified by its loose connective tissue structure and the heavy parallel fibers as a base. In the animal the skin is attached to the body by sub-

MUSEUM ASSOCIATES
LOS ANGELES COUNTY MUSEUM
THE LIBRARY

cutaneous connective tissue. At irregular intervals will be seen large cavities which are sections of the flask-shaped mucous *glands*.

c. Under high power study part of the *epidermis*. It is composed of two layers. The outer *stratum corneum* is closely packed, the cells being flattened and the outer ones lifeless. The inner *stratum Malpighii*, or *stratum germinativum*, is composed of larger cells, the deepest layer being a straight row of columnar epithelium. These are the generative cells, and if the section was made in a young frog numerous cells in process of mitosis will be seen. By division new cells are formed which are pushed outward, becoming flattened near the surface.

d. The dermis contains the nerves and blood vessels. The fibers are more loosely packed than in most reptiles and mammals, but heavy enough to make the skin tough. Scattered through the upper network of tissue in the dermis are the irregularly shaped, pointed *pigment cells*, forming a layer beneath the epidermis. The change of color in various amphibia is due to the contraction of the dark spots, causing the animal to get lighter in color.

e. *Cutaneous glands* are the most conspicuous structures in the skin of a frog, secreting mucus which keeps the skin moist. They are flask-shaped, and are formed as an invagination of the epidermis. The invagination pushes down into the dermal part of the skin, but the cells are ectodermal. Find a gland which has been cut through the *lumen* which connects the spherical gland with the exterior, and study the continuity of cells with those of the epidermis.

f. Many parts of the frog contain so-called *poison glands*, which are very large, rounded areas, appearing granular in section. The secretion is acrid and distasteful, and has defensive not offensive value as a selective character.

3. Skin of Reptiles.

a. The reptile has ectodermal scales, which may have dermal plates lying under the outer layer. Among recent reptiles the plates are particularly characteristic of the Crocodilia and Chelonia, and were common among the extinct ones. In lizards and snakes the scales are usually small, in the latter the ventral scales being modified as flat, parallel *scutes*. The

scales of turtles are very large, thin plates covering the bone, and the tortoise shell of commerce is from the plates of the sea turtle.

b. Observe a lizard or snake and note that each scale overlaps the posterior one, and is slightly concave on its ventral surface.

c. If a section of the skin can be studied, the epidermal scales will appear as a saw-tooth edge, the *stratum corneum* being thick. The *stratum germinativum* underlies it, and has much the same structure as was observed in the frog. Where the ventral surface of one scale merges into the next scale, a *sense organ* will occasionally be sectioned. This appears as a minute papilla. Nerve fibers end in this organ, and the papilla has an elongated sensory "hair" projecting from it. The structure is supposed to be homologous with the hair of mammals. The *dermis* lies in loose bands of tissue, rising into the scale as a *papilla*. The connective tissue next the epidermis is very loose, but gets more compact toward its inner margin, where it passes into the subcutaneous tissue.

4. Integument of the Bird.

a. The *scales* of a bird are similar to those of the reptile, and are found on the feet and lower legs. Epidermal claws are found on the toes, developing like the *beak*, from a thickening of the stratum corneum.

b. *Developing feathers* in a cross-section of a ten or twelve day old embryo chick show a striking similarity to developing scales, and feathers and scales are considered as homologous structures. In development of the feather the epidermis invaginates to form a *follicle*, and the feather grows outward as a scale-like structure from the papilla at the base of the follicle. In the slide study the invaginating *follicle*, the *papilla* from the dermal layer covered by the ectodermal cells, and the feather growing outward in the follicle.

c. The skin of the bird can be studied in the same slide. The two layers are easily identified. Observe the inpocketed stratum germinativum and the stratum corneum, both of which pass into the follicle and over the papilla.

d. *Feathers* are of three types, the *down feathers* being the earliest and simplest. They cover the nestling, and a few may be found among the feathers of the adult. Pluck a few down

feathers from a day-old chick or other bird and mount on a microscope slide. If mounted in balsam they may be kept permanently. Observe (1) the short *quill*, which attached proximally to the papilla; (2) the *barbs*, which arise from the quill in a circle; and (3) the *barbules*, coming off from either side of the barb.

e. *Contour feathers* are the main covering of the adult, and vary in size and shape over the body. They are arranged in definite areas, as can be observed in a plucked pigeon or other bird. The feather has a central axis, or supporting structure, which is in two parts. The proximal *quill* is hollow, with a proximal opening, the *inferior umbilicus;* and a distal opening, the *superior umbilicus*, through which projects a tuft of small barbs. The distal part of the axis is the *rachis*, extending from the superior umbilicus to the tip of the feather. Along the rachis is a distinct groove, the *umbilical* groove. The *barbs* are parallel rays, extending outward from either side of the rachis. The *barbules* are minute rays from the barb. Study with the hand lens and notice the method by which the barbs are held together to form an unbroken surface on the feather. The rachis with its barbs and barbules is called the *vane* of the feather.

f. The *filoplume* is a small, degenerate contour feather, located among the contour feathers. These are the "hairs" left when a bird is plucked. Under a hand lens or low power of the microscope it will be seen as a thread-like central shaft with a few terminal barbs.

5. Integument of Mammals.

a. Many mammals have scales similar to those of the reptile. These can be observed on the tail of the rat or mouse. Observe the overlap of the scales and the relation of the hairs to the scales. Manis (Order Edentata) has large scales with several hairs between each. This condition of hairs between scales is thought primitive, and supports the homology of the sense organs under the scales of reptiles with the mammalian hair.

b. Study hairs of several mammals under low power of the microscope. Hair is as typical of mammals as feathers are of birds, being found in no other group of the vertebrates. Ob-

serve that the proximal end is expanded where the hair grew from the papilla, and that the hair is covered with overlapping cornified cells without nuclei. In human hair the scalation is slight, the hair being fairly smooth. In the bat (Chiroptera) the scales are long and project sharply from the central core of the hair. Compare wool, and hair from other mammal groups. What is the relation between the *cuticle* of the hair and the felting ability of certain hairs?

c. Study a cross-section of human scalp. First study under *low power* to look over the whole section. It is rare that a hair is cut along its entire length in the skin, so the various parts must be located in different parts of the section, and then synthesized. On the skin find the *stratum corneum*, and the *stratum Malpighii*, which can be seen to extend down into the follicle. The *hair* consists of the *shaft*, that portion which extends above the skin, and the *root*, the part that is embedded in the skin. At the lower end of the root, notice the bulb-like expansion, the *hair bulb*, under which is a cup-shaped depression which receives an extension of the dermis, the *papilla*. On the bulb, notice the *outer root sheath* which is continuous with the epidermis, and the two *inner root sheaths*. Above the papilla is the longitudinal core of cells, the *medulla*, which forms the central axis of the hair. On either side of the medulla in the section, and forming a hollow cylinder around it in the complete hair, is the *cortex*. The outer narrow layer is the *cuticle*. Observe that near the bulb the cuticle is formed of columnar cells that become flattened distally. Extending into the dermis from the upper half of the follicle may be seen the conspicuous *sebaceous glands*, which keep the hair oiled. The cells of this gland never rebuild, but become filled with oil and then are cast off with the contained oil. New cells are formed at the outer edges of the lobes of the gland. *Sweat glands* may be seen opening through the epidermis. They are tubular glands, having highly coiled bases in the dermis.

d. Study and compare the *claws* and *nails* of several mammals. The epidermal claw, or nail, is supported where it leaves the digit by the *unguis*, lying between the ball of the digit and the nail.

e. The *horns* of a cow or similar Artiodactyl should be observed. The outer ectodermal horn overlies the bony core, which is a

part of the frontal bones. The horns of the cow are never shed but continue growing from the base throughout life.

f. The *antlers* of deer differ. They are shed each year, and as they grow the skin grows out, covering the bony core. This skin is called the "velvet", and is the ectodermal part. It constricts at the base and falls off, leaving the core as the antler. It is obvious that the antler can then grow only by being shed and a new one developing.

g. The horns of the Rhinoceros, the "whale-bone" of toothless whales, and the beak of Ornithorhynchus are other epidermal structures.

PART VII

EXTERNAL ANATOMY

A. Necturus

1. Necturus is a perennibranchiate (persistent gilled) *Urodele*. The gills are not homologous with those of the fish, but are a larval character that developed when the Crossopterygians took to land, indications of the gills being found in the fossilized larvae of the Stegocephala. The persistent gills are found only in water-living forms. From a study of these and the Axolotl, the Perennibranchiata are considered by many anatomists to be permanent larvae.

a. Note the mucous character of the skin. This is much more apparent in living animals than preserved ones.

b. The body is typically vertebrate in shape, intermediate in form between that of the fish and lizard. The *head*, *neck*, *body* and *tail* are present. The neck is only a slight constriction, and the body passes insensibly into the tail.

c. The *head* is broad and flat, the mouth being terminal and supplied with fleshy lips. Recall the condition in the Dogfish.

d. Locate the *eyes*. They are small and covered with a transparent portion of the skin which becomes rather opaque after the animal is immersed in formalin.

e. There is no external ear, and the middle ear is degenerate, being represented in the skull by an oval opening in the bones. The *columella* is present but embedded in muscle and connective tissue. What is the homologue of this bone?

f. Find the *nostrils*, which communicate with the pharnyx by the *internal nares*. Probe the opening. How does Necturus differ from the Dogfish? What is the function of this opening? Compare the function of the nares in Squalus and Necturus.

g. Observe the limbs, identifying the parts of each. Which is the preaxial border? How many digits has each foot? This is a typical amphibian condition, both in fossil and recent forms.

h. The *tail* is the region posterior to the body cavity and *cloacal aperture.* The tail is *diphycercal,* that is, symmetrical in respect to the vertebral column. What other groups have a cloaca? Is the cloacal aperture longitudinal or transverse?

2. Make a longitudinal incision along the ventral surface *through the skin only.* In specimens in which the abdominal cavity has been opened for injection the skin should be loosened from the muscles at the edges of the incision. Make a similar incision through the skin along the mid-dorsal line. Loosen the skin from the underlying muscles with the fingers, and pull the skin from the entire body. The *gills* should be left in place. The white tissue between the skin and muscles is the subcutaneous connective tissue and may be removed. The flask-shaped mucous glands can be seen in the cut edges of the skin.

B. Turtle

1. The turtle is one of the Chelonia, the only living representatives of the Anapsid reptiles. The plastron has probably been removed for injection. If it has not been removed do so at this time (Appendix III).

a. The "tortoise shell" which covers the plastron and carapace is an ectodermal structure homologous with the scales of other reptiles. There are several rows of these scales or plates. Insert a scalpel beneath the edge of one scale of the middle of the carapace and peel it off. Note the bony plates of the plastron. These plates were described in connection with the skeleton.

b. Find the body regions, as far as possible. Is the body specialized or primitive in proportions?

c. Observe the shape of the head, and the horny "beaks" which function as teeth.

d. On the side of the head, in the posterior part, is a rounded area with relatively smooth skin. Underlying this is the *tympanum,* the "ear drum". Slit the skin to find this. Slit the tympanum to see the small bone attached to its inner surface. This bone, the *columella,* connects with the internal ear.

e. The *eyes* have become opaque in a preserved specimen, but in a freshly killed one they are still transparent. Are the *eyelids* present? Is there a *nictitating membrane?*

f. The *nostrils* are on the anterior end of the snout. In what part of the mouth are the internal nares?
g. The *limbs* are short and strong. How many digits are there on each foot? Is the number typically reptilian? Recall the lizard formula.
h. The opening of the *cloaca* is on the base of the tail. Is it relatively further posterior than in other animals?
i. How are the head and tail withdrawn into the shell?

C. Alligator

1. The Alligator is an American representative of the Crocodilia. Do you recall any others of North America? What is the greatest embryological difference between Necturus and Alligator?

a. Note the arrangement of the scales. Below the large dorsal scales are bony plates. How does the shape and size of the dorsal scales differ from those on the ventral surface?
b. Find the body regions. Is the body round or flattened? Is the neck distinct?
c. Observe the shape of the head and the elongated snout.
d. The eyes are relatively small. Are eyelids present?
e. Posterior to the eyes notice the flaps covering the *external auditory meatus*. By opening the flap, the ear drum (*tympanum*) may be seen covering the middle ear or *tympanic cavity*. In the cavity is the *columella*. Recall the opening of the Eustachian tube into the pharynx. What is the homologue in the dogfish?
f. The *nostrils* are close to the end of the snout, and have a circular band of muscles (sphincter muscle) around them for closure under water. Recall from your study of the skull the position of the internal nares.
g. The limbs are short and strong. Count the digits on each foot. Is this number typically reptilian? Recall the lizard formula, which is primitive in the reptiles.
h. The tail is large and powerfully muscled. Is it used in swimming? The *cloaca* should be located. In what direction does the slit extend?

2. The body cavity has probably been opened for the injection of the circulatory system. Begin at this incision and separate the

skin from the muscles. Make an incision through the skin from this opening to the symphysis of the jaw. *Be very careful* not to injure any of the muscles. Especial care will be necessary in the shoulder region. Now split the skin to the cloaca; cut around it leaving the skin on an area half an inch in every direction from the aperture. Remove the skin from the entire body except the tail and dorsal surface of the head.

D. Bird

1. The description applies most directly to the pigeon, but applies to any other bird as well.

a. The neck is long and mobile, the body rounded, and the tail shortened to a *uropygium.*
b. Observe the horny beak. At its base find the *cere,* a spongy structure occurring in a few families of birds.
c. Locate the *eye.* How many lids has it? Under the outer lids observe a thin fold of skin, the *nictitating membrane.*
d. Behind each large eye is the *auditory* aperture.
e. Pluck the feathers from the entire animal. Observe that the feathers are restricted to certain areas, the *pterylae.* The relatively bare regions are *apteria.*
f. Below the uropygium is the *cloaca.*
g. Identify the parts of the leg and wing.

E. Mammal

1. The mammal external anatomy should be studied before skinning.

a. Locate the regions of the body, and the relative size of each as compared with Alligator or Turtle, Necturus, and Squalus. Note the short face, the size of the cranium, and the *pinna,* or external portion of the ear. This external ear is peculiar to the mammals.
b. The body is divided into *thorax* and *abdomen.* On the ventral surface are the paired *teats,* the openings of the *mammary* (milk) *glands.* Is there any evidence of teats in the male?
c. Observe the clawed digits. What is their number? Notice the angle of the limbs with the body.
d. The hair need not be studied, but the large tactile hairs, (vibrissae) on the nose should be observed. Is it possible that hairs first functioned exclusively as tactile organs?

e. Note the tail. How does its relative size compare with that of other mammals?

f. In the male, below and anterior to the anus, are two rounded eminences. This double pouch is the *scrotum*, containing the two *testes*. Anterior to the scrotum is a median prominence, the *prepuce*, the fold of skin covering the *penis*.

g. The female external genitalia are located in the same position as the scrotum of the male. The fold of skin surrounding the urinogenital opening forms the *labia majora* ("greater lips") which are homologous to the scrotal sacs. The urinogenital opening in the female mammal is called the *vulva*.

2. *Skin* the entire animal but leave the skin attached immediately around the external genitalia. There are two muscles that should be noted as the animal is skinned:

a. The *panniculus carnosus*, covering the side and back and adhering closely to the skin. Notice how the fibers are attached. This muscle enables the animal to shake its skin, the homologous muscle being rudimentary in man. It arises from several groups of muscles, but mainly from the latissimus dorsi.

b. The *platysma*, covering the sides of the neck and face. It is one of the branchiomeric muscles.

3. After the animal is skinned, the following *salivary glands* should be studied, as they may be displaced and destroyed by the work on the muscular system previous to the work on the digestive system.

a. Just ventral to the pinna of the external ear, find the *parotid* gland. It extends ventrally from this position, posterior to the angle of the jaw, and may even extend onto the ventral surface. Its duct leaves the gland near its dorsal portion, and extends anteriorly across the large muscle (masseter) on the cheek. Trace it to where it pierces the mucous membrane of the cheek and enters the mouth cavity.

b. The *submaxillary* gland, a large rounded pinkish mass, will be found mediad to the masseter muscle. Loosen it from its connective tissue, and on its medial surface find a duct which leads upward and slightly forward to the mouth. In the path of this duct will be found the smaller *sublingual*

gland. In the RABBIT this is flat and has several ducts emptying into the mouth. These are very difficult to find. In the CAT the sublingual is elongated, and its duct passes parallel to that of the submaxillary gland. The cat has another gland, the *molar*, which is lateral to the molar tooth.

PART VIII

MUSCULAR SYSTEM

A. Development

1. In all vertebrates the muscles develop from the mesodermal somites, which arise lateral to the notochord. These somites grow laterally, and in holoblastic forms soon meet ventrally to surround the primitive gut. But in meroblastic forms the muscle plate grows laterally around the large yolk, a small portion later constricting around the enteric canal. The mammal ovum is small and cleaves holoblastically, but almost from the beginning the development is like that of its reptilian ancestors. The chick is used in this exercise as its development is typical of the amniotes, and is simpler than that of the mammal.

The vertebrate embryo develops more rapidly at the cranial end, consequently many developmental stages will be shown in sections of the same embryo. This is particularly noticeable in the neural tube, where the primitive brain will be taking shape while the posterior end of the tube is hardly more than a flat plate of ectodermal cells. Therefore, the posterior sections show the condition through which the more anterior passed at an earlier stage, and the course of development can be followed by beginning caudally and proceeding craniad.

2. 33-Hour Chick: Serial Sections. At thirty-three hours the three primitive regions of the brain, the optic vesicles which give rise to the eyes, and the heart are laid down. The age is identified by the number of somities, twelve being the normal number for this period of incubation. The embryo is removed from the yolk before sectioning.

a. Select a section from the caudal third of the animal, where the section appears flat, with a depression on the dorsal side. The latter is the neural groove. Observe that it is continuous with the dorsal layer of ectoderm, and is thicker than the lateral part of the layer. Ventral to the groove, in the

median line, is a round group of cells, the notochord; and in contact with the latter, and bounding the ventral side, is the endoderm. Between the very thin endoderm and the ectoderm is a paired mass of cells extending laterally from the notochord, the *mesoderm.*

b. Observe that a short distance from the notochord the mesoderm becomes constricted. Lateral to the constriction a split will be noticed, separating the mesoderm into dorsal and ventral layers. In later development the split becomes the coelom. The dorsal layer is the lining of the outer wall of the body cavity and is the *somatic* layer of the mesoderm; the ventral *splanchnic* layer is lying in contact with the gut.

c. At the constriction noted above, between the vertebral region and the lateral split region, is the *intermediate* mesoderm or *mesomere.* The embryonic kidney develops from this region.

d. Study a more anterior section, where the vertebral part of the mesoderm is triangular in shape, and the neural groove has closed to form the neural tube. Note that the constriction between the vertebral and lateral regions is very marked. The coelomic split is more apparent, and the splanchnic mesoderm together with the endoderm is growing ventrally to cut off the gut. Near the mid-line, ventral and lateral to the notochord is a pair of openings, the sectioned dorsal aortae.

3. 48-Hour Chick: Serial Sections. The forty-eight hour chick has most of the organs laid down. Locate a section in which the closed neural tube, the notochord, and the aortae appear as in "d" of paragraph two. The mesoderm will be greatly thickened, and the ectoderm will have pushed ventrally to form a deep groove on either side of the embryo. The splanchnic layers almost meet ventral to the gut, and this region of the splanchnic layer is greatly thickened. The embryo has turned and is lying on its left side which will account for the seeming distortion of the layers.

a. Trace the ectoderm and the somatic layer of the mesoderm, which are in contact, and note that they are growing dorsally over the embryo, to either side of the groove previously ob-

served. In more anterior sections the two ridges will be found in contact dorsally, forming a cavity around the embryo. This space, the *amniotic* cavity, soon fills with fluid, and serves as a protection for the embryo. The wall of the cavity, then, has an inner layer of ectoderm, and an outer layer of mesoderm.

b. Return to the original section. The coelomic cavity is triangular in shape. At the most ventral point of the groove the somatic and splanchnic layers are nearly in contact, and this point marks the limit of the tissue which will form the body of the chick. This region of the mesoderm, ventral to the intermediate mesoderm, gives rise to the lining of the coelom and the smooth muscle around the viscera, and is known as the *hypomere*. The part of the somite dorsal to the intermediate mesoderm is the *epimere*, and from this part are derived most of the mesodermal structures of the body. Note that there is a clear differentiation of parts in the mesoderm.

c. Dorsal to the aortae, and immediately lateral to the notochord, is a loose collection of cells, the *sclerotome*, which collects around the notochord and forms the bony structures.

d. Lateral to the sclerotome, and next the ectoderm, is a heavy mass of cells extending dorsally almost to the nerve cord. This is the *dermatome* and gives rise to the subcutaneous tissue, and the dermis of the skin.

e. At its dorsal end the dermatome bends over upon itself, forming an ill-defined region, the *myotome*. Though relatively small at this stage, it soon outstrips the dermatome in size and eventually forms most of the skeletal muscle of the body.

f. Lateral to the aortae, at the ventral end of the dermatome, are the thin-walled postcardinal veins. These veins are prominent in the early embryo, but degenerate as the postcava develops and takes over their function.

g. Ventral and median to the cardinal veins are the thick-walled *Wolffian ducts*. Nearer the median line is a mass of nephric cells, which developed from the intermediate mesoderm, and form the *nephrotome* from which arises the kidney. The tissue may be pierced by a small lumen, a *mesonephric tubule*.

B. General Discussion

1. Gross Anatomy.

a. A muscle is considered as a group of muscle fibers, definitely set apart by connective tissue. The sheath enclosing the entire muscle is the *epimysium*, which sends strands of loosely arranged connective tissue into the muscle, dividing it into bundles or *fascicles*. Each fascicle is surrounded by an envelope, or *perimysium*. From the latter pass delicate strands enveloping each fiber as an *endomysium*. This last can be seen only with magnification.

b. Each muscle has an *origin* and an *insertion*. The origin is the attached end which anchors the muscle to a bone, or connective tissue *fascia* of another muscle. The other end of the muscle, which is attached to the part which is to be moved, is called the insertion. The free part lying between is the *belly*. Origins and insertions at times are difficult to determine, particularly in the body region, where the muscle simply pulls two parts toward each other; but the terms serve a useful function.

c. Muscles are always attached by *tendons* or by fasciae, never by free fibers. When the tendon is broad and flat it is called an *aponeurosis*. The fascia is a fibrous membrane in close connection with the skeleton, tendons or muscles. A muscle may have several points of origin, or *heads*, with a single insertion; or, an inserting tendon may divide into several parts.

2. Action of Muscles. The action of the muscle may vary with the position of the part to be moved, therefore a single term will rarely describe the full action of a muscle or a group of muscles. However, for simplicity, several descriptive words are in use in the science of myology.

a. A *levator* is a muscle that raises a structure, or a part; as the muscles which close the mouth are levators of the lower jaw.

b. *Depressors* are muscles antagonistic to the former; as those muscles which open the mouth.

c. *Adduction* is drawing a limb toward the mid-ventral line; or a digit toward the median line of the arm.

d. *Abduction* is drawing a limb (or digit as before) away from the mid-ventral line of the body. Thus, if the arms are held

extended at the sides, carrying them to the front is adduction; but further extension from the original position toward the mid-dorsal line would be abduction, even though they are brought toward the medial plane.

e. *Flexion*, or bending, is a movement in which the formation of an angle between two parts of the body is an essential feature. As it is possible to perform this movement in relation to two axes, viz., a transverse and antero-posterior axis, it is necessary to introduce qualifying terms: as ventral, anterior, or palmer flexion.

f. *Extension* consists of obliterating an angle formed by flexion. If the hand be bent backward this would be dorsal-flexion, though the muscles performing the movement are extensors of the wrist. Therefore an extensor or flexor muscle is named for its more important function.

g. *Rotation* is movement about an axis which is longitudinal. The head rotates on its axis. Other joints have this as one of numerous movements.

h. *Circumduction* is typical of ball and socket joints, and consists of combining extension, abduction, etc., into a movement whereby the free end of the appendage describes a circle.

3. Homology of Parts. The thoracic and pelvic limbs will be considered equivalent, part for part, in both skeletal and muscular systems. In the same way, the parts of the homologous limbs of different vertebrates will be considered similar, though the position of the parts may differ. For the sake of clarity, both the anterior and posterior limbs may be thought of as being completely in the transverse plane of the body, the humeri and femora being at right angles to the antero-posterior axis. The forearm and shank are then bent and brought into the dorso-ventral plane of the body, the hand and foot making the second angle, and continuing laterally in the transverse plane, parallel to the humerus and femur. This neutral limb was flexed backward toward the body in the pectoral, and forward in the pelvic limb, bringing the tetrapod legs into their typical position. The elbow forms a posterior, the knee an anterior, angle. A consideration of the limb positions of man, the cat, the alligator and Necturus will make this hypothetical, neutral type clear. The logical step

below Necturus would have the limbs at right angles to the long axis of the body, with no antero-posterior flexion.

4. Nomenclature of Muscles. The homology of muscles in different groups is more or less uncertain, though recent work has put comparative myology on a firmer basis. Homologies are based on origin, insertion, innervation, and embryology. The last two are most important.

Naming muscles is another difficulty. The scientific method is to name the muscle by its origin and insertion, and in this way make the name give the location and function. In man the muscles have been mostly named by their shape or appearance, and the same description rarely applies to the muscle in any other animal. As the names in human anatomy are well established in the language, and multiplying names often destroys the comparative idea, the authors have followed the expedient though unscientific method, and used the human nomenclature wherever possible.

5. Dissection of Muscles. Only the muscles of the *left* side of the body are to be dissected. The specimens are to be used in the study of other systems, and the right side must be left intact for this purpose.

Dissection does not mean the removal, but the laying bare of structures. No muscle is to be cut unless specific directions are given to that effect; and unless otherwise stated, the incision should be made through the middle of the muscle, so that both ends are preserved. When several muscles in the same region have to be cut, the incisions should be made at different angles, or at different levels. In this way there will be no difficulty in mating the ends of the same muscle.

A knife is rarely necessary in muscle dissection, a pair of forceps and the fingers being the most efficient instruments. When it is necessary to cut a muscle, use scissors.

C. Superficial Description

1. Primitive Groups.

a. The skeletal muscles are derived from both epimere and hypomere. Those arising from the latter (hypomere) are known as *branchiomeric* muscles, and are limited to the primitive gills. When the jaws became modified from the gill

arches, the branchiomeric muscles migrated with them, and became the muscles of the jaw and throat.

b. Most of the skeletal muscles arise from the *epimere*. In their simple condition they are regular myomeres, separated by myosepta.

c. The body muscles are divided by a horizontal, longitudinal septum at the level of the transverse processes of the vertebrae, forming the dorsal *epaxial* group, and the ventral *hypaxial* group.

d. The muscles of the appendages arise from both epaxial and hypaxial bundles.

2. Necturus.

a. The trunk and tail muscles preserve the primitive myomeric condition. Observe that the septum between epaxial and hypaxial groups meets the external wall at the lateral line.

b. Observe the direction of the muscle fibers in the epaxial group.

c. What is the direction in the hypaxial muscles? Notice that along the mid-ventral line there is a white band of connective tissue, the *linea alba*, where the muscles of either side meet.

d. On either side of the linea alba in the posterior part of the animal, observe that the hypaxial fibers have assumed an antero-posterior direction. These fibers form the *rectus abdominis*, which can be distinctly seen near the pelvic girdle. The large portion which inserts on the pubic bone will be dissected later.

e. Notice the muscles passing from the body to the pelvic limb. These muscles are poorly developed, but will be dissected later.

f. In the region of the pectoral girdle will be seen the well-defined shoulder muscles. These arise on the dorsal myomeres and insert on the scapula and humerus. The *pectoralis* is ventral, the largest of the anterior girdle. It arises as a broad sheet along the mid-ventral line, and inserts on the limb. The other shoulder muscles need not be identified.

g. On top of the head are the two pairs of large jaw muscles, the median *temporalis*, and the larger *masseters* lateral to them. Recall the fenestration of the amphibian skull. Would these muscles show so prominently on the alligator or turtle head?

h. On the ventral side, between the jaws is another large branchiomeric muscle, the *mylohyoid*. This is connected with the lateral muscles which pass on to the gills.

3. Alligator.

a. The myomeres are not so distinct as in Necturus, though in the tail region they are quite apparent. Locate the horizontal septum between the epaxial and hypaxial groups.

b. The more dorsal epaxial fibers are longer, stretching over several segments. What changes have occurred in the myosepta? What functional value does this have? Catch one of the small tendons and pull the muscle fibers out to observe their attachments.

c. The hypaxial fibers have the same ventro-caudal direction, forming the outer body layer of muscles. On the ventral side the longitudinal fibers have become a huge bundle, the *rectus abdominis*. The *linea alba* is partly hidden by this muscle.

d. The muscles to the pelvic limb appear to arise more directly on the limb than in Necturus.

e. Identify the well developed *trapezius*, arising on the neck and ribs, and inserting on the scapula. Observe its size, which is correlated with a greater use of the legs. The *pectoralis* is a heavy muscle, partly obscured by the neck muscles. Notice its distribution over the ventral ribs.

f. Due to the small fenestrae, the head muscles are difficult to dissect. The origin and part of the insertion of the temporal muscle can be seen by cutting the skin away on the side of the jaw, and top of the head just posterior to the eye. What opening of the skull is in this region?

g. The *mylohyoid* is well developed, and passing backward from the jaw to the skull is the huge *pterygoid* muscle.

4. Mammal.

a. The metameric structure of the muscles is lost in the adult placental, though present in the embryo.

b. The epaxial muscles are large and powerful, the fibers running almost longitudinally. Cut through the heavy fascia to expose the dorsal muscles, and notice that near the vertebral column the fibers are longer and more nearly longitudinal, carrying the condition found in Alligator a step further. The lengthening of the fibers adds strength and flexibility to the

body. Recall the swimming habit of Squalus and Necturus and compare the running habit of the rabbit or cat. Would jumping be possible with simple muscles of the Necturus type?

c. The hypaxial muscles are thin, but the direction of the fibers can be easily determined. They are more longitudinal but similar in direction to those of Necturus. The *rectus abdominis* can be identified as a thin sheet stretching from the pelvic girdle to the ribs, with the *linea alba* lying along the mid-line from the pelvic girdle to the ribs.

d. Without identifying the pelvic muscles, notice how they attach to the pelvic girdle.

e. The *trapezius* arises along the mid-dorsal line from the head to the end of the ribs, being divided into two portions: (1) The *anterior trapezius* arises from the neck ligaments, and converges to a point where it inserts on the metacromion process of the scapula; and (2) the *posterior trapezius* arises along the lumbo-dorsal fascia from a point dorsal to the scapula to the end of the ribs. It narrows toward the scapula, where it inserts in the dorsal half of the spine. (The fibers passing in a more ventral direction, but arising near the trapezius belong to the latissimus dorsi which will be described later.)

f. The *pectoralis* muscle is divided into several portions, two of which should be located at this time. The *pectoralis major* arises from the entire sternum, the fibers converging as the muscle passes away from the mid-line to its insertion on the humerus. It inserts on the antero-median border, for two-thirds the length of the humerus. Arising on the manubrium of the sternum, immediately anterior to the p. major, is the *pectoralis primus*. Its fibers are almost parallel, inserting in a fairly wide fascia on the humerus just anterior to the major portion. Near the insertion the two muscles are easily separated, the fibers running together near the origin.

g. The *masseter* is the large muscle on the side of the face, passing from the zygomatic arch to the jaw.

D. Muscles of the Head

1. Dissection of muscles must be made in a topographic manner, the embryological origin, however, being variable. Most of the muscles of the head are branchiomeric (from the hypomere). The

eye muscles are exceptions, arising from primitive metameric groups from the epimere. Several muscles of the neck and girdle are mentioned for ease of identification.

2. Necturus.

a. The *mylohyoid,* on the ventral part of the neck has been located. It extends from the symphysis of the jaws to the level of the gills. The origin is on the rami of the jaws and the muscles of the gills; the insertion is along the mid-line of the throat in a connective tissue partition, the *raphe.* Slit the raphe to its anterior limit, and turn back the left half of the muscle.

b. The *geniohyoids* are slim muscles on either side of the midline, arising on the symphysis, and inserting in a fascia posteriorly.

c. Arising about the middle of the geniohyoid, and curving around the angle of the jaws to insert on the gill supports, is the *external ceratohyoid.* This muscle pulls the gills forward, and its size is correlated with the constant motion of these organs.

d. Lift the ventral part of the external ceratohyoid. This exposes two small muscles. The *internal ceratohyoid* is the more anterior, arising with the external portion, and inserting on the first gill arch. Arising on the arch just posterior to the insertion of the former muscle is the *constrictor branchiarum* which inserts on the other gill arches. This muscle closes the openings of the gills slits.

e. Above the external ceratohyoid, and inserting on the dorsal part of the gill arches, is the fan-shaped *levator branchiarum.* The origin is on a fascia of the metameric muscles of the neck.

f. The median *temporal,* and the *masseter* have been located. Both insert on the lower jaw. Separate the masseter from the external ceratohyoid and the more dorsal temporal. Observe its origin along the curved squamosal and the dorsal parietal. Cut through the belly, pull the masseter outward, and locate the tendinous insertions of both the temporal and masseter, just posterior to the eye.

g. Pull the dorsal half of the masseter back and loosen the external ceratohyoid. Lying parallel to the latter is the *digastric* which arises on the posterior part of the skull and the ventral

side of the squamosal. It inserts on the lower jaw. It functions as a depressor of the jaw.

h. The *levator arcuum* is a gill muscle arising on the posterior part of the skull near the digastric. It passes laterally to an insertion near that of the levator branchiarum. It is found by lifting the external ceratohyoid.

3. Alligator.

a. On the *ventral* side of the jaw is the *mylohyoid.* The fibers run from one ramus of the jaw to the other, and in the posterior part the muscle is divided by a raphe. At its posterior end the muscle partly covers the muscle at the angle of the jaw.

b. Raise the mylohyoid at its posterior end, and uncover the transverse muscle which inserts under the jaw muscle observed previously. This is the *sphincter colli.*

c. Carefully slit the mylohyoid. Arising at the symphysis of the jaw, and passing backward to the lateral sides of the hyoid are the flat, elongated *geniohyoids.* Each is composed of plates of tissue which interlace with those of the other side.

d. There are three muscles of the jaw in the alligator, the masseter having been lost. The largest chewing muscle is the prominent *pterygoid,* which forms the large bundle at the posterior angle of the jaw. It arises from the pterygoid process and the fossa, and inserts on the angle of the jaw. It is an elevator of the jaw.

e. The *digastric* is the depressor of the jaw. Locate the posterior process of the mandible, where the pterygoid inserts. Inserting on the dorsal margin of the process is the large digastric, which passes dorsally and anteriorly to its origin on the posterior part of the skull.

f. The skin of the dorsal fenestra and the external mandibular foramen has been removed. This exposes part of the origin and insertion of the *temporal* muscle. Observe that this muscle lies mediad to the zygomatic arch.

4. Rabbit.

a. The most superficial muscles of the mammal throat and face are branchiomeric, and are derived from the superficial part of the sphincter colli of reptiles. On the neck and between the jaws of the rabbit is the very thin muscular sheet, the *platysma.* Connected with it are several facial muscles.

b. The *depressor conchae*, the "ear depressor", is a part of the platysma. Its origin is along the lateral border of the mandible, immediately in front of the masseter, and it inserts at the base of the ear.

c. The *inferior labial* depresses the lower lip. It covers the anterior third of the jaw, meeting its mate at the mid-ventral line, and inserts on the lower lip.

d. The *superior labial* raises the upper lip. Its origin is in the maxillary fossa, and it passes to the upper lip for its insertion. Branches pass to the nose. Observe the "hare lip" and how the contraction of the labial muscle opens the cut between the sides of the lip. The hare lip is an abnormality when found in most mammals. What is the function of a cleft lip in rodents?

e. The *mylohyoid* is deeper in the rabbit than in Necturus or Alligator. Cut the platysma, exercising care not to cut any blood vessels in displacing the glands. The fibers are in the typical transverse position, inserting on a raphe, and arising from the median sides of the mandible. Its function is to raise the floor of the mouth.

f. Cut the mylohyoid. The small, unpaired *geniohyoid* lies beneath it, the fibers running longitudinally. The origin is on the symphysis of the jaw, and the insertion on the hyoid bone. It assists in drawing the hyoid forward.

g. The jaw muscles are complete in the rabbit. At the symphysis of the lower jaws locate the *digastric* muscle which lies on the inner side of the mandible, ventral to the mylohyoid. It passes around the angle of the jaw as a thin tendon to its origin on the occipital bone. It is a depressor of the jaw. Probably only the posterior part is homologous with the digastric of lower forms.

h. On the lateral side of the posterior half of the jaw is the powerful *masseter* which has its origin on the zygomatic arch. The insertion is along the side and the ventral border of the jaw.

i. On the median face of the jaw, inserting just dorsal to the masseter, is the *pterygoid*. Pull the digastric medially, and follow the pterygoid muscle toward its origin on the pterygoid process and fossa.

j. The *temporal* muscle can be located immediately anterior to the ear, dorsal to the masseter. It is a small muscle arising in

the reduced temporal fossa. It passes medially to the zygomatic arch to insert on the ascending ramus of the lower jaw. Observe the skull of a cat (Carnivore) and notice the wide temporal fossa with the well developed temporal crest. The temporal exerts a direct pull on the jaw, and is typically the cutting muscle. The masseter, being attached to the zygomatic arch, tends to give a lateral motion to the jaw, and is therefore well developed in animals with a gnawing or grinding dentition

k. The smaller face muscles need not be dissected.

5. Cat.

a. The *platysma* is the most superficial muscle of the cat, lying in a subcutaneous position. Connected with it are several of the face muscles. If it was not stripped off in removing the skin it will be found stretching as a very thin sheet from the ventral side of the neck to the dorsal part of the neck and head.

b. The *depressor conchae*, pulling the ear downward, is one of three small muscles on the side of the face. It arises from the ventral side of the neck and overlies the platysma as a thin group of fibers. The zygomatic and submentalis lie anterior to it, inserting on the ear.

c. The *inferior labial* is a depressor of the lower lip. It arises along the anterior edge of the mandible and inserts on the lower lip. Occasionally a few fibers meet along the ventral line between the mandibles.

d. The *superior labial* raises the upper lip. Its origin is along the maxillary bone, and it passes to the upper lip and nose for its insertion. In the cat the two parts are easily separable.

e. The *mylohyoid* is partly obscured, but can be located superficially as a group of transverse fibers stretching between the mandibles. Do not destroy the glands and blood vessels in clearing the muscle. The insertion is on a raphe in the midventral line, and the function is to raise the floor of the mouth.

f. Cut the mylohyoid. The small *geniohyoids* lie beneath it, the fibers running longitudinally. The two halves lie close together. The origin is on the symphysis of the jaw, and the insertion is on the hyoid bone. It assists in drawing the hyoid forward.

g. Along the median ventral border of the jaws locate the *digastric* muscles, lying ventral to the mylohyoid. The insertion is on the mandible, beginning at the symphysis. The muscle passes around the angle of the jaw to its origin on the occipital bone. At the angle of the jaw the muscle is almost divided transversely. It functions as a depressor of the jaw.

h. On the lateral side of the posterior half of the jaw is the *masseter*, which has its origin on the zygomatic arch. The insertion is along the side and ventral border of the jaw.

i. On the median side of the jaw, inserting just dorsal to the masseter, is the *pterygoid*. Pull the digastric medially, and follow the pterygoid muscle toward its origin on the pterygoid process and fossa.

j. The *temporal* muscle can be located immediately anterior to the ear, dorsal to the masseter. In the cat it is a powerful muscle arising along the temporal and parietal bones. It passes mediad to the masseter and zygomatic arch, to insert on the ascending ramus of the lower jaw. The student should compare the description of the rabbit (Par. 3, Section "j").

k. The smaller face muscles need not be dissected.

E. Muscles of the Neck and Shoulder

1. Necturus.

a. Arising along the dorsal muscles and converging toward the articulation of the forearm with the girdle, three muscles can be identified. The most anterior arises by two slips from the dorsal side of the neck, immediately posterior to the branchial arches. This is the *trapezius*, which inserts on the anterior border of the scapula.

b. Next in order posteriorly is the *deltoid* which arises on the lateral side of the scapula and inserts on the humerus.

c. Posterior to the deltoid is the *latissimus dorsi*, the largest of the three, which arises by several slips from different myotomes. The fibers converge to insert on the humerus, internal to the deltoid.

d. Cut the latissimus dorsi and gently raise the scapula. Inserting on the dorsal border of the scapula are several very small slips, the rudimentary *serratus anterior*. These slips arise from two or three myotomes, posterior and ventral to the scapula.

e. Lift the trapezius and expose the small longitudinal muscle inserting on the dorsal anterior part of the scapula, the *levator scapulae* which arises on the cervical vertebrae, with a thin tendinous attachment to the skull.

f. On the *ventral* side of the neck is the large flat *sternohyoid.* Lift the geniohyoids and locate the insertion of the sternohyoid on the visceral apparatus, which is homologous with the hyoid of the mammal. The origin is in the body musculature of the sternal region, and is directly continuous with the ventral myotomes.

g. Inserting on the humerus are three prominent muscles. The most posterior is the large, thin, fan-shaped *pectoralis*, inserting on the ventral border of the humerus.

h. Partly covered by the anterior border of the pectoralis is the *supracoracoid*, which completely covers the coracoid cartilage.

i. Inserting between the supracoracoid and the deltoid is the *precoraco-humeralis*, a narrow longitudinal band lying along the precoracoid cartilage. The cartilage extends almost to the external ceratohyoid.

j. Dorsal to, and paralleling the precoraco-humeralis, is the small slip-like *omohyoid.* This arises in the fascia of the sternohyoid, and inserts on the anterior border of the scapula just ventral to the trapezius.

2. Alligator.

a. On the *ventral* side of the neck are the *sternohyoid* muscles. The sternohyoid is a long muscle lying along the trachea (windpipe). It arises on the episternum and passes forward to the hyoid cartilage. The muscle is easily separable into two portions. The median part inserts on the horn of the hyoid, beneath the posterior end of the geniohyoid. The more lateral part inserts into a tendon ventral to the geniohyoid.

b. Parallel with the posterior part of the geniohyoid are two muscles, with the mylohyoid inserting between them. The median one, next the geniohyoid, is the *internal mandibulo-hyoid.* It arises from the inner side of the jaw, and inserts on the hyoid with the sternohyoid.

c. The lateral *external mandibulo-hyoid* arises on the ventral margin of the jaw immediately anterior to the pterygoid

muscle. It passes posteriorly and slightly dorsally to insert on the horn of the hyoid.

d. Carefully raise the sternohyoid, and locate dorsal and lateral to it the long thin *omohyoid*, which lies along the esophagus, a tough-walled white tube. The muscle arises from the coracoid near its junction with the scapula, and inserts on the horn of the hyoid with other hyoid muscles.

e. The *sternomastoid* lies lateral to the sternohyoid, arising near the latter on the coracoid. Near the posterior margin of the pterygoid it has an attachment to the cervical ribs. From this point the anterior part of the muscle turns dorsally under the pterygoid to insert on the posterior part of the skull.

f. Carefully lift the esophagus, without breaking any large blood vessels. Lying against the cervical vertebrae are two long masses of muscles. The slim, median group is the *longus colli* muscle. The larger mass is the *scalenus*.

g. On the side of the neck is a flat muscle, the *latus colli*. It arises on a dorsal fascia, and inserts both on the mylohyoid and on a fascia which passes to the vertebrae dorsal to the sternomastoid. Cut this muscle without injuring the anterior part of the trapezius which lies beneath it.

h. Just dorsal to the sternomastoid is the *levator scapulae*, a fan-shaped muscle arising on the cervical vertebrae where the sternomastoid attaches. From its anterior origin it passes backward, spreading out to insert on the entire anterior border of the scapula. Its insertion is covered by the trapezius.

i. The *trapezius* arises in an aponeurosis on the dorsal mid-line of the hind part of the neck, and the craniad part of the thorax. It inserts on the ventral border of the scapula, and partly into the fascia of the shoulder. Cut the trapezius and lay it back. This will expose the insertion of the levator scapulae.

j. On the *dorsal* side of the neck, on either side of the mid-line, lie the powerful *semispinalis capitis* muscles. The origin is on the dorsal processes of the anterior thoracic and posterior cervical vertebrae. The insertion is on the dorsal and lateral occipital region of the skull.

k. Separate the fascia of the semispinalis and slightly raise it. Ventral and lateral to it is the *internal semispinalis capitis*, a muscle of almost the same size. It arises on the vertebral

processes and inserts on the squamosal, lateral to the semispinalis capitis. Lift this muscle to expose those more ventrally placed.

l. Near the insertion of the semispinales muscles is a round muscle inserting ventral and lateral to them. This is the *longissimus capitis*. About halfway the neck it passes into another muscle, which hides its origin on the last three cervical vertebrae.

m. The *splenius cervicis* is divided into two parts by the longissimus capitis. At the posterior part of the neck the splenius lies next the semispinales muscles. This muscle is attached by tendons to the cervical vertebrae.

n. Lying ventral to the longissimus capitis is a deep, large muscle, the *splenius capitis*. Lift the longissimus capitis, and the splenius capitis will be seen lying parallel to the anterior part of the sternomastoid muscle.

o. On the lateral surface of the scapula are three superficial muscles. The largest and most posterior is the *latissimus dorsi*, a thin sheet arising on the mid-dorsal line and on the thoracic ribs. The muscle converges ventrally to insert by a strong tendon on the humerus. Cut through the belly of the muscle.

p. On the posterior half of the scapula is the *teres major*, which was partly covered by the latissimus dorsi. Its origin is on the upper half of the scapula, and its insertion is near the latissimus dorsi on the humerus.

q. The anterior half of the scapula is covered by the *deltoid*. Its origin is on the dorsal and anterior margins of the scapula, and its strong tendon inserts on the anterior border of the humerus.

r. Dorsal to the deltoid, passing from the scapula to the neck, is the *rhomboideus*. It has its origin in a heavy fascia attached to the splenius muscles, and is inserted on the dorsal median portion of the scapula. It draws the scapula forward and upward.

s. Pull the dorsal border of the scapula outward. Arising by numerous prongs from the ribs is the *serratus anterior* which inserts on the dorsal and axillary borders of the scapula. The posterior head is the largest, inserting on the entire axillary border. The other heads are much smaller.

t. The *teres minor* is a small muscle found on the lower third of the axillary border of the scapula, hidden by the teres major, and inserting on the humerus.

u. On the *ventral* side of the thorax is the *pectoralis* muscle, the largest muscle of the pectoral girdle. It arises from the entire episternum and sternum. The fibers converge to insert on the ventral part of the humerus.

v. The *supracoracoideus* covers the anterior part of the shoulder just anterior to the pectoralis. It is a rather short triangular muscle, arising on the scapula and coracoid. It inserts on the humerus anterior and distal to the pectoralis.

3. Rabbit.

a. On the *ventral* side of the neck are the *sternohyoids*, passing backward from the hyoid. They fuse at the larynx, and continue caudad, in the median ventral line, to their origin on the manubrium of the sternum. They draw the hyoid backward, and like the other hyoid muscles, function during chewing and swallowing (and speech in man).

b. Divide the sternohyoid and locate the larynx, covered by the thyroid cartilage from the 4th and 5th visceral arches (2nd and 3rd branchial). The trachea (windpipe), supported by rings of cartilage, extends from the larynx to the lungs. On either side of the trachea, slightly posterior to the thyroid cartilage, is the dark-colored, bilobed, thyroid gland.

c. Lift the sternohyoid muscle. Dorsal to it, paralleling the trachea, is the *sternothyroid.* It has its origin on the sternum, and its insertion on the thyroid cartilage.

d. The *thyrohyoid* muscle originates on the side of the thyroid cartilage, and is almost continuous with the preceding muscle. It passes forward to the hyoid where it inserts.

e. Lateral to the sternohyoid is the *sternomastoid,* with an origin on the manubrium ventral to the former. From a single origin, the paired muscle diverges laterally and dorsally to insert on the mastoid processes of the skull.

f. Lateral and dorsal to the preceding is the *cleidomastoid.* It has its insertion on the mastoid process just dorsal to the sternomastoid, and can be traced back to its origin on the clavicle.

g. The *basioclavicularis* arises on the clavicle, lateral to the cleidomastoid. From its origin it passes forward, crossing dorsal to the mastoid muscle, to its point of insertion on the basioccipital. It, with the preceding two muscles, functions to draw the head ventro-laterally when functioning singly; or ventrally when contracting synchronously.

h. In order to find the following muscles the *anterior trapezius* must be cleared of its connective tissue and fat. It arises on the ligament of the head and the cervical vertebrae, and inserts on the metacromion of the spine of the scapula.

i. As the trapezius is raised the slim *ventral levator scapulae* will be uncovered. Its origin is on the ventral part of the skull at the union of the basioccipital and basisphenoid. For one-third its length it parallels the basioclavicularis, then unites with the anterior trapezius and inserts with it on the metacromion.

j. Cut the anterior trapezius about the middle and lay back both ends, clearing away the remaining fat and connective tissue. Near the neck will be a thin fascia. Clear the muscle fibers, which should be preserved, and remove this fascia.

k. The *dorsal levator scapulae* is the long slender muscle stretching from the scapula to the occiput. Its origin is on the occiput just behind the ear, and it passes to its insertion on the medial side of the scapula, about the middle of the vertebral border.

l. From the skull, extending caudad on the dorso-lateral part of the neck, is the broad *splenius* muscle. It is a thin sheet originating on the neck ligament and side of the neck, and inserting on the supraoccipital and mastoid portions of the skull. Carefully raise this muscle and remove it.

m. Beneath the preceding is a heavy band of muscles, continuous with the longitudinal muscles of the body region. Separate the ventral and lateral part, the *longissimus capitis*, which arises from the second to fourth thoracic vertebrae, and inserts under the splenius on the mastoid portion of the skull.

n. The narrow band dorsal to the longissimus capitis is the *semispinalis capitis*. It arises from the transverse processes of the posterior five cervical and four thoracic vertebrae, and inserts on the lateral occipital bone. Its origin cannot be

traced until the shoulder muscles are dissected out. The small occipital muscles need not be dissected.

o. On the *dorsal* side of the scapula identify the *posterior trapezius*. The anterior part of this muscle has been cut for the dissection of the neck. The posterior portion is a thin sheet arising on the fascia of the thoracic vertebrae, and inserting on the dorsal half of the spine of the scapula. Dorsally its fibers interlace with the more posterior muscle.

p. The *latissimus dorsi* lies posterior to the preceding. It arises on the dorsal thoracic fascia and laterally along the posterior ribs. Its fibers converge toward the scapula and pass under the arm to insert on the medial side of the deltoid ridge.

q. Cut the posterior trapezius and the latissimus dorsi at the level of the vertebral border of the scapula. The *thoracic* part of the *serratus anterior* is prominent, passing ventrocaudally in seven bands from its attachment on the medial dorsal part of the scapula. It originates on the thoracic ribs. Separate the muscles at the cranial border of the scapula and lift it, without tearing the attached muscles. The *cervical* portion of the anterior serratus will be seen extending cranioventrally in five strips from its insertion on the dorsal medial surface of the scapula to the first two ribs and the cervical vertebrae. With the loss of the coracoids, most of the weight of the anterior part of the body is carried by the serratus.

r. The *teres major* is a long muscle stretching the entire length of the axillary border of the scapula. It connects with the serratus dorsally and inserts with the latissimus dorsi. It is the most posterior muscle of the scapular border. The *teres minor* is a small muscle arising on the ventral part of the axillary border, and inserting on the greater tuberosity of the humerus. It is difficult to separate without destroying the other muscles of the scapula.

s. The *rhomboideus* inserts on the vertebral border of the scapula, dorsal to the serratus. Its origin is on the cervical and thoracic ribs. It is a broad band, the origin being wider than the insertion.

t. The *deltoid* muscle of the rabbit is in three parts. Fold back the posterior trapezius to its point of insertion on the spine of the scapula.

(1) Where the trapezius covered the infraspinous region, there is a shiny fascia. Along the ventral line of this fascia, stretching from the spine to the axillary border, will be found the *scapular* portion of the deltoid. The muscle continues under the metacromion process to insert on the deltoid ridge of the humerus.

(2) The *acromial* head of the deltoid is smaller, covering the lateral surface of the humerus. It has an origin on the acromion process, and passes over the insertion of the scapular head, to insert on the deltoid ridge distal to the former.

(3) The *clavodeltoid* is the most anterior part of the deltoid muscle, lying on the anterior border of the humerus. It arises from the fascia over the clavicle, and inserts near the distal end of the humerus.

u. The *infraspinatus* muscle lies in the infraspinatus fossa, under the scapular portion of the deltoid. It passes downward to insert on the greater tuberosity of the humerus.

v. Filling the supraspinatus fossa is the *supraspinatus* muscle. It is covered by a part of the pectoralis which can be lifted along its posterior border near the spine of the scapula to expose the former. The supraspinatus inserts on the greater tuberosity immediately anterior to the infraspinatus.

w. Raise the scapula and with the finger clear away the connective tissue. The large *subscapularis* completely fills the subscapular fossa. It is inserted on the lesser tuberosity of the humerus, and draws the humerus toward the median line.

x. The *scalenus group* of muscles arises along the transverse processes of the cervical vertebrae and insert on the anterior ribs. Lift the cervical portion of the serratus and locate the long slips of the scaleni passing dorso-caudally.

y. The ventral *pectoralis* muscles of the rabbit can be divided into five parts, three of which will be dissected.

(1) The *pectoralis major* originates from the entire sternum and inserts on the antero-medial border of the humerus for two-thirds its length.

(2) The *pectoralis primus* inserts on the humerus immediately anterior to the preceding. The origin is on the manubrium of the sternum, and it covers the anterior border of the major portion.

(3) The *pectoralis minor* has been identified where it inserts on the spine of the scapula, overlying the supraspinatus muscle. A few fibers also insert on the clavicle. It can be traced from its point of insertion to its origin on the manubrium and sternum. Its origin is covered by the pectoralis major.

4. Cat.

a. On the *ventral* side of the neck are the *sternohyoids,* passing backward from the hyoid. The two halves lie closely opposed from the larynx to the sternum, covering the ventral side of the trachea (windpipe). At their posterior end they pass under more superficial muscles which can be lifted. They draw the hyoid backward, and like the other hyoid muscles, function during chewing and swallowing.

b. Separate the sternohyoids and locate the larynx, covered by the thyroid cartilages which arise embryologically from the 4th and 5th visceral cartilages. The trachea, supported by rings of cartilage, extends from the larynx to the lungs. On either side of the trachea, slightly dorsal and posterior to the thyroid cartilage is the bilobed thyroid gland.

c. Lift the sternohyoid muscle. Dorsal to it, paralleling the trachea, is the *sternothyroid.* It has its origin on the sternum and its insertion on the thyroid cartilage.

d. The *thyrohyoid* muscle originates on the side of the thyroid cartilage, and is almost continuous with the preceding muscle. It passes forward to the hyoid cartilage where it inserts.

e. Covering the posterior part of the sternohyoids are the *sternomastoid* muscles. Each consists of two parts, a deeper median portion, and the larger lateral head. The former arises on the dorsal side of the manubrium, the fibers interlacing nearly to the larynx. The lateral part arises on the ventral side of the manubrium and passes to its insertion parallel to the median part. The two portions unite near their insertion on the mastoid process and lambdoidal ridge.

f. Lateral and dorsal to the preceding is the *cleidomastoid.* It is wider than the preceding at its origin on the clavicle, and narrows as it approaches its insertion on the mastoid process under cover of the sternomastoid.

g. In order to find the following muscles the *anterior trapezius* (clavotrapezius) must be cleared of its connective tissue and cut. It arises along the ligament of the head and neck, the fibers passing caudo-ventrally to its insertion on the clavicle lateral to the cleidomastoid.

h. As the trapezius is laid back the slim *ventral levator scapulae* (about the size of the cleidomastoid) will be uncovered. Its origin is on the atlas and basioccipital bones and it inserts on the metacromion.

i. The *dorsal levator scapulae* is a long slender muscle stretching from the occiput to the scapula. The origin is on the lambdoidal ridge just behind the ear, and it passes to its insertion on the medial side of the scapula about the middle of the vertebral border.

j. The broad *splenius* covers the dorsal and lateral parts of the neck. It is a thin sheet arising from the ligament of the entire cervical region and the fascia of the deeper muscles. It inserts on the occiput in a wide tendon. At its ventral edge, near the ventral levator scapulae, separate the muscle from the deeper ones and cut it near the head.

k. Beneath the splenius is a heavy band of muscles, continuous with the longitudinal muscles of the body region. Separate the ventral and lateral part, the *longissimus capitis*, which arises from the second to the fourth thoracic vertebrae and inserts under the splenius on the mastoid portion of the skull.

l. The narrow band dorsal to the longissimus capitis is the *semispinalis capitis*. It arises from the transverse processes of the last cervical and anterior thoracic vertebrae, and inserts on the occipital bone. Its origin cannot be traced until the shoulder muscles are dissected out.

m. The smaller occipital muscles need not be dissected. These form a complex near the head and are traced with difficulty.

n. On the *dorsal* side of the neck identify the *middle* and *posterior trapezius* muscles. From their insertions these are often called the acromio- and spinotrapezius. The middle portion arises on the spinous ligament in the thoracic region and passes ventrally to its insertion on the metacromion and spine of the scapula. The posterior part arises from the posterior thoracic vertebrae and passes cranio-ventrally to the dorsal part of the spine of the scapula.

o. The *latissimus dorsi* lies under and posterior to the posterior trapezius. It arises on the dorsal thoracic fascia and laterally along the posterior ribs. Its fibers converge toward the scapula and pass under the arm to insert on the medial side of the deltoid ridge.

p. Cut the trapezius and the latissimus dorsi at the level of the vertebral border of the scapula. The *thoracic* part of the *serratus anterior* is prominent, passing ventro-caudally in seven bands from its attachment on the medial dorsal part of the scapula. It originates on the thoracic ribs. Separate the muscles at the cranial border of the scapula and lift it, without tearing the attached muscles. The *cervical* portion of the anterior serratus will be seen extending cranio-ventrally in five closely attached strips from its insertion on the dorsal median surface of the scapula to the transverse processes of the cervical vertebrae. Correlate the size of the serratus with the loss of the coracoids, and the increasing weight thrown on the serrati.

q. The *teres major* is a long muscle stretching the entire length of the axillary border of the scapula. It connects with the serratus dorsally and inserts in a tendon with the latissimus dorsi. It is the most posterior muscle of the scapular border. The *teres minor* is a small muscle arising on the lower fifth of the axillary border of the scapula, lying under the teres major. It inserts on the greater tuberosity of the humerus. It is difficult to separate without destroying the other muscles of the scapula.

r. The *rhomboideus* inserts on the vertebral border of the scapula, dorsal to the serratus. Its origin is on the cervical and thoracic ribs. It is a broad band, the origin being wider than the insertion, and is the most dorsal muscle of the shoulder after the trapezius is cut.

s. The *deltoid* muscle is usually considered as being in three parts, corresponding to the three parts of the human muscle.

(1) The *scapular* part of the deltoid is the most posterior of the three. It arises on the spine of the scapula ventral to the insertion of the posterior trapezius. It passes laterally over the shoulder to insert on the middle part of the deltoid ridge of the humerus.

(2) The *acromial* head of the deltoid arises on the acromion and adjacent fasciae, near the insertion of the ventral levator scapulae. It passes over the insertion of the scapular portion to insert more distally on the deltoid ridge. A slip is given off which passes to the anterior part of the deltoid.

(3) The *clavodeltoid* (clavobrachialis of some anatomists) arises on the clavicle. It appears to be continuous with the anterior trapezius. It passes down the anterior-medial side of the arm to insert by a long tendon on the ulna. Its homology with the human deltoid is doubtful.

t. The *infraspinatus* muscle lies in the infraspinatus fossa, under the scapular portion of the deltoid and the posterior trapezius. It covers the entire posterior half of the scapula, and inserts on the greater tuberosity of the humerus.

u. Filling the supraspinatus fossa of the scapula is the *supraspinatus* muscle. It covers the anterior half of the scapula, inserting on the tuberosity of the humerus.

v. Raise the scapula and with the finger clear away the connective tissue. The large *subscapularis* completely fills the subscapular fossa. It is inserted on the lesser tuberosity of the humerus, and draws the humerus toward the median line. The muscle cannot be completely uncovered due to the other structures under the arm which should not be destroyed.

w. Lift the cervical portion of the serratus and locate the bands of fibers passing from the cervical vertebrae in a dorso-caudal direction. These are the *scalenus* muscles, inserting on the anterior ribs.

x. On the *ventral* side of the animal, arising on the sternum, is the *pectoralis* muscle. There are three distinct parts, and several minor divisions.

(1) *Pectoantibrachialis* is the most ventral slip of the pectoralis group. It arises on the ventral side of the manubrium, and passes to its insertion in a fascia attached to the dorsal border of the ulna. During its course it parallels the clavodeltoid.

(2) The *pectoralis major* is in two parts, a superficial and a deep portion. It arises from the manubrium and the first three divisions of the sternum, and the fascia overlying the deep part along the mid-ventral line. The

insertion is in two parts along the upper two-thirds of the humerus.

(3) The *pectoralis minor* lies deeper than the major portion. It arises from the ventral border of the posterior part of the sternum, the fibers passing cranio-laterally to their insertion on the upper half of the humerus. From the xiphisternum arises a part of the pectoralis minor, often described as a separate muscle. The degree of separation is quite variable in cats, and it is therefore included as a part of the pectoralis minor.

F. Muscles of the Anterior Limb

1. Necturus.

a. On the ventral side of the upper arm, lying along the humerus are two flexor muscles. The smaller, more lateral one is the *biceps*. It has its origin on the proximal end of the humerus, and inserts on the radius.

b. The *coracobrachialis* is the larger of these flexors, lying on the medial side of the humerus. It arises on the coracoid cartilage and inserts on the distal end of the humerus.

c. On the dorsal side of the humerus is the extensor muscle, the *triceps*. It arises by three heads from the coracoid, scapula and humerus. These fuse to form a relatively large muscle, inserting on the ulna.

d. The ventral flexor muscle of the forearm is the *flexor digitorum communis*.

e. On the preaxial border, lying along the radius, is the small *flexor carpi radialis*.

f. Cut the digitorum communis, and underneath will be found the *flexor carpi ulnaris*, on the ulnar border; and passing from the ulna to the radius and carpals is the *pronator* muscle.

g. On the extensor side of the forearm identify the *extensor digitorum communis*.

2. Alligator.

a. The *biceps* lies on the median side of the upper arm and arises by two heads. One arises from the coracoid by a long flat tendon; the more lateral part has its origin on the humerus. The two parts are easily separable for the upper two-

thirds, when the fibers run together. The insertion is on the radius and ulna by two tendons.

b. Lateral to the biceps is the *brachialis*, which arises on the head of the humerus, parallels the biceps for its entire length, and inserts on the radius.

c. Lift the pectoralis, and find the *coracobrachialis*, a flat strong muscle extending from the border of the coracoid to the humerus, where it inserts on the proximal half of the anterior border. The tendon of origin of the biceps passes along the line of insertion of this muscle.

d. The *triceps* arises by five heads and inserts into a broad flat tendon which spreads over the elbow, inserting on the ulna.

e. On the *extensor* side of the forearm are four superficial muscles. Beginning on the radial (preaxial) border, the first is the *brachioradialis*, arising on the humerus and inserting along the distal end of the radius. This is the most anterior muscle of the forearm.

f. The *extensor carpi radialis* (*longus*) partly covers the preceding at its distal end. It arises from the common tendon of the humerus, and inserts on the radial side of the carpus, sending branches to the radius.

g. In the center is the *extensor digitorum communis*, which arises on the common tendon of the humerus, and passes distally to spread over the hand as a thin ligament to its attachments on the digits.

h. Lying posterior to the preceding is the *extensor carpi ulnaris*, which originates with the preceding, and inserts along the inner side of the ulna, and on the carpus. This muscle is in two parts, which need not be separated.

i. Lift the extensor carpi radialis longus and expose the *extensor carpi radialis brevis*, a strong muscle covered by the superficial group. It arises on the common tendon of the humerus, and inserts on the median border of the radius.

j. The other deep extensor can be found by separating the muscles at the distal ends. The *supinator* arises along the median border of the ulna, and passes to the distal end of the radius.

k. On the *flexor* side identify again the brachioradialis, lying on the preaxial border. The powerful *flexor radialis* lies

next to it, passing from the humerus obliquely across the arm to its insertion on the carpus.

l. Arising with the preceding is a slim muscle, which separates from it and inserts on the digits by a very small tendon. This is the *flexor digitorum sublimis.*

m. On the postaxial border is the *flexor carpi ulnaris,* which has origin under the preceding two, and inserts into the carpus on the ulnar side.

n. Cut the flexor muscles at different levels and note the *flexor digitorum profundus,* a deep muscle lying between the radius and ulna. It arises from the humerus, radius and ulna, and inserts on the digits.

3. Rabbit.

a. The *biceps* lies on the median side of the flexor surface of the arm. The pectoralis covers its origin on the coracoid process of the scapula. It is a spindle-shaped muscle inserting on the radius and ulna.

b. The *brachialis* is next lateral to the biceps, the pectoralis inserting between them. It arises along the median and lateral surfaces of the humerus, the lateral portion being the larger. The insertion is with the biceps on the radius and ulna.

c. The *coracobrachialis* lies under the pectoralis minor. It is a small muscle arising on the coracoid process and inserting on the humerus under the proximal part of the biceps.

d. The *triceps* arises by three heads which are almost separate in the rabbit. Identify:

(1) The long head (caput longus), the largest and most posterior muscle of the upper arm. It arises from the axillary border of the scapula, and inserts on the olecranon.

(2) The lateral head arises from the greater tuberosity and lateral part of the humerus, and lies as a flat muscle lateral and anterior to the former.

(3) The median head arises on the posterior side of the humerus. It can be found by separating widely the long head and the biceps. The tendons of all three parts converge and insert together.

e. The *extensor antebrachii* is a small muscle arising from a

fascia on the long head of the triceps on its medial surface, and inserts on the medial surface of the olecranon.

f. A thorough dissection of the muscles of the forearm cannot be made in a short time. The primitive group has become very complex. On the *extensor* side, beginning anteriorly, identify and, if time permits, work out origins and insertions:
   (1) The *brachioradialis* lying most anteriorly on the radial side, arises on the humerus and inserts on the distal end of the radius.
   (2) The *extensor digitorum communis* arising from the common tendon of the humerus is next. The insertion may be found by skinning the hand and following the tendons to the digits.
   (3) Separate the two preceding and note the *extensor carpi radialis*. It is a slim muscle arising on the lateral epicondyle and inserting on the carpals. The muscle can be divided into two parts.
   (4) The *extensor digiti* is a slim muscle inserting on the 4th and 5th digits.
   (5) *Extensor carpi ulnaris* arises on the epicondyle and the upper part of the ulna, to insert on the carpals.

g. The flexor muscles are equally complex. The superficial ones, beginning at the radial border, next the brachioradialis, are:
   (1) The *pronator teres* arising on the humerus and inserting on the medial side of the radius.
   (2) The *flexor carpi radialis* is another small muscle arising from the humerus, and inserting by a long tendon into the carpus.
   (3) The *flexor digitorum profundus* is a larger muscle arising from the humerus, radius and ulna. The majority of the muscle lies deep. It inserts by several tendons into the digits.
   (4) Under cover of the superficial part of the profundus is the *flexor digitorum sublimis*, which sends its tendons into the palm. Its slim tendons lie outside those of the profundus. In man the entire muscle takes a superficial position.
   (5) The *flexor carpi ulnaris* lies most posteriorly on the arm. It arises on the olecranon and inserts on the carpals.

4. Cat.

a. The *biceps* lies on the median side of the flexor surface of the arm. The pectoralis covers its origin on the glenoid angle of the scapula. It is a spindle-shaped muscle inserting on the radius with a strong tendon.

b. The *brachialis* is lateral to the biceps, the pectoralis inserting between them. It arises along the lateral, proximal portion of the humerus. The insertion is on the ulna. Distally the muscle lies in contact with the biceps.

c. The *coracobrachialis* lies under the pectoralis major. It is a small muscle arising on the coracoid process and inserting on the humerus under the proximal part of the biceps.

d. The *triceps* arises by three heads, as in the human, which are easily separable. These parts are:

(1) The long head (caput longus), the largest and most posterior muscle of the upper arm. It arises from the axillary border of the scapula, and inserts on the olecranon.

(2) The lateral head arises from the greater tuberosity and lateral part of the humerus, and lies as a flat muscle lateral and anterior to the former.

(3) The median head arises on the posterior side of the humerus. It can be found by widely separating the long and lateral heads of the triceps. The tendons of all three parts converge and insert together on the olecranon.

e. The *extensor antebrachii* is a small muscle arising from the fascia of the latissimus dorsi, near the insertion of the latter. It lies medial to the long head of the triceps, and inserts with the pectoantebrachialis on the dorsal part of the olecranon.

f. As the primitive group of muscles in the forearm has become very complex, these muscles cannot be thoroughly dissected in a short time. Identify, and if time permits, work out origins and insertions of the following muscles.

g. On the *extensor* side, beginning anteriorly:

(1) The *brachioradialis*, lying most anteriorly on the radial side, was found in dissecting the upper arm. It is a very slender muscle arising about the middle of the humerus on the lateral side. It inserts on the distal end of the radius.

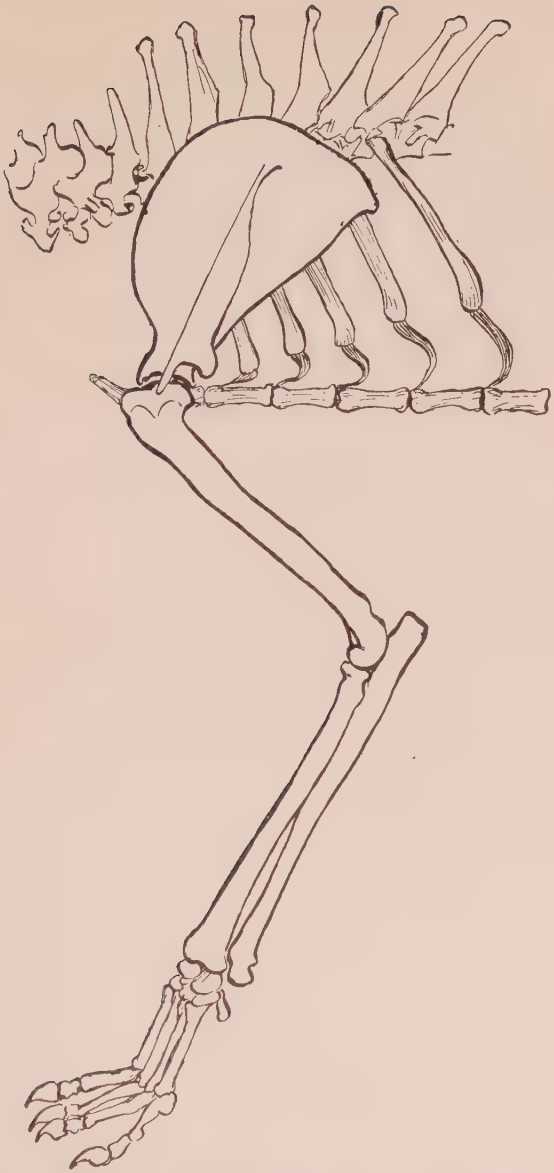

PLATE 18. Lateral view of the anterior girdle and limb of the cat. Fill in the deep muscles of the limb and shoulder, showing the exact attachments on the bones.

(2) The *extensor carpi radialis* is the first of adjacent muscles on the forearm. It arises broadly on the distal-lateral border of the humerus by two heads, the short head being completely covered by the long head. The two parts insert together on the radial carpals.

(3) The *extensor digitorum communis* lies about the middle of the extensor side of the forearm. It arises on the humerus from the common tendon, and inserts by several tendons on the digits. These may be seen by skinning the hand and lifting the tendon.

(4) The *extensor digiti* is a slim muscle, arising on the common tendon and inserting on the 4th and 5th digits.

(5) The *extensor carpi ulnaris* is the last of the extensor muscles. It arises on the external condyle of the humerus and inserts on the ulnar carpals.

h. On the flexor side of the arm identify, beginning at the radial border:

(1) The *pronator teres*, a short muscle, arising on the humerus and inserting on the medial side of the upper half of the radius.

(2) The *flexor carpi radialis* is a slim muscle arising from the humerus, and inserting by a long tendon into the carpus.

(3) The *palmaris longus* is a thin, fusiform muscle arising on the common tendon and inserting by several tendons into the digits.

(4) The two heads of the *flexor carpi ulnaris* lie on the ulnar border of the arm.

(5) Separate the muscles, and the large *flexor digitorum profundus* will be seen. It arises by five heads, passes across the wrist as a very heavy tendon, and inserts by several tendons into the digits.

G. Muscles of the Body

1. Necturus.

a. Identify again the epaxial and hypaxial groups, divided horizontally at the lateral line.

b. About an inch posterior to the limbs catch the epaxial muscles with the thumb nail and pull them dorsally. This

will expose the short ribs. Passing from one to the other note the *intercostal* muscles. Observe the difference in length and direction of the fibers.

c. On the body wall, just ventral to the horizontal septum, identify the *external oblique* muscles, and observe the direction of the fibers.

d. Cut through this outer layer and find the *internal oblique* muscle layer with its fibers directed in a ventro-cranial direction, opposite to the outer layer.

e. On cutting through this layer will be found the *transversus* muscle lying next the lining of the body cavity.

f. The *rectus abdominis* has been identified.

2. Alligator.

a. The metameric arrangement of the axial muscles can be traced in the alligator, though they are more completely covered than in Necturus. Metamerism is distinct in the caudal region.

b. Locate the horizontal septum and trace it backward. The epaxial muscles have become greatly modified. The myosepta have in great part degenerated, and the myomeres have elongated into flat muscles which are attached by rounded tendons to the neural arch and transverse processes. Loosen a tendon, and pull the muscle up to see its shape and method of attachment. The semispinales and scalenus groups are a modified continuation of these muscles.

c. Make a small incision in the epaxial muscles over the thoracic ribs and raise the tissue. Lying between the ribs are the *intercostal* muscles.

d. The *rectus abdominis* has been identified on the ventral part of the body, attaching strongly to the pubis. A deeper portion passes from the pubis and extends between the oblique muscles of the body.

e. Along the side of the body, posterior to the thoracic ribs and near the horizontal septum, cut into the body and identify the three body layers, the *external* and *internal obliques* and the *transversus*. These are little modified from the condition found in Necturus. If the internal rectus abdominis is found, cut more dorsally for the body muscles.

f. In the tail cut into the muscles and observe the "cone-in-cone" arrangement. Several of the caudal muscles attach to the pelvis and will be considered later.

3. Rabbit.

a. Remove the very heavy, tough fascia from the dorsal part of the body, and from the sides of the abdomen and thorax. Also remove the fat from the axilla and the region between the thigh and the body.

b. Observe the heavy band of muscle tissue lying next the spinal column. At its lateral edge insert a finger under it, and separate this mass from the hypaxial group. The fascia lying between the two parts marks the old horizontal septum. It will be observed that the hypaxial group has grown dorsally, slightly overlying the epaxial group.

c. In the lumbar region the epaxial muscles may be divided into two groups:

(1) The more lateral *sacrospinalis* arises from the crest of the ilium and dorsal surface of the sacrum, and extends craniad. It is the most powerful muscle in the body, and divides anteriorly into several parts. In the thoracic region the most important is the *longissimus dorsi*. In the head region the longissimus cervicis has been dissected, it being a part of this group.

(2) The *multifidus* lies mediad to the sacrospinalis, being the narrow band on either side of the neural spine, and arises by long tendons from the transverse processes. The muscle is practically continuous with the *semispinalis* of the thoracic region. This last muscle has been identified. The muscles continue craniad to form a complex system of cervical and head muscles. The relationship of this group of muscles is practically the same in the rabbit as in man, except that in the latter the median group is not so prominent superficially.

d. The *intercostal* muscles may be dissected out on the side of the thorax.

e. On the side of the body wall locate the fibers of the *external oblique* muscle. These will be found extending in a more longitudinal direction than in the lower forms. Cut through the external fibers and expose the *internal oblique*, with its

fibers directed antero-ventrally. Internal to this layer will be a distinct *transverse* muscle, with the bundles directed ventrally and slightly caudally.

f. The *rectus abdominis* is thin and strap-like, extending from the pubic symphysis to the ribs. Its halves are separated by the *linea alba*, and it lies in the aponeurosis of the internal oblique where it splits near the mid-line.

g. The *caudal* musculature is not prominent in the rabbit, due to the shortness of the tail. Separate the fascia between the anus and the tail and observe the *coccygeal* muscles. The *pubo-* and *iliococcygeals* have a connection with the rectal fascia, and in man form the *levator ani* muscles.

4. Cat.

a. Remove the tough fascia from the dorsal part of the body, and from the sides of the abdomen and thorax. Also remove the fat from the axilla and the region between the thigh and the body.

b. Observe the heavy band of muscle tissue lying next the spinal column. At its lateral edge insert a finger under it and separate this mass from the hypaxial group. The fascia lying between the two parts marks the old horizontal septum. It will be observed that the hypaxial group has grown dorsally, slightly overlying the epaxial group.

c. In the lumbar region the epaxial muscles may be divided into two groups:

(1) The *multifidus* is a narrow band of fibers lying on either side of the vertebral spines. The fibers are relatively short, arising by long tendons from the transverse processes. The muscle is practically continuous with the *semispinalis* of the thoracic region. This last muscle has been identified.

(2) Laterad to the multifidus are the large *sacrospinalis* muscles which arise from the crest of the ilium and dorsal surface of the sacrum, and extend craniad. Slightly anterior to the sacrum the muscle can be divided into two portions, which continue anteriorly and divide into several parts. In the thoracic region the most important is the *longissimus dorsi*. In the head region the longissimus cervicis and capitis have been dissected, being a part

of this group. The complex of occipital and neck muscles which were not dissected are a specialized part of the multifidus and longissimus groups.

d. The *intercostal* muscles may be dissected out on the side of the thorax.

e. On the side of the body wall locate the fibers of the *external oblique* muscle. They will be found extending in a more longitudinal direction than in the lower forms. Cut through the external fibers and expose the *internal oblique*, with its fibers directed antero-ventrally. Internal to this layer will be the distinct *transverse* muscle, with the fibers directed ventrally and slightly caudally.

f. The *rectus abdominis* is a thin strong band of fibers extending from the pubis to the ribs, its halves being separated by the *linea alba*. It lies between the aponeuroses formed by the internal oblique and the transversus muscles.

g. The *caudal* musculature is fairly well developed in the cat. Separate the fascia between the anus and the tail and observe the *coccygeal* muscles. The *pubo-* and *iliococcygeals* have a connection with the rectal fascia, and in man form the *levator ani* muscles.

H. Muscles of the Pelvis and Thigh

1. Necturus.

a. Covering the *ventral* side of the pelvis are two superficial muscles. The more anterior is the *pubo-femoralis*, arising along the mid-line of the pubis as far as its anterior end. The fibers pass backward and outward to insert on the proximal part of the femur.

b. On the antero-lateral margin of the girdle, partly covered by the pubo-femoralis, is the *rectus abdominis*. It inserts broadly on the margin of the pubis, and passes imperceptibly into the body musculature.

c. Posterior to the pubo-femoralis is the *gracilis*, arising from the pubis and ischium and passing to the leg, where it inserts on the tibia. There is a transverse constriction at the level of the proximal end of the femur.

d. Insert a dull instrument under the gracilis and lift it, clearing away the connective tissue beneath. Cut the muscle and expose the *obturator*, arising on the pubis and ischium poste-

rior to the pubo-femoralis. It inserts on the proximal part of the femur.

e. Around the cloaca is a paired anal gland, one side of which should be carefully removed. Clear away the mucus and connective tissue, and expose the two longitudinal muscles.

f. Lying next the cloaca is a very thin band of muscle, the *ischio-caudalis*. It arises in the tail musculature, and inserts on the ischium.

g. Lateral to the former is a larger muscle, the *pyriformis*, divided into two parts. The smaller ventral portion goes directly to the gracilis, where it inserts on the fascia. Place the animal with the dorsal side up and draw the leg forward. The larger part of the muscle will be seen to insert on the femur. Trace the muscle backward to its origin on the caudal vertebrae.

h. Cut the pubo-femoralis and remove the posterior attachment of the rectus abdominis. Passing from the proximal end of the femur, paralleling the margin of the pubis, is the *ilio-psoas*, a narrow band of fibers. Its origin is on the inner surface of the pubis, and it inserts on the proximal end of the femur.

i. The most anterior muscle as seen from the ventral side is the slim *sartorius*. Its origin is at the juncture of the pubis and ilium, and it inserts on the tibia.

j. On the *dorsal* side of the thigh are four muscles. The most anterior is the *rectus femoris*, arising on the ilium and inserting on the knee.

k. Posterior to the former is the *vastus* muscle, arising on the ilium, and inserting in the common tendon at the knee.

l. Arising almost with the former, and inserting into the knee tendon is the *biceps femoris*.

m. The *semimembranosus* arises on the posterior border of the ilium, and inserts on the fibular side of the knee.

n. Cut the middle two of the superficial muscles described above and fold back. The *gluteus* muscle will be laid bare. It arises on the side of the ilium and inserts on the proximal half of the femur.

2. Alligator.

a. Clear away the fascia of the *ventral* side of the leg. Lying superficially in the middle of the thigh is the *gracilis*, which

arises by several heads, resembling the complexity of its mammalian homologue. On the proximal end of the tibia find the broad insertion of the gracilis and trace proximally to the origins. The anterior two heads lie close together and insert on the ischium; the posterior head is directed caudodorsally to insert on the ilium. The muscle is a flexor of the tibia and adducts the leg.

b. From the point where the anterior heads of the gracilis pass under the external rectus abdominis muscle, make an incision posteriorly for two or more inches. Raise the ventral caudal muscles and the abdominis, clear away the fascia, and continue the incision craniad for an inch or more. Be very careful to avoid cutting any pelvic muscles while making the incision which will expose their origins.

c. Immediately anterior to the gracilis is the *obturator internus*, arising from the anterior border of the ischium. It inserts on the middle third of the femur.

d. The more deeply placed *gemellus* is a slim muscle which can best be identified by its insertion on the femur in close contact with the preceding muscle. As it passes proximally to insert on the posterior border of the ischium it diverges from the obturator internus. The anterior head of the gracilis passes between the two.

e. Lift the ventral body muscles, and locate on either side of the proximal part of the obturator internus, a short, cone-shaped muscle. These are the two parts of the *obturator externus*.

   (1) The posterior, shorter head originates on the ischium, and is attached by a strong tendon to the trochanter of the femur.

   (2) The anterior head is smaller, but longer than the other. It has an origin on the ventral side of the pubis, and is inserted on the femur anterior to the other head.

f. Parallel to the second part of the preceding muscle is the *iliopsoas* muscle. It arises from the inner side of the pubis and is attached to the trochanter of the femur.

g. The *semitendinosus* is a deep muscle paralleling the gemellus. It arises by a long tendon from the ischium, passes distally as a slim rounded muscle and inserts on the tibia and fibula.

h. The *pyriformis* is a large muscle of the tail which is inserted on the posterior border of the femur. It can be located in the incision made through the caudal muscles.

i. On the *anterior* border of the thigh locate the *sartorius*. This is a thick muscle which can be seen from the ventral aspect, and arises from the ilium near its union with the pubis. As it passes to its point of origin it lies in contact with the dorsal margin of the ilio-psoas. It is reduced to a thin tendon which passes over the antero-median side of the knee joint.

j. At the middle of the front of the thigh is the insertion of the *psoas major*. The belly of the muscle is covered by the oblique muscles. From the point of insertion make an incision in a dorso-cranial direction almost to the epaxial muscles. Turn back the fold and observe the origin of the psoas on the under side of the transverse processes of the vertebrae. Follow the muscle to its insertion in a broad, heavy tendon on the proximal third of the femur.

k. Clearing the insertion of the psoas has laid bare a conical muscle between the sartorius and the psoas. This is the *iliacus* which inserts on the femur slightly distal to the psoas. The origin is on the inner side of the ilium, and cannot be traced without ruining the specimen.

l. On the *dorsal* and anterior sides of the thigh locate the broad *rectus femoris*. It arises from the crest of the ilium and inserts in a wide thin tendon on the anterior surface of the tibia. On its anterior border, arising from the most anterior part of the ilium is a small part of this muscle. This slip passes by a tendon into a deeper muscle of the thigh.

m. Immediately posterior to the rectus femoris, with an origin on the ilium, is the small *biceps femoris*. It is in two parts. The first runs parallel with the posterior edge of the rectus and inserts in a tendon on the knee. The origin of the second head is under cover of the first, and can be seen by lifting the latter. The deeper part passes posteriorly to the superficial head, and inserts on the posterior margin of the fibula.

n. Arising from the posterior margin of the ilium is the *semimembranosus*, a spindle-shaped muscle that bounds the posterior border of the thigh. At the bend of the knee the muscle becomes tendinous and inserts on the inner side of the tibia. From this tendon, a tendinous slip passes distally to the ankle

to insert in the tarsus. The semimembranosus is one of the largest flexors of the shank.

o. Arising on the ilium, immediately under the tendon of the rectus, is the *gluteus* muscle. It narrows to a point as it passes distally. The insertion is along the outer border of the femur.

p. Lift the biceps femoris and identify the double *vastus* muscle. It arises by two heads on the femur, separated by the gluteus. The two heads insert in a common tendon which passes over the knee.

3. Rabbit.

a. Spread the hind legs apart, being careful not to tear any of the muscles. Clear away the fat which usually lies between the thigh and the body wall. This portion of the body is called the *inguinal region*, as the inguinal canals through which the testes descend are at this point. Clear away the overlying connective tissue on the inner side of the thigh.

b. About the middle of the thigh is a very narrow band of muscle fibers extending from the deepest part of the thigh to the knee. This is the *sartorius* muscle, which arises on the inguinal ligament and inserts by a tendon on the median condyle of the tibia. Carefully cut the fascia on either side of the sartorius.

c. Covering the posterior half of the inner surface is the *gracilis*, forming a broad, comparatively thin sheet. It originates on the entire pubic symphysis, and inserts in a tendinous expansion on the fascia of the distal end of the thigh.

d. Anterior to the sartorius is the *vastus medialis*, which is not easily separated from the more anterior muscle. The muscle arises from the medial border of the femur for most of its length, and is inserted in the common tendon over the patella.

e. On the anterior border of the thigh is the *rectus femoris*. It originates by two heads from the ilium and inserts on the tendon of the knee. The superficial part lies in contact with the vastus medialis and covers the anterior margin of the leg. The deeper part may be located by separating the vastus medialis from the first part of this muscle. It is a cylindrical muscle arising from the ilium in front of the acetabulum.

f. Anterior to the sartorius cut the inguinal ligament, which lies in the deepest part of the angle formed by the body and

the thigh, and make a longitudinal incision about an inch long in the body wall. This will expose the *ilio-psoas*, arising from the ribs and transverse processes of the lumbar vertebrae, and inserting on the femur.

g. Cut the tendon of the gracilis and lay it back. This will expose two large muscles which seem continuous. The posterior one is the *adductor magnus* which arises from the ventral side of the ischial tuberosity, and inserts on the distal end of the medial surface of the femur, extending on to the tibia.

h. The *adductor longus* arises anterior to the preceding from the pubic symphysis and the ramus of the ischium. It is inserted on the proximal half of the medial surface of the femur.

i. The *semimembranosus* forms the posterior margin of the thigh. It is a spindle-shaped muscle lying laterad to the preceding, originating from the ischial tuberosity and inserting into the fascia of the shank with the gracilis. A tendon separates from the muscle and proceeds to the foot.

j. The *semitendinosus* lies completely buried in the adductor magnus. Make a longitudinal slit about one-third the distance from the anterior margin and locate the round, slim muscle just below the surface. The origin of the semitendinosus is on the ischial tuberosity, and the insertion is with the adductor magnus.

k. The anterior half of the *lateral* surface of the thigh is covered by a heavy fascia called the *fascia lata*. Slit this and separate the muscles below, taking care not to tear the muscles by ripping the fascia off.

l. The posterior half of the surface is covered by the two parts of the large *biceps femoris*. This muscle inserts on the shank, from the patella to the middle of the tibia, and can be separated by removing the tissue which lies between it and the semimembranosus. When this is cleared insert a finger and loosen the inner surface as much as possible. Separate the two parts by splitting the fascia of the outer side of the leg. Each part is roughly triangular, the posterior being larger.

   (1) The anterior part arises on the sacral and caudal vertebrae and inserts on the patella.

   (2) The posterior part arises on the ischium and the fascia of the thigh. It widens distally to insert on the lateral surface of the leg.

m. Raise the fascia lata and expose the large anterior *vastus lateralis*. This has origin on the greater trochanter, and inserts over the knee.

n. Posterior to the preceding, and lying between it and the anterior head of the biceps femoris, is the *vastus intermedius*. It is almost completely covered by the vastus lateralis, and is not easily separated from it. It arises from the trochanter and the surface of the femur, and inserts over the knee with the preceding.

o. Pull up the fascia lata to find its insertion dorsal to the *vastus lateralis*. Lay back the fascia to expose the dorsal muscles of the ilium and sacrum. The fibers of the fascia will be found continuous with the superficial part of the rectus femoris muscle. Now cut the two parts of the biceps femoris, making the incision about the margin of the lower third of the muscle. Lay both back.

p. Lying on the dorsal part of the sacrum is the thin *gluteus maximus*, partly covered by the anterior part of the biceps femoris. It has an origin on the fascia of the sacrum and a part of the ilium, and inserts on the third trochanter of the femur. This is the smallest of the gluteal muscles of the rabbit. In man it is one of the heaviest muscles of the body.

q. Cut through the gluteus maximus. This will expose the entire *gluteus medius*, which arises from the crest and the wing of the ilium. It is inserted on the greater trochanter. This muscle is a thin sheet covering the following muscle.

r. Make a transverse incision through the preceding; lift it, and expose the *gluteus minimus*, which has its origin on the entire lateral border of the ilium. It inserts on the greater trochanter. In the rabbit this is a large, heavy muscle, the name describing the human condition.

s. Lying between the ischial spine and the head of the femur will be seen the *gemellus* and *obturator* muscles. These should not be dissected, but their position and size may be determined. The gluteus, gemellus, and obturator groups in man form the buttocks.

4. Cat.

a. Carefully spread the hind legs apart, without tearing any of the muscles. Clear away the fat which usually lies be-

tween the thigh and the body wall. This portion of the body is called the *inguinal* region, as the inguinal canals through which the testes descend are at this point. Clear away the overlying connective tissue on the inner side of the thigh.

b. On the median side of the thigh are two superficial muscles. The flat band covering the anterior half is the *sartorius* muscle, which arises from the crest and medial border of the ilium and inserts over the patella. It is the most anterior muscle of the leg.

c. Covering the posterior half of the surface is the *gracilis* which arises from the caudal part of the ischium and pubis. At the distal third of its length it passes into a flat tendon, to insert on the tibia and surrounding fascia.

d. Spread the two superficial muscles, and if necessary cut the gracilis. Five large muscles can be identified as the deeper group of the medial side. Begin at the anterior (cranial) border.

e. Under the sartorius is the *rectus femoris*. This is a strong muscle arising on the side of the ilium and inserting on the patella.

f. Next in order is the *vastus medialis* which has its origin on the shaft of the femur near the head. It inserts rather broadly on the median side of the patella.

g. The *adductor femoris* appears as a triangular muscle lying under the gracilis. Its origin is along the symphysis of the pubis and ischium, and it inserts along nearly the whole of the ventral surface of the femur.

h. Posterior to the preceding is the *semimembranosus* which can be divided into two portions. The muscle arises on the ischium, and has an insertion into the distal part of the femur and the proximal part of the tibia.

i. Along the posterior border of the thigh is the *semitendinosus*, a slim muscle arising on the tuberosity of the ischium. It passes under the fascia of the gracilis to insert on the anterior border of the tibia about an inch from its proximal end.

j. Lying between the rectus femoris and adductor femoris at their proximal ends is a triangular group of three muscles. Passing through the abdominal wall and inserting on the medial, proximal part of the femur is the *ilio-psoas*. The

origin on the transverse processes of the lumbar vertebrae cannot be traced at this time. Where it passes through the inguinal wall it is a conical muscle.

k. Lying posterior to the preceding is the *pectineus*. It is a very narrow slip with an origin on the pubis and an insertion on the femur. This muscle and the following are closely united with the adductor femoris.

l. The *adductor longus* is a thin muscle lying along the border of the adductor femoris. Its origin is on the pubis, and it inserts on the femur about the middle of the shaft.

m. On the *lateral* side of the thigh locate the anterior *vastus lateralis*. It arises on the proximal end of the shaft of the femur, paralleling the rectus femoris for most of its length. Distally it fuses with this muscle and inserts with it over the patella.

n. The *vastus intermedius* lies deep against the shaft of the femur. It arises on the dorsal surface of the shaft of the femur, and on the fascia of the knee. It can be found by lifting the rectus femoris which completely covers it.

o. On the posterior side of the thigh is the large *biceps femoris*. The origin is on the tuberosity of the ischium, and from the origin the fibers spread to form a wide muscle inserting in an aponeurosis on half the tibia and surrounding fascia.

p. Lying immediately anterior to the proximal part of the biceps femoris is the small *caudofemoralis*. It arises on the caudal vertebrae and passes onto the thigh posterior to the trochanter of the femur. About midway the thigh it becomes tendinous and passes to the patella as a very small tendon.

q. On the dorsal side of the pelvis are the hip muscles. The most anterior one is the *gluteus medius*, a wide flat muscle, triangular in shape, which arises from the crest of the ilium and the transverse processes of several vertebrae. It passes laterally and ventrally to insert on the great trochanter.

r. Posterior to the preceding is the *gluteus maximus* a smaller muscle than the medius. Its origin is on the last sacral and first caudal vertebrae. It partly covers the gluteus medius as it passes to its insertion on the side of the great trochanter. This muscle was named from the human condition, where it is the largest muscle of the body.

s. Cut both the medius and maximus, avoiding the underlying

muscles. About the middle of the medius is the *gluteus minimus*, a conical muscle with a long tendon. It arises from the ventral part of the ilium, and inserts on the lateral side of the great trochanter.

t. Beneath the gluteal muscles are the smaller muscles, the *pyriformis*, the *gemellus*, and the *obturator*. These cannot be dissected at this time.

I. Muscles of the Shank

1. Necturus.

a. On the posterior (flexor) side of the shank identify the prominent *gastrocnemius*. It arises on the posterior border of the femur and passes as a thin broad muscle to its insertion on the tarsus and digits.

b. Cut the muscle and lay back the ends. Beneath it is the deep muscle of the shank, the *tibialis posticus*. It arises from the tibia and fibula, and inserts on the tibia and tarsus.

c. On the extensor side of the leg are three superficial muscles. The central one arises on the femur by a narrow tendon, and spreads as it passes to its insertion on the tarsus and phalanges. It is the *extensor digitorum*.

d. On the preaxial border is the *tibialis anticus*. It arises on the femur and inserts on the tarsus.

e. On the postaxial border is the *peroneus*. This arises on the femur and inserts on the fibular border of the tarsus.

f. Cut the flexor digitorum and expose the very small *poplitius*. It arises on the femur with a few fibers from the fibula, and passes to its insertion on the upper half of the tibia.

2. Alligator.

a. On the outer (dorsal) side of the shank there are three superficial muscles. The one on the preaxial side is the *tibialis anterior*, which arises from the head and neck of the tibia, and passes distally to unite with the following muscle.

b. The *extensor digitorum longus* springs from the external condyle of the femur, unites with the preceding muscle, and passes under the tibio-fibular ligament at the ankle. It breaks into four tendons which are inserted on the digits.

c. The *peroneus anterior* arises from the entire outer border of the fibula. It is inserted on a broad ligament which spreads

over the calcaneus, a part going to the rudimentary fifth metatarsal.

d. The larger of the ventral shank muscles is the *gastrocnemius*. It arises from the femur and tibia, and extends to the heel where it forms the *Achilles tendon*. From this tendon spring the flexors of the toes.

e. Anterior to the last is the *plantaris* which arises from the tibia and inserts with the gastrocnemius.

f. Raise the preceding two muscles and observe the small muscle in close contact with the tibia. It is the *flexor digitorum longus*.

3. Rabbit.

a. The most anterior (primitive dorsal) muscle is the *tibialis anterior*. It originates from the lateral condyle of the tibia, and inserts at the base of the second metatarsal. It is a thin muscle and can be easily separated from the muscle which lies under it, next the tibia.

b. The *extensor digitorum longus* is immediately beneath the preceding. It arises from a flat tendon on the patellar surface of the femur, and inserts on the phalanges of the digits by four tendons.

c. On the postaxial (fibula) side of the shank is a group of four muscles, called collectively the *peroneus*. When acting as a unit it is a lateral tractor of the foot. They arise from the tibia and fibula, and insert on the metatarsi.

d. The posterior (ventral or flexor) group can be separated into four long muscles. The *gastrocnemius* is the most superficial, and is a very thin muscle in two parts. The lateral and deeper heads cover the deeper muscles. The heads arise from the tibia and femur, and insert with the following muscle into the strong *Achilles tendon*.

e. The *soleus* is often included with the gastrocnemius. It is a thin muscle which can be located by raising the lateral part of the gastrocnemius. It arises from the fibula.

f. In contact with the soleus in the median line is the *plantaris*. It is larger than the soleus, and is practically covered by the medial head of the gastrocnemius. It arises from the lateral condyle of the femur. As its tendon passes over the plantar surface of the foot it splits into four tendons which insert on the second phalanges of the four functional digits.

g. Deeper than the three preceding is the *flexor digitorum longus*. Insert a finger under the Achilles tendon and slide it proximally to expose the flexor. It arises from the tibia and fibula, and passes distally to insert by four tendons into the phalanges of the digits.

4. Cat.

a. The most anterior muscle of the shank is the *tibialis anterior*. It has its origin on the upper part of the tibia and fibula, and inserts on the metatarsals.

b. Lateral to the former, and partly covered by it, is the *extensor digitorum longus*. It arises from the fascia over the femur, and inserts into the phalanges by four tendons.

c. On the lateral (postaxial) side of the shank is a group of muscles, the *peroneus* muscles. They arise from the tibia and fibula, and insert on the metatarsi. When acting as a unit they function as a tractor of the foot. The peroneus tertius of human anatomy is not morphologically a part of this group, and is present only in man and the gorilla.

d. Lying on the caudal side of the shank are the flexors. The *gastrocnemius* is the outer muscle, covering the posterior side of the shank. It is a thin muscle in two parts arising from the tibia and femur, and inserting into the strong *Achilles tendon* which passes over the tarsals onto the foot.

e. Lift the gastrocnemius and find the *soleus* which is almost completely covered by the former. It arises on the fibula and inserts with the gastrocnemius.

f. Lateral to the gastrocnemius and soleus, and mostly covered by them, is the *plantaris*. The superficial part of the muscle can be seen between the peroneus and gastrocnemius. This muscle arises on the lateral border of the patella, and inserts on the plantar surface of the foot. Its tendon is in close association with the tendon Achilles, and at times fuses with it, as in the human.

g. Deeper than the preceding is the *flexor digitorum longus*. It arises on the tibia and fibula and passes across the calcaneus as a small tendon to insert on the foot.

PART IX

DIGESTIVE AND RESPIRATORY SYSTEMS

A. Necturus

1. Cut the stitches with which the ventral incision had previously been sewed, thus opening the *pleuroperitoneal cavity*. Enlarge the incision until it extends from the pectoral to the pelvic girdles. Make this to *one side* of the mid-line, to avoid cutting blood vessels. Pry the jaws apart. On the *right* side, beginning at the angle of the jaws, cut through the jaws, hyoid bones and gills as far posteriorly as the pectoral girdle. Note that this is to be a *lateral incision*. Leave the other side intact.

2. Digestive System.

a. How many rows of teeth are there on the upper jaw? On the lower jaw?

b. In the mouth find the opening of the *esophagus*.

c. In the *peritoneal cavity* is the very prominent dark, elongated *liver*. Note the vascular *mesentery* that supports it. At the posterior end of the liver, between two small lobes, find the spherical *gall bladder*. Try to find the *bile duct*, leading to the intestine.

d. Dorsal to the liver is the elongated *stomach*. Is it divided into clearly differentiated cardiac and pyloric portions?

e. The alimentary tract continues as the *intestine*. That part close to the stomach and in contact with a small whitish gland at its bend, is the very short *duodenum*. The posterior end of the intestine is enlarged to form the *rectum*, which empties into the *cloaca*. The latter structure will be studied later, in connection with the urinogenital system.

f. The small gland already noted at the end of the duodenum is the *pancreas*. Further examination will show that it is triradiate, sending one branch toward the dorsal surface of the liver, another along the intestine, and a third along the mesentery. Can you find the *pancreatic duct?*

g. Near the distal end of the mesenteric lobe of the pancreas is the dark *spleen.*

3. Respiratory System.

a. The *external nares* are far anterior, being just to each side of the mid-line, and on the "upper lip."

b. Open the mouth. Find the *internal nares,* between the two rows of teeth, and ventral to the anterior limit of the eye.

c. On the mid-line of the floor of the mouth find the *glottis,* a small opening at about the level of the second gill. This is the opening of the anterior end of the *trachea.*

d. In the peritoneal cavity, dorsal to the stomach, find the paired elongated *lungs.* Note the texture of the walls. Are they of much use to the animal?

e. Note the *gill slits,* openings from the pharynx leading between the *external gills.* The slits are remnants of the internal gills and are homologous with those of the fish. The external gills are not homologous with these, but with the larval gills of other amphibia, and probably with those of the crossopterygian larva. How many external gills are there? In preserved specimens the true character of gills is not shown. In living animals they are very finely lobed, giving a huge surface. Muscles are present that enable the animal to keep the gills in motion. This ensures a constant supply of aërated water even though the animal does not change its position.

B. Turtle

1. If the plastron has not already been removed for injecting do so now (see Appendix III). With the plastron removed, the viscera will be found to be covered with a thin membrane, the *somatic peritoneum.* In most animals, this lies just internal to the ventral axial muscles, but the latter are missing in this animal. Note the muscles from the anterior and posterior girdles. One third of the distance between the anterior end of the pectoral girdle and the base of the tail is the *heart.* Posterior to this, on either side of the mid-line are the *abdominal veins.* With bone forceps remove the lateral part of the carapace between the girdles leaving a mass near the mid-line for support, thus giving access to the viscera. Ligate (tie off) each abdominal vein in two places, with the ligatures about one-fourth inch apart. Now make a

transverse incision through the peritoneum, cutting the abdominal veins between the ligatures. Continue this incision laterally and dorsally, and turn back the free edges. The space opened is the *peritoneal cavity*. If the animal is a female the large sac-like *ovaries*, filled with large yellow eggs of varying size, will be prominent. A large liquid-filled membranous sac may be prominent posteriorly. This is the *urinary bladder* which may be emptied by making a small incision.

2. Structures of the Peritoneal Cavity.

a. On both sides of the heart is the large *liver*. This is divided into the *right* and *left* lobes which are connected dorsal to the heart. The *gall bladder* is in the right lobe. Note how the dorsal surface of the liver conforms to the shape of the carapace.

b. Under the left lobe will be found the elongate *stomach*. This is poorly divided into a larger, anterior *cardiac*, and a posterior *pyloric* portion. At the end of the latter, just dorsal to the heart, is a slight constriction, the *pylorus*, the seat of a valve controlling the passage of food out of the stomach. Anterior to the cardiac portion will be seen the *esophagus* which connects with the mouth cavity.

c. The pylorus opens into the *duodenum*; which crosses the body transversely. As it passes the gall bladder it receives the short but large *bile duct*. Parallel to the duodenum, located in the mesentery, is the elongate *pancreas*. The *pancreatic duct* may be found near the right end of the pancreas and should be traced into the duodenum.

d. The duodenum passes insensibly into the *ileum*. These two parts comprise the *small intestine*. Trace it to the coiled posterior portion and note that the mesentery is thrown into coils corresponding to those of the ileum. In the female it may be necessary to remove the right ovary.

e. The *colon*, or *large intestine*, is the posterior continuation of the intestine. The junction of this and the ileum is marked by a distinct swelling, the rudimentery *caecum*. Just dorsal to this, embedded in the mesentery, is a dark red organ, the *spleen*, which is not a part of the digestive system. The colon crosses the body transversely, then bends sharply posteriorly. Just after this bend the colon empties into the *rectum*. On

either side of this in the male will be seen the testis with its tightly coiled epididymis.

f. Just ventral to the anterior margin of the girdle is the bilobed, membranous sac, the *urinary bladder*. This will be studied in connection with the urinary system, and must not be destroyed.

g. Separate the urinary bladder and the peritoneum from the muscles of the pelvic girdle, and with bone forceps cut the ventral part of the girdle at two points. Separate the muscles and remove the loosened median bones.

h. The dark tubular *cloaca* will be seen passing through the opening in the girdle. Trace this posteriorly to its opening on the ventral surface of the tail, and anteriorly to its junction with the rectum.

3. Respiratory System.

a. Lift the lobes of the liver to locate the *lungs*, which are flat and closely applied to the dorsal wall.

b. With bone forceps cut away the median portion of the pectoral girdle. Then with a heavy scalpel pry open the mouth, cutting the jaw muscles.

c. Within the mouth cavity notice the horny "beaks" which function as teeth. These are epidermal structures. On the roof of the mouth note the paired *internal nares*. The mouth cavity opens posteriorly into the *esophagus*. On the ventral surface of the mouth identify the Y-shaped *tongue*, pointed at its anterior end. Between its posterior elongations is the hard *laryngeal prominence*. Probe the anterior end of this, and a slit-like opening, the *glottis*, will be found opening into the *trachea*.

d. Slit the skin along the mid-ventral line of the neck. A tube that is supported by circular cartilaginous rings will be found. Trace this tube, the *trachea*, anteriorly to a distinct swelling, the *larynx*. Ventral and slightly anterior to this is a flat cartilaginous plate, the *body* of the *hyoid*. Extending posterolaterally on either side of this is a *horn* of the hyoid. The hyoid cartilages are modified gill arches.

e. Open the mouth and cut around the laryngeal prominence, thus freeing the enclosed larynx from the mouth for study. Embedded in its anterior end, supporting the two small flaps

that close the glottis, is the pair of *arytenoid* cartilages. Posterior to this is the circular *cricoid* cartilage, which is wider ventrally than dorsally. The larynx, which is supported by the latter cartilage, forms the "sound box" in the mammals. The *thyroid cartilage* is missing.

f. Trace the trachea posteriorly. It swings to the left and then passes dorsally, anterior to the left lobe of the liver. Lying dorsal to it will be seen a muscular tube, the esophagus. Anterior, but dorsal to the heart, the trachea divides into two *bronchi*, each bronchus proceeding to a lung. Do not follow the trachea after it dips dorsally, as blood vessels may be destroyed.

g. Lift the left lobe of the liver and remove the delicate clear membranes between it and the lung. Be careful not to destroy any blood vessels. The bronchus may now be seen entering the lung. The blood vessels of the lung will probably be seen at the same time.

C. Alligator

1. Open the mouth of the animal. In doing this, use an old, *strong* knife. Beginning on the inside of the mandible, work backward, cutting the pterygoid muscle. Continue around the posterior and dorsal sides of the rami of the jaw, until all this muscle is severed. Pass the blade of the knife between the quadrate and articular bones, cutting all the ligaments at the joint. Pry open the jaw, being careful not to injure the teeth. Insert the knife between the upper and lower jaws, and work posteriorly, thus cutting the temporal muscle. When this is done, the jaw may be opened to its full extent.

2. Examine the mouth region and identify the following structures:

a. On the outside find the *external nares*.

b. On the roof of the mouth find the *internal nares*.

c. Identify the flat tongue. This can be elevated, but cannot be protruded.

d. The posterior part of the tongue is produced into a fold, which, together with a velum from the roof of the mouth forms the *throat valve*. Note that this is in front of the internal nares. By closing this valve, the animal is enabled to lie

in the water with an open mouth, his nostrils just above the surface, and breathe without danger of getting water into his trachea. Also, he is enabled to swallow food under water, the dorsal velum being folded back over the internal nares.

e. Just posterior to the internal nares is a single median opening. This is the opening of the *Eustachian tubes.*

f. Immediately back of the throat valve, on the floor of the mouth, is the *glottis,* the opening of the *larynx.*

g. Continuing directly backward is the enormous *esophagus.*

3. The *visceral* organs are difficult to separate. Lengthen the ventral incision to extend from the pectoral to the pelvic girdles. At the ends of this opening make lateral incisions, and remove the lateral body wall. Between the abdominal wall and the *peritoneum* is the *diaphragmaticus muscle,* which extends much of the length of the body. Remove this, being careful not to injure two large veins, the abdominals, lying in the peritoneum to either side of the mid-ventral line. Spread the organs apart and with the back of a knife destroy the omenta binding them together. If it becomes necessary to cut the abdominal veins, ligate (tie off) each vessel twice, with the ligatures one-half inch apart. Cut the veins between ligatures.

4. Identify the following parts of the digestive tract:

a. The esophagus leads directly into the *stomach.* This is in two well-defined parts; a large *fundic,* and a smaller, globular *pyloric* region. Open the stomach to observe the highly muscular walls of the fundic and the thinner walls of the pyloric portion.

b. Split open the posterior end of the pyloric stomach, and note the valve that separates the stomach from the *duodenum.* This region is highly glandular. Make an incision and study the character of the walls.

c. The alimentary tract is continued as the coiled intestine which terminates in the enlarged *rectum.*

d. This in turn opens into the *cloaca.* There is a powerful annular (sphincter) muscle that guards the opening.

e. The *liver,* lying posterior to the heart, is bilobed, the right being the larger. Find the *gall bladder* and bile duct. Trace the latter to its opening in the intestine.

f. The *spleen* lies near the spinal column, posterior to the gall

bladder. Recall its mesodermal origin. Would you expect it to have a duct?

g. The *pancreas* lies along the duodenum. Find its duct. Into what part of the alimentary tract does it empty?

5. Identify the following parts of the respiratory tract:

a. To either side of the mid-line, anterior to the stomach, is a dark spongy *lung*. Turn to Necturus and compare the lungs of the two animals. How do they differ? Which would you expect to be the more efficient breathing organ? Why?

b. Entering the anterior end of each lung is the *bronchus*, arising as a bifurcation of the trachea. Note the cartilaginous rings supporting the walls of these structures.

c. About the middle of the trachea is the *thyroid gland*, consisting of lobes on either side, connected by the *thyroid isthmus*.

d. At the anterior end of the trachea is a broad sheet of cartilage, the *hyoid*. Remove the connective tissue to expose its limits. The large flat plate is the *body*, and the postero-lateral projections the *horns* of the hyoid. Slit the body of the hyoid along the mid-line. An expansion of the trachea, the *larynx*, will be seen dorsal to the hyoid. With scissors cut the tissue lateral and anterior to the larynx, thus freeing it from the floor of the mouth.

e. Almost in the mid-line, posterior to the glottis, the pair of *arytenoid* cartilages can be felt. Expose these and note that they abut against a larger transverse cartilage posteriorly. Trace this around onto the ventral side, where it expands slightly. This ring-like cartilage represents the *thyroid* and *cricoid* cartilages of the mammal. Insert the blade of a pair of scissors into the glottis and open the larynx. Determine the relation of the cartilages to the cavity. What is their function?

D. The Pigeon

1. If the pectoral muscles of the right side have not previously been laid back, and the sternum on that side removed, do so at this time. (See Appendix III.) Repeat the operation for the left side, and remove the remainder of the sternum, together with the medial portion of the clavicles and coracoids. In cutting through the coracoids and clavicles be careful not to injure the very thin-

walled *crop* lying at the base of the neck. *Do not* injure the pectoral muscles. When the abdominal cavity is opened, a sheet of membrane, thickly impregnated with fat will be found overlying the organs. This structure, the *great omentum*, is a fold of peritoneum.

2. Observe the following parts of the alimentary tract:

a. The *mouth*, bounded above and below by the *beaks*. What is their structure? Are there any *teeth* present? Within the mouth, find the openings to the *pharynx* and *trachea*.

b. The pharynx leads into the larger *gullet* (*esophagus*) which in turn empties into the very large *crop* in which grain will usually be found. Here the food undergoes a process of softening and maceration. What is the physiological advantage of this?

c. From the crop the esophagus leads into the *stomach*. This consists of two parts: the anterior small *proventriculus*, which may be mistaken for a part of the esophagus; and a large, muscular *gizzard*. The proventriculus is the secreting portion of the stomach. Some of the glands may be seen macroscopically. The juices here secreted are poured upon the food that is ground in the gizzard. Cut open both portions to observe the character of the lining, but *do not* separate the parts. Note the relatively small cavity of the gizzard. How soft is the lining? Are there any stones in the cavity? What is the significance of these two facts? Dorsal to the proventriculus is the small spheroidal *spleen*. Cephalad to this region is the *liver*. Most birds do not have a *gall bladder*, although it is present in some. Is it to be found in the Pigeon?

d. The digestive tract is continued as the *intestine*. The portion of this nearest the stomach is the U-shaped *duodenum*, between the limbs of which is the *pancreas*. The intestine proper is much coiled. Separate the coils as much as possible without breaking the *mesentery* that supports them. The intestine passes insensibly into the *rectum*, the point of junction being marked by small tubular outgrowths, the *rectal caeca*. The rectum empties into the cloaca, the details of which will be studied later.

3. Certain structures mentioned below cannot be located on account of injury to other systems. Study of these must be de-

ferred until the circulatory system has been dissected. This is left to the initiative of the student.

a. Attention has previously been called to the opening of the *trachea.* Also find the *external* and *internal nares.*

b. The trachea extends along the neck parallel to the esophagus. What is the character of the tracheal rings? After a short distance the trachea passes to the left of the crop, to the peritoneal cavity.

c. Dorsal to the heart the trachea divides to form the *bronchi.* At this bifurcation is a swelling, the *syrinx.* This is the "soundbox" of the bird. Where is sound produced in mammals and the alligator? *Do not* try to find the syrinx at this time, as it lies dorsal to the heart. Its cavity is the *tympanum* and the voice is produced by a median *semilunar membrane* at the posterior end of the syrinx. The trachea divides to form the *bronchi,* each of which leads into one of the *lungs.* Notice how closely the lungs are attached to the dorsal thoracic wall, and note that they are quite compact. They have little elasticity. Cut the lung and compare with those of Alligator or Turtle.

d. In addition to the lungs there are *air sacs,* which arise as bladder-like extensions of the mucous membrane of the bronchi. These sacs are seven in number. The paired *posterior thoracic,* closely applied to the side wall of the body, and the *abdominal air sacs,* lying in the coils of the intestine, are supplied by tubes that arise as a splitting of the bronchus within the lung. Anterior to this split, connections are given off from the bronchus to the paired *cervical,* and the median *interclavicular,* air sacs. These have probably been destroyed. There are connections between the air sacs and the cavities in the bones. Do the air sacs in any way aid the small lungs to maintain the high metabolism that is found in the bird?

e. The ramifications of these air sacs can be demonstrated in a freshly killed bird by uncovering and breaking the humerus, and then blowing smoke into the trachea with a glass tube.

E. Mammal

1. If they have not been destroyed by work on muscles, again locate and identify the salivary glands (see Part VI, E.). Using a strong scalpel cut through the masseter muscles. Pry open the

mouth, insert the scalpel, and cut other jaw muscles. Take hold of the upper and lower jaws and pull open the mouth to its fullest extent.

2. Oral Region.

a. The space between the lips and the teeth is called the *vestibule.* Identify the different types of *teeth,* which were described in connection with the skull.

b. The *tongue* is placed ventrally, attached at its posterior end to the hyoid bone, and is free anteriorly. The ventral part of the tongue is connected with the floor of the mouth by a fold of skin, the *frenulum.* About halfway between this and the incisors are two small papillae, the location of the openings of the ducts from the sublingual gland.

c. The dorsal surface of the mouth cavity is composed of the anterior *hard palate* and the posterior *soft palate,* the latter having no bone support. The hard palate is characterized by transverse ridges. What bones support this part of the palate? On the anterior part of the hard palate, just behind the incisors, is a small papilla containing the opening of the nasopalatine ducts, which connect the nares with the mouth cavity. Lateral to the third premolar of the cat, the second in the rabbit, is a small opening of the duct of the parotid gland, which may be seen with difficulty.

3. Pharyngeal Region. Cut through the floor of the mouth on either side, keeping the scalpel close to the mandible. Pull the tongue downward between the two rami of the jaw. On the tongue note the various *papillae,* the loci of many microscopic tastebuds. Study the following structures of the *pharynx.*

a. The soft palate may now be seen to be similar to a curtain descending at the dorsal end of the mouth cavity, cutting off a chamber in back of it, the *nasopharynx.* Slit the soft palate to expose this chamber. Opening into the anterior end are the *internal nares.* Posterior to these, on the lateral wall, will be found the openings of the *Eustachian tubes.* In man the pharyngeal tonsils (adenoids) are located on the walls of the nasopharynx.

b. On either side of the pharynx slightly anterior to the free edge of the soft palate, is a depression, the *tonsillar fossa.*

In each is located a soft rounded mass of lymphatic tissue, the *palatine tonsil.*

c. The pharynx narrows posteriorly into the *esophagus.* Just anterior to this is a mid-ventral slit, the *glottis,* guarded by a flap of tissue, the *epiglottis.* The glottis opens into the *trachea.*

d. Recall that in the Amphibia the internal nares open into the anterior part of the mouth cavity. How does the condition in the mammal differ from this? What is the functional advantage of the mammalian system?

4. The Hyoid. From the outside of the throat, feel a bone at the base of the tongue, extending most of the distance between the posterior ends of the mandibles. It is ventral to the posterior limit of the masseter. This, the *hyoid* bone, is V-shaped with the apex pointed anteriorly. Remove the muscle and connective tissue ventral to the bone, being careful not to injure any structures posterior to it.

a. On either side are two small projections, the *horns* or *cornua.* These projections have tendinous connections with the jugular processes of the skull. This bone in mammals is derived from the second and third visceral arches. It serves as a support for the base of the tongue and gives a base for the attachment of muscles. In many mammals the cornua are formed of several bones.

5. The Larynx. Posterior to the hyoid is the *larynx,* a cavity in the anterior end of the trachea. The ventral supporting cartilage is popularly known in man as "Adam's apple." After this is located, the incisions on either side of the tongue may be extended posteriorly, so that the whole structure may be pulled ventrally. *Do not injure* the large veins in this region. To prevent any injury separate the veins from the surrounding tissue, and leave them in place when the tissue is moved.

a. The glottis and epiglottis can be seen to better advantage. Spread the glottis and look into the larynx. On either side will be seen a *vocal cord.* Note that this is not a cord, but simply a flap-like extension of the lining. Separate the esophagus from the trachea.

b. The large shield-shaped cartilage on the ventral side is the *thyroid cartilage* which is incomplete dorsally. It arises from the fourth and fifth visceral arches.

c. Posterior to the thyroid cartilage and just anterior to the first *tracheal ring* is the annular *cricoid cartilage.* This is wider dorsally than ventrally, and passes beneath the posterior lateral extensions of the thyroid cartilage. This cartilage originated as a fusion of several of the most anterior tracheal rings.
d. The *arytenoid cartilages* are paired cartilages dorsal to the other two, and give support to the sides of the glottis.
e. Just posterior to these cartilages on either side of the trachea, is a flattened, oval, reddish lobe of the *thyroid gland.* The two lateral lobes are connected by the *thyroid isthmus,* extending across the ventral surface of the trachea. This gland is not a part of the functional respiratory or digestive systems, although it arises embryologically as a ventral outpocketing of the pharynx. The relation of the secretions of this gland to the maintenance of the general metabolism is of fundamental importance.
f. The tracheal rings are incomplete dorsally, forming a slight depression in which the esophagus is located.
g. Do not at this time trace the trachea beyond the thyroid gland.

6. The Pleural Cavities. The *pleural* and *peritoneal cavities* have been opened in connection with the injection of the circulatory system. (See Appendix III.)

a. The pleural cavities are paired, and situated lateral to the median pericardial cavity. Each pleural cavity contains a soft spongy *lung.* Is there more than one lobe to each? Does their shape correspond to the shape of the cavity? Cut into the lung to note its structure. With what is this correlated? *After* the dissection of the circulatory system dissect the trachea from the thyroid gland to the lungs, noting its bifurcation into bronchi.
b. The pleural cavity is bounded posteriorly by an arched muscular partition, the *diaphragm.* In what direction does the arched surface extend? Inspiration of air is accomplished partly by the flattening of this structure, creating a partial vacuum in the pleural cavities. The other agent is the intercostal muscles, by means of which the ribs are raised and cavities enlarged. Expiration takes place in part by the relaxation of the muscles which have enlarged the cavities.

c. The cavities are lined with a moist membrane, the *pleura.* The part that extends over the walls of the cavity is called the *somatic;* that over the lungs and indistinguishably fused to them, the *visceral.*

7. Peritoneal Cavity. The *peritoneal cavity* is lined with *somatic* (parietal) *peritoneum,* the organs being covered by the *splanchnic* (visceral) layer. The two are connected by the *mesentery.* Identify the following structures:

a. Find the *esophagus* as it passes through the diaphragm and enters the *stomach.* The junction of the stomach and esophagus is called the *cardia,* and the region immediately surrounding it the *cardiac* region. The sac-like bulge to the left of the cardia is called the *fundus.* The remainder of the organ is the *body.* The *pylorus* is marked with a constriction. The concave surface from the cardia to the pylorus is called the *lesser curvature,* the convex surface the *greater curvature.* The stomach is supported by the *mesogaster.* Only a small portion of this passes to the stomach, the remainder being in the form of a posteriorly directed sac, the *greater omentum,* the thin walls of which are usually streaked with fat deposited around blood vessels. In the RABBIT the omentum is a simple bag-like structure suspended from the dorsal body wall and greater curvature of the stomach. In the CAT the ventral wall of the omentum is attached to the greater curvature of the stomach, and its posterior surface encloses the pancreas. It is much larger than in the rabbit, forming an "apron-like" sheet lying ventral to the intestines.

b. The *liver* is convex on its anterior surface, fitting into the diaphragm. There are two main lobes, the *right* and *left.* Each is re-divided into the *lateral* and *median* lobes. On raising and separating the lobes the smaller *caudate* lobe will be seen. The *gall bladder* lies between the right median and lateral lobes, partially embedded in the former. The *cystic duct* from the bladder joins the *hepatic ducts* from the lobes of the liver to form the *common bile duct.* The *lesser omentum,* or *gastro-hepatico-duodenal ligament,* passes from the lesser curvature of the stomach to the liver. It is divided into two portions: (1) the *gastrohepatic ligament* from the lesser curvature to the liver, and (2) the *hepaticoduodenal* from the liver

to the first part of the intestine. The cavity formed by the former, which contains the caudate lobe, is continuous with that of the greater omentum. The bile duct continues to the duodenum enclosed in the hepaticoduodenal ligament. The *falciform ligament* connects the median lobes of the liver to the mid-ventral line. Anteriorly and dorsally it is continuous with the *coronary ligament,* which connects the liver with the diaphragm.

c. The duodenum of the RABBIT is very long. After it passes the pylorus it extends posteriorly as the *descending limb.* The short turn at its posterior end is the *transverse limb,* and the next portion, extending craniad, is the *ascending limb.* The *mesoduodenum* supports this part of the intestine. The *pancreas* is a light brown very diffuse organ situated in the mesoduodenum. It is found mainly in the form of glandular streaks along the blood vessels. The pancreatic duct enters the duodenum about an inch anterior to the beginning of the ascending limb. This position is an unusual one, the typical position being at the entrance of the bile duct.

d. The duodenum of the CAT is shorter than that of the rabbit. The *descending limb,* extending posteriorly, is long, but the bend, the *transverse limb,* and the anterior *ascending limb* are short. The structure is supported by the *mesoduodenum.* The *pancreas* is a light brown very elongate organ. It is located in the mesoduodenum and extends from the pylorus the entire length of the duodenum. It has two ducts, one entering the common bile duct and the other directly into the duodenum a short distance posterior to the first.

e. The portion of the small intestine immediately posterior to the duodenum is the *jejunum* and the remainder is the *ileum,* although there is no clear demarcation between the two regions. The separation is based on histological differences. In the cat the ileum is about twice as long as the jejunum, while in the rabbit they are about equal in length. The *mesentery* proper supports this part of the intestine.

f. In the RABBIT at the junction of the large and small intestine is an enlargement, the *sacculus rotundus.* Very close to this is an extremely large sac. The first foot of this is very large in diameter, and is known as the *caecum;* the distal end is smaller and is called the *vermiform appendix.* The large size

of the caecum is correlated with the storage of food. Bacteria in the caecum attack the cellulose walls of the plant cells, liberating the enclosed protoplasm and allowing the broken-down cellulose to be absorbed. Beyond the sacculus rotundus the large intestine is the *colon*.

g. In the CAT the small intestine enters abruptly into the large. The end of this extends posteriorly as a small blind sac, the caecum. There is no vermiform appendix.

h. The colon is divided into three main portions. The first extends anteriorly (*ascending* colon), the next crosses the body (*transverse* colon) and the last extends posteriorly (*descending* colon) to empty into the *rectum*. In the RABBIT the colon is long and the first part is characterized by longitudinal bands of the muscle, the *taeniae*, which gather the walls into pockets, the *haustra*. In the CAT the colon is short and the walls are smooth. The colon is supported by a portion of the dorsal mesentery, the *mesocolon*. *In both animals*, at the turn between the transverse and descending parts of the colon the mesocolon is secondarily fused to the mesogaster.

i. The descending colon disappears dorsal to the urinogenital organs. There, as will be seen later, it forms a straight tube, the rectum, which terminates as the *anus*.

F. Structure of the Digestive Tract

1. Discussion. The walls of the digestive tract are composed of four main layers. (1) On the outside of the intestine are *longitudinal* muscles. Adhering to the outside of these is the visceral peritoneum or serosa. (2) The *circular* muscles lie internal to the longitudinal. (3) The lining of the intestine is the mucosa. (4) The submucosa lies between the mucosa and the circular muscles. The mucosa is nearly always thrown into folds or pits, thus increasing markedly the total amount of secreting or absorptive surface. In the stomach the mucosa lines the many gastric pits, while in the intestine it is in folds or projections into the lumen. The regions in which the main absorption of food takes place vary widely, the small intestine absorbing the main part in the carnivores like the cat, and the large intestine a large portion in the rabbit. The antagonistic action of the two layers of muscles produces the peristaltic and antiperistaltic waves that churn the food, thus mixing it with digestive juices, and also forcing it posteriorly.

2. Ileum of the Mammal.

a. The major structures of a section through most parts of the intestine can be identified by the following description of the ileum of the cat.

b. Note that one side of the section has a smooth edge, while the opposite is highly serrated. The smooth edge is the outside of the intestine while the serrated surface lies next the lumen or cavity.

c. The outer part of the wall is composed of the external *longitudinal* muscles and the more internal *circular muscles.* Closely adhering to the outside of the longitudinal muscles is a very thin layer, the visceral peritoneum, or *serosa.*

d. The inner surface of the intestinal tract is lined with *mucosa.* Between the mucosa and the circular muscles is a layer of loose connective tissue, the *submucosa.* In the submucosa will often be found irregular patches of closely packed cells. The cells are characterized by a small nucleus with a very small amount of cytoplasm. This mass of lymphoid tissue is *Peyer's patch.* These patches are found mainly in the ileum.

e. Locate a region in which there is a projection of the submucosa into the lumen of the intestine. These projections (valvulae conniventes) are characteristic of the small intestine. The mucosa is thrown into club-shaped projections, the *villi,* which are barely visible with the naked eye.

f. Find a region where a villus is seen its entire extent. This will require considerable search and may not be found at all. If not, the parts can be synthesized. Place a villus under high power.

g. The covering epithelium of the villus is composed of a single layer of elongate cells. These are of two kinds: (1) The most apparent are cells containing a large light area. These are the *goblet* or *mucous cells,* and the flask-shaped transparent area is a mass of mucus within the cell. (2) Simple *columnar* cells which are elongated, have their nucleus near the base, and are nonsecretory. The cells rest upon an apparently structureless *basement membrane.*

h. The villus is supported by small strands of connective tissue and a few isolated smooth muscle fibers. It contains a small branch of the lymphatic system (lacteal) and capillaries.

PART X

CIRCULATORY SYSTEM

A. Necturus

1. A study of the circulatory system of the Dogfish gives an almost diagrammatic picture of the generalized vertebrate circulation. The descriptions of Necturus, Alligator, turtle and the pigeon are intended to give an idea of the main characteristics of the systems in these classes. The mammal circulatory system is given in more detail, mainly because it is much nearer the condition found in man. Review the general account of the circulatory system of the Dogfish. Necturus differs from the condition in Squalus in six main features:

a. The heart has developed a second auricle.
b. Correlated with this, pulmonary arteries and veins are present.
c. There has been a reduction in the number of afferent and efferent branchial arteries, correlated with the loss of the internal gills as breathing organs and the development of a smaller number of external gills.
d. The postcava has developed, taking over most of the function of the posterior cardinals.
e. The lateral abdominal veins of the Elasmobranch have fused in the mid-ventral line, giving rise to the unpaired abdominal vein of the Urodele.
f. The renal portal system is now connected with the abdominal vein by an anastomosis in the region of the pelvis.

2. The Heart.

a. Cut through the pectoral girdle and the ventral muscles to expose the heart, located in the *pericardium.*
b. The *ventricle* is posterior, and its walls are thick and muscular. The paired *auricles* are more anterior, have thin walls, and are darker in color than the ventricle.
c. Extending anteriorly from the ventricle is the heavy *conus*

arteriosus which opens into the *bulbus arteriosus*, the expanded base of the *ventral aorta*.

d. Lift the apex of the heart, and on the dorsal surface observe the *sinus venosus*, into which the venous trunks empty.

3. Afferent Branchial Arteries.

a. Trace the ventral aorta anteriorly by cutting through the anterior wall of the pericardium. The aorta splits into two lateral branches. One of these has previously been destroyed by the incision made during the dissection of the digestive system.

b. The other passes laterally and splits into two vessels. The more posterior of these splits again, thus forming the three *afferent branchial* arteries.

c. Trace the arteries to the gills. Using a needle, split the skin of the gill and lay it back with forceps. The artery sends up a loop which branches among the gill filaments.

4. The Efferent Branchial Arteries.

a. Remove the mucous membrane from the roof of the mouth, and locate the *efferent branchial arteries*. How many are there?

b. Trace the arteries back to the gills. What is the relation of the efferent and afferent branchial arteries?

c. The efferent arteries fuse in the mid-dorsal line, thus forming the *dorsal aorta*.

5. The Dorsal Aorta and Its Branches.

a. The first arteries to be given off the aorta are the *subclavians*, passing in the direction of the anterior limb. Follow one of them, being careful not to destroy any veins in doing so. After it passes into the arm it is called the *brachial* artery. This, at about the level of the elbow, splits to form the *radial* and *ulnar* branches.

b. The first visceral artery is the *gastric*, passing to the walls of the stomach.

c. Posterior to this, and best seen from the left side of the animal, is the *coeliaco-mesenteric* artery, representing both the coeliac and anterior mesenteric of the Dogfish. This gives rise to some *mesenteric* branches to the anterior part of the intestine; to the *splenic* artery passing to the spleen; to the *pancreatico-*

duodenal to the pancreas and duodenum; and to the *hepatic* artery entering the liver.

d. Posterior to the point of origin of this artery, several vessels branch from the aorta:
   (1) Several median *mesenteric* arteries passing to the intestine.
   (2) Numerous paired *genital* arteries to the gonads.
   (3) *Renal* arteries to the kidneys, strap-shaped organs lying on either side of the mid-line in the posterior part of the coelom.
   (4) Metameric *parietal* arteries to the body wall.

e. Close to the pelvic girdle the aorta gives rise to the paired *iliac* arteries. Each one gives off the *epigastric* artery which extends along the lateral body wall, and the *hypogastric* passing to the bladder. The main artery, now called the *femoral*, passes into the limb. Trace it to where it divides into the *tibial* and *fibular* arteries.

f. The aorta is continued into the tail as the *caudal* artery.

6. The Hepatic Portal System.

a. Stretch the mesentery of the small intestine. Halfway between the intestine and the dorsal body wall will be found the *mesenteric* vein.

b. Near the duodenum it is joined by many small branches: several *pancreatics* from that organ and the *gastrosplenic* from the stomach and spleen. In addition to this, it receives many small *intestinal* veins. The union of the mesenteric, gastrosplenic, and pancreatic veins forms the *hepatic portal vein*. The abdominal vein empties into this.

c. Trace the hepatic portal vein into the liver.

7. The Renal Portal System.

a. On the lateral side of each kidney find the *renal portal* vein. Trace this posteriorly and note that the two veins arise as a bifurcation of the caudal vein. Be careful not to destroy any structures of the urinogenital system or of the cloaca.

b. Emptying into the renal portal vein will be found the *iliac* vein from the hind limb. Trace this. The portion of the vein in the limb is called the *femoral* vein. It arises as a fusion of the *tibial* and *fibular* veins. Of particular importance, however, is a branch that leaves the iliac vein and, just anterior

to the limb, meets its fellow from the other side to form the *abdominal vein*. These branches are the *pelvic veins*.

c. It will thus be seen that blood in the posterior region passes anteriorly by one of two routes: (1) Through the renal portal system, or (2) through the abdominal vein into the hepatic portal system.

8. The Systemic Veins.

a. Lay back the body walls and move the intestine to one side. Near the dorsal attachment of the mesentery will be seen the large *postcava*. Trace this posteriorly, where it will be seen to originate between the kidneys, draining them of the blood brought by the renal portal system. Anteriorly the cava bends sharply ventrally to enter into the liver where it does not break into capillaries. It receives the *hepatic* veins from the liver. Trace the postcava through the liver and the transverse septum. It then breaks into two vessels, the *hepatic sinuses*, which enter the sinus venosus. The postcava originates as a fusion of numerous *renal veins* from the kidneys, and receives the genital veins from the gonads. At its turn into the liver, it gives off two much smaller branches, the *postcardinals*. These pass forward lateral to the mid-dorsal line, and enter the common cardinal veins. It is well to bear in mind that phylogenetically the part of the postcava posterior to the point where the postcardinals are given off is a fusion of the primitive postcardinals.

b. The *common cardinal* veins enter the lateral sides of the hepatic sinuses just before the latter enter the sinus venosus. Trace the right common cardinal laterally by removing the muscles between the pericardium and the pectoral limb. Just outside of the pericardial cavity, the common cardinal arises as a fusion of three vessels:

(1) The *subclavian*, which in turn is formed by the union of the cutaneous from the skin and the *brachial* from the arm. Trace the latter to where it originates as a fusion of the *radial and ulnar*.

(2) The *jugular*, homologous with the anterior cardinal vein of the Elasmobranch, arises as a fusion of the *external* and *internal jugulars*. The former receives branches from the floor of the mouth and from the head and jaws.

Just above the gills it has an enlargement, the jugular sinus. The internal jugular is small and difficult to find.

(3) The *lateral* vein from the body wall. It will be found by cutting into the horizontal septum between the epaxial and hypaxial muscles.

9. The Pulmonary System.

a. The *pulmonary artery* arises from the vessel formed by the union of the second and third efferent branchial arteries. It extends along the dorsal edge of the lung.

b. The *pulmonary vein* is located on the ventral side of the lung. It passes anteriorly, and just caudad to the transverse septum joins its fellow from the opposite side. The single vessel then penetrates the septum and enters the left auricle.

10. The Arteries of the Head.

a. At its entrance into the gill the first afferent artery gives off the *external carotid*. This turns mediad and branches into the floor of the mouth.

b. From the first efferent branchial artery, near the place where it joins the second and third, arises the *internal carotid*. This passes forward on the roof of the mouth accompanied by the internal jugular.

c. Near the fusion of the radices of the aorta the *vertebral artery* is given off. This passes dorsally into the skull.

B. Turtle

1. The turtle circulatory system differs from that of the Urodele in the following respects:

a. The heart now has the auricles completely separated and the ventricles partially so. In the Crocodilia the heart is truly four-chambered.

b. The abdominal veins are paired.

c. With the increased development of the postcava, the postcardinals, as separate veins, have been lost. The vertebral veins are perhaps a remnant of these.

d. Functional gill arches have been lost.

e. The pulmonary arteries no longer have any connection with the radices of the aorta.

2. Identify the *heart* about one-third the distance from the pectoral girdle to the base of the tail. Just posterior to this locate the paired *abdominal veins* to either side of the mid-line. Trace these posteriorly and note the connection between them just anterior to the pelvic girdle. If it has not been done previously, ligate each abdominal vein twice and then make a transverse incision through the peritoneum, cutting the *abdominal veins* between the ligatures Lay the cut edges back to expose the underlying structures. With bone forceps cut away the lateral part of the carapace between the pectoral and pelvic girdles.

3. The Heart and Its Vessels.

a. Remove the pericardium from the heart. The *apex* of the heart is pointed posteriorly, and contains the two incompletely separated *ventricles*. On the anterior surface are the two large *auricles*. Lift the ventricles to observe the *sinus venosus* as it enters the right auricle. Several vessels will be seen entering the sinus.

b. Three arteries will be seen leaving the base of the ventricles. Remove the connective tissues that bind these together, so that they are completely separated.

c. The vessel farthest to the animal's *left* is the *pulmonary artery*. Shortly after it leaves the heart it gives off a branch that passes beneath the other arteries. This branch is the *right* pulmonary, and the main vessel is now called the *left* pulmonary artery. Each branch passes to a lung.

d. The *left radix* of the *aorta* is the next artery leaving the heart. It extends to the left roughly parallel to the left pulmonary. Trace it as far as convenient dorsally. Then lift the left lobe of the liver and break the connective tissue between it and the lung. A large vessel will be found extending posteriorly in the peritoneum. This is the left radix, and should be traced forward. As the aorta passes toward the mid-line posteriorly it gives off several branches that will be described under Paragraph 4.

e. The *right radix* is the extreme right vessel from the heart. It dips immediately dorsally and the main part is hidden behind its large ventral branch, the *innominate* or *brachiocephalic* artery. Trace the latter vessel. It soon splits to give two parallel branches on each side. (1) The much larger ventral

branch is the *subclavian*, passing toward the limb. Trace it. A small vessel is given off from it to the *thyroid gland* which lies at the base of the "V" formed by the subclavians. A larger branch, the *ventral cervical* passes to the ventral neck muscles. After the artery passes through the peritoneum it is called the *axillary artery*. It gives off a large vessel that passes sharply dorsally, the *vertebral* artery. This gives off small branches to the dorsal shoulder muscles and continues anteriorly into the brain cavity. The axillary, now called the *brachial*, passes into the limb. (2) The smaller dorsal branch of the brachicephalic is the *carotid*. Trace it laterally with the subclavian. It soon bends to the mid-line, giving off a few very delicate vessels to the neck muscles, and passes anteriorly along the side of the neck to the head. In specimens with the head withdrawn it is thrown into folds. The *right radix* itself dips dorsally and then passes laterally and posteriorly, later swinging to the mid-line. By lifting the left lobe of the liver and separating it from the lung, trace the right radix to its fusion with the left radix.

4. The Dorsal Aorta and Its Anterior Branches. Although this term should be applied only after the fusion of the radices, some branches from the left radix are described, since these branches in other animals leave the aorta after the fusion.

a. From the left radix, before the fusion with the right, at a point dorsal to the stomach, three branches are given off simultaneously.

(1) The *gastric* passes toward the stomach, and then branches into the *anterior gastric* passing along the lesser curvature, and the *posterior gastric* along the greater curvature.

(2) The *coeliac* divides into two branches, the *anterior pancreatico-duodenal* and the *posterior pancreatico-duodenal*. The former supplies the pyloric stomach, liver, part of the pancreas, and the duodenum. The latter goes to the remainder of the pancreas, the gall bladder, liver, and duodenum.

(3) The *superior mesenteric* passes posteriorly supplying by many branches, the entire small intestine; and giving off a larger branch, the *inferior mesenteric*, which in turn supplies the colon, rectum and cloaca.

b. The aorta extends posteriorly giving off paired branches. Do not dissect the posterior part at this time, as it is dorsal to a large vein that should be dissected first. The posterior part is described in Paragraph 8.

5. The Abdominal Veins and Renal Portal System.

a. Find the abdominal veins that were cut previously during the transverse incision through the ventral peritoneum. First trace the anterior part. It bends sharply dorsally to enter the liver where it breaks into capillaries. At the turn, branches are received from the pericardium and from the ventral shoulder muscles.

b. Trace the posterior part of the abdominals, selecting the one that has the better injection. It bends sharply dorsally, receiving, close to the bend, the small *pelvic* vein from the ventral part of the pelvis. A short distance beyond the bend the small *crural* vein from the thigh muscles enters the abdominal.

c. Skin the dorsal surface of the leg. A large vessel, the *femoral* vein, will be seen partially embedded between two muscles.

d. Return to the abdominal veins. At the level of the dorsal portion of the base of the leg the *femoral* vein just noted fuses with the abdominal.

e. The *iliac*, the fusion of the femoral and abdominal, continues in a dorsal direction. Lift the leg and slit the skin between it and the carapace. Continue the incision posteriorly along the side of the tail, and remove the skin from both the leg and tail.

f. Extending anteriorly from the side of the tail and along the lateral side of the leg next to the carapace, is the large *caudal* vein. Trace this around the anterior side of the leg to where it fuses with the iliac to form the *renal portal*. Overlying the iliac vein at this point is an artery which should not be destroyed.

g. The renal portal vein receives a small branch from the carapace, and extends medially onto the ventral surface of the kidney, a yellowish, flat organ lying external to the peritoneum. Remove the peritoneal covering. The renal portal, as it lies on the kidney, receives two large branches. (1) an anterior branch, the *vertebral* vein, which can be traced by loosening the lung from the carapace. The vein will be found along the

sides of the vertebrae, in the space between the ribs and the carapace. (2) A posterior branch, the *hypogastric* vein, which turns sharply ventrally near the mid-line to its origin as a fusion of two vessels, the medial *cloacal* vein from that organ, and the lateral *internal iliac* from the superficial muscles of the posterior part of the leg. This fusion will be found lateral to the ventral part of the cloaca.

h. The renal portal vein enters the kidney where it breaks into capillaries.

6. The Hepatic Portal System.

a. Lift the lobes of the liver and gently separate them from the digestive tract. Dorsal to the pancreas, at the point where the mesentery supporting the stomach and duodenum is gathered into a ligament, is the large *hepatic portal* vein. Trace it posteriorly and determine its distribution. It drains the entire anterior part of the digestive tract, and also the spleen, pancreas and bile duct.

b. When the vessel enters the liver it breaks into capillaries. The hepatic portal is rich in absorbed food, much of the carbohydrate content being stored by the liver.

7. The Systemic Veins. Again examine the sinus venosus. Four veins will be seen to enter it. These are the paired *precavae*, the single *postcava*, and the *left hepatic*.

a. The left precava enters the sinus on the left side, where the sinus lies against the ventricle. Trace this vessel, which has the same branches as the right, lateral and dorsal to the heart. It is formed by the fusion of two small and one large vein:

(1) The *thyreo-scapular*, the most mediad of the group, is formed by the fusion of a vein from the thyroid with one from the ventral shoulder muscles. These fuse just before entering the precava.

(2) The *internal jugular* is about the same size as the thyreo-scapular. It passes anteriorly and then swings almost to the mid-ventral line, where it may be seen parallel to the carotid. It drains the head region.

(3) The subclavian is the most lateral of the three and by far the largest. After a short distance it makes a sharp bend anteriorly. Shortly after the bend it is seen to arise as a fusion of the *axillary* and *external jugular*. Trace the

former. Within the limb it is called the *brachial*. The external jugular extends anteriorly, lateral and dorsal to the internal jugular. The two jugulars have an anastomosis just posterior to the head.

b. The *left hepatic vein* from the left lobe of the liver can be traced directly backward into that organ.

c. The *postcava* enters the sinus on the left side, just posterior to the right precava. Trace it back through the right lobe of the liver. Note the several *hepatic veins* emptying into it as it passes through the liver tissue. It will be found to be near the mid-line posterior to the liver. The posterior branches will be described in Paragraph 8.

8. **Posterior Aorta and Postcava.**

a. The postcava bends to the mid-line ventral to the aorta, so it is desirable that the two be dissected together.

b. Between the kidneys the postcava will be seen to arise as a fusion of several *renal* veins, and *genital* veins from the gonads. Remove the postcava and renal portal veins.

c. The dorsal aorta gives off several *renal* arteries to the kidneys and *genital* arteries to the gonads. It splits into the paired *common iliac* arteries at the posterior end of the kidneys.

d. Loosen one kidney from the dorsal wall and fold it back so the vessels dorsal to it may be seen.

e. The *epigastric* artery leaves the aorta near the posterior end of the kidney. Just behind this will be seen the common iliac. Trace the epigastric. It passes laterally to the point where the renal portal vein turns toward the kidney. Here it divides into branches to the carapace, the fat bodies, and pelvic muscles.

f. The *common iliac* divides immediately into the *internal* and *external iliac* arteries. Trace the external branch. It soon gives off a small branch dorsally. This supplies some dorsal pelvic muscles and is continued into the dorsal surface of the leg as the *sciatic* artery. The major portion of the external iliac supplies more ventral muscles of the pelvis and continues into the leg as the *femoral* artery.

g. The *internal iliac* remains near the mid-line. It should not be followed at this time because of its close relation to the urinogenital system. It gives off branches to the rectum, bladder, reproductive organs, and pelvic region in general.

C. Alligator

1. As in the description of Necturus, only such detail is given as is necessary to give a clear idea of the main characteristics of the class. It must be remembered that there is a great amount of variation in the reptiles. The reptilian circulatory system differs from that of the Urodeles in four main features:

a. There is a true four-chambered heart in the Crocodilia; in other reptiles an incomplete separation of the ventricles.
b. With the greater development of the postcava, the postcardinals have been lost.
c. The abdominal vein is paired.
d. The functional branchial arteries have been lost.
e. The pulmonary arteries no longer have a connection with the radices of the aorta.

2. The Heart.

a. Remove the pericardium from the heart. The apex is pointed backwards. This portion, lighter in color, contains the *ventricles*. On the anterior part of the ventricles are the two dark *auricles*. Between the auricles, leading from the ventricles, is a large light structure, the so-called *conus arteriosus*. It will be greatly distended with injection mass.
b. Leaving the anterior end of the "conus" are four large arteries, two on each side of the mid-line. The two median ones are the *subclavians*, and the other two are the *radices* of the *aorta*. Lateral to the left radix, and more dorsal, are the pulmonary arteries, passing to the lungs. These will be seen to greater advantage later.
c. The heart will be studied later. In order to understand the system, however, it is necesary that the student know at this time from which ventricle each artery arises. Remember that this is a true *four-chambered* heart. From the *right* ventricle arise the left radix, and the two pulmonary arteries. From the *left* ventricle arise the two subclavians and the *right* radix. What is the condition of the blood, as regards aëration, in each of these arteries? There is some mixture of blood between the right and left radices.

3. The Dorsal Aorta. Separate the viscera from the body wall on the left side, and find the dorsal aorta as it passes along the mid-dorsal line.

a. Recall that in the animals previously studied the radices of the dorsal aorta met and later the aorta gave off the coeliac. In this animal the radices do not meet in the same manner, but there is simply an anastomosis between the two. This will be found dorsal to the apex of the heart. After this connecting branch, the left radix is continued directly as the *coeliac axis*, and the right radix continues along the mid-line as the *dorsal aorta*. What is the distribution of the coeliac artery?

b. Note the smaller lateral branches from the aorta leading to the body walls. These are the *parietal arteries*.

c. At about the level of the posterior end of the stomach is a large branch of the aorta, the *mesenteric artery*, supplying the posterior end of the intestine.

d. At the level of the anterior limit of the hind limb, and again at the level of the middle of the limb, paired branches are given off. The smaller anterior pair are the *ischiadic* and the larger posterior pair are the *iliac arteries*. While the former pair supply a part of the preaxial portion of the leg, the main supply of blood is received through the iliacs.

e. The aorta is continued into the tail as the caudal artery.

4. The Renal Portal System.

a. The *abdominal* veins have previously been noted as the large veins in the ventral peritoneum. Posteriorly they appear to arise as a bifurcation of the *caudal* vein.

b. Just anterior to the split, two short but wide *renal portal* veins are given off to the kidneys. From a comparative point of view, the *abdominals* originate as branches of the renal portals instead of as a bifurcation of the caudal.

c. The *abdominals* extend forward, each receiving the *iliac* vein from the hind leg, and numerous *parietal* veins from the body wall. In addition, the larger left abdominal receives branches from the stomach. They enter the respective lobes of the liver, but just before doing so, the left gives off a branch that anastomoses with the right abdominal.

d. The *abdominals* are not properly a part of the renal portal system. Recall the relation of the abdominal vein of Necturus to the hepatic portal and renal portal systems. This condition is carried farther in the Alligator, so that the abdominals

connect the renal portal system directly with the liver. The result is exactly the same in the two animals.

5. The Hepatic Portal System.

a. Spread apart the folds of the intestine. Embedded in the mesentery near its attachment along the mid-dorsal line is the *mesenteric* vein. As this passes forward it receives several *intestinal* veins, the *pancreatic*, and the *gastro-splenic*.

b. The union of the pancreatic and gastro-splenic with the mesenteric forms the *hepatic portal* vein.

c. Trace this forward to the liver. It enters the liver in the neighborhood of the bile duct, and there breaks into capillaries.

6. The Systemic Veins.

a. Displace the viscera to the left, and examine the region along the mid-dorsal line. Here will be found another large thin-walled vein, the median *postcava*. This originates by the fusion of a number of small *renal* veins. It passes cephalad *through* the right lobe of the liver, and enters the *sinus venosus*.

b. As it passes through the liver it receives a few small *hepatic* veins. As it enters the sinus venosus it may be joined by the main hepatic vein. More often, however, the main hepatic vein enters directly into the sinus.

c. Just to either side of the "conus" is a large vein, the *precava*. It has previously been noted entering the sinus venosus. Trace the left precava anteriorly. The right one is similar.

d. The precava arises as a fusion of two vessels; the *internal jugular* from the head, and the *subclavian* from the forearm. Trace the latter.

e. Extending anteriorly is the superficial *external jugular*. Dorsal to the entrance of this into the subclavian will be found the *subscapular* vein, having two branches and draining the muscles of the shoulder region. Beyond this point the subclavian is called the *brachial* vein.

f. Return to the internal jugular and trace it forward. Near the angle of the jaw it anastomoses with the external jugular of that side.

g. Between the subclavian and the heart the precava receives the *vertebral* vein which drains the brain. This vessel is often difficult to find. Trace it to where it leaves the vertebrarterial canal.

7. Arteries.

a. Trace the left subclavian artery away from the heart. It soon gives off two branches, both of which extend anteriorly. The more superficial is the *collateralis colli*, lying along the trachea. The deeper branch is the *carotid*. This dips to the mid-line dorsal to the esophagus.

b. Near the pterygoid muscle the carotid bifurcates. Each of the two branches, after sending a connection to the collateralis colli, enters the brain and the muscles of the head and upper jaw.

c. The subclavian, after giving off these branches, is continued in the direction of the arm. It immediately gives off the *vertebral* artery which passes over the surface of the lung and turns dorsally to enter the vertebrarterial canal, from which it passes to the brain. Beyond this, the subclavian gives off the *subscapular* artery to the muscles of the shoulder, and is then continued into the arm as the *brachial* artery. At the level of the elbow the brachial splits into the *radial* and *ulnar* arteries. Which one sends branches to the digits?

d. Observe that the right subclavian artery does not give off a carotid.

e. The ischiadic and iliac arteries have been noted as branches of the dorsal aorta. They should now be dissected. The former supplies blood to the body wall near the anterior limit of the leg. The iliac enters the leg as the *femoral*. After giving off small vessels to the upper part, at the knee it gives off the *tibial* and *fibular* to the corresponding sides of the leg. The femoral is continued as the *crural*. The tibial, fibular, and crural veins accompany these arteries.

8. The Pulmonary System.

a. Dorsal to the subclavians and radices of the aorta, find the *pulmonary arteries* again. Do they leave as a single vessel or as two separate ones? Trace them to the lungs.

b. The *pulmonary* veins are best located as they enter the left auricle. Trace them back to the lungs. From what part of this do they leave?

D. Pigeon

1. Only the main vessels are included under this description, as this animal is used only for comparison with the other classes.

The main differences between the bird and reptile circulatory systems are five in number:

a. There is no mixture of aërated and non-aërated blood.
b. There is no sinus venosus.
c. The left radix of the aorta has been lost.
d. There is a reduction of the renal portal system.
e. There is a great reduction of the abdominal vein.

2. Heart and Arteries.

a. Remove the pericardium and locate the main vessels coming from the heart.
b. The *dorsal aorta* leaves the left ventricle and immediately bends dorsally. At the first glance it is not visible at all because of this sharp bend.
c. The *brachiocephalic* or *innominate*, arteries, one on either side, are given off from the aorta. A little study will show that this is the true condition and that one of these vessels does not give off the aorta as a branch, as may at first appear. Each innominate divides into three main vessels:
   (1) The *carotid*, near the mid-line, going to the head;
   (2) the *subclavian*, to the wing; and
   (3) the *pectoral*, to the great wing muscle.
d. The *pulmonary arteries* come from the *right* ventricle as a single vessel which soon splits. The two branches will be found dorsal to the innominates, and should be traced to the lungs.

3. The Dorsal Aorta.

a. Displace the viscera to one side, and find the dorsal aorta on the mid-dorsal line. It gives off the following arteries:
b. The *coeliac* leaves the aorta just posterior to the heart, and goes to the stomach, gizzard, etc.
c. The *anterior mesenteric* leaves slightly caudad to the coeliac.
d. The *posterior mesenteric* is far posterior, and supplies the rectum and cloaca.
e. The *caudal* artery is a very short continuation of the dorsal aorta into the uropygium.
f. The *renal* and *femoral* arteries lie on the body wall, and go to the kidneys and hind limbs respectively.

4. Lying in the peritoneum on the ventral surface, is the delicate *epigastric* vein which drains the great omentum. This is thought

to be in part the homologue of the abdominal vein of the amphibia and reptiles.

5. Hepatic Portal System. Raise the right lobe of the liver. To its dorsal surface will be seen attached a mass of connective tissue. Enclosed in this is the *hepatic portal* vein. What is its function? Find the branch that goes to the other lobe of the liver. It arises from three main vessels:

a. The *gastro-duodenal*, draining the stomach and duodenum.
b. The *anterior mesenteric*, from the mid-region of the intestine.
c. The *coccygio-mesenteric* (a continuation of the *caudal vein*) which extends along the rectum and drains the posterior region of the alimentary tract. Which vessel drains the pancreas and spleen?

6. The Systemic Veins. Remove the stomach and intestine. Locate the tri-lobed *kidneys*, lying in depressions in the bones of the pelvic girdle on either side of the mid-line. Study the following vessels:

a. The *caudal vein*, draining the uropygium, is continued as the coccygio-mesenteric vein, a portion of the hepatic portal system. It also gives off a lateral branch on either side, which extends along the dorsal body wall. This branch is termed the *renal portal* vein, and differs from that of lower animals in not breaking up in the kidney, but merely sending branches to it.
b. The renal portal vein is joined by small veins from the posterior body wall, and, posterior to the kidneys, by the *internal iliac* veins draining a small portion of the leg. Between the first and second lobes of the kidney, the renal portal is joined by the large *femoral* vein, draining most of the leg. The resulting vessel is called the *iliac vein*. It receives several branches from the kidney.
c. Immediately anterior to the kidneys, the iliacs from the two sides fuse to form the large median *postcava*. This passes through the right lobe of the liver. As it enters the right auricle it is joined by the *hepatic veins*, from the liver, and the epigastric vein.
d. Beside the esophagus find the large *jugular* veins. The blood of the head returns to the heart by these vessels. Trace them anteriorly to their anastomosis. Anterior to the heart the jugular is joined by the *pectoral* vein from the great muscle,

and the *brachial* draining the wing. From this point posteriorly the vessel is called the *precava*. The two precavae empty into the right auricle.

e. Again find the pulmonary arteries. Then find the *pulmonary veins*. The latter empty into the left auricle.

E. Rabbit

1. The mammal circulatory system will be described in more detail than that of the other animals, mainly because it is much nearer the condition found in man. The major differences between the system of the rabbit and that of the reptile are:

a. There is no mixture of aërated and non-aërated blood.
b. The sinus venosus has been absorbed into the heart and so is not present in the adult.
c. The right radix of the aorta has been lost.
d. The renal portal system has been lost.
e. The abdominal veins have been lost, although their homologue may possibly be retained in part.
f. The postcardinals, which are not present in specialized reptiles, are retained in part as the azygos vein.

2. The Heart and Its Vessels.

a. Remove the pericardium, if this has not already been done. The mammalian heart is more compact than those studied previously.
b. The *apex* points posteriorly, and anteriorly is the flat broad *base*. Probe the walls and determine which parts are thickest.
c. The *ventricles* form a greater part of the heart, and occupy the posterior portion. The division into the *right* and *left* ventricles is marked by a slight groove extending from the left of the base to the right of the apex.
d. The *auricles* may be identified by their darker color and thinner walls.
e. Two large arteries may be seen leaving the anterior end of the ventricles. The more ventral, between the auricles, is the *pulmonary artery*. From which ventricle does this arise? Dorsal to this is the *dorsal aorta* (or just "aorta" in the mammal, there being no ventral aorta). From which ventricle does this arise?

f. Gently lift the heart so that the dorsal surface may be seen. Three veins will be seen entering the right auricle. Entering the anterior end of the auricle is the *right precava*. The *left precava* enters the right auricle on the posterior face, at the junction of the wall of the auricle with that of the ventricle. The precavae lie lateral to the heart on either side. The vein on the extreme posterior face is the *postcava*. Entering the lateral surface of the left auricle are the *pulmonary veins*.

3. The Systemic Veins.

a. The two precavae are identical in their branches except for the azygos vein. Trace the right precava. Just before the right precava enters the heart it is joined dorsally by a large vein, the *azygos*. Lift the liver and trace the azygos along the dorsal wall of the thorax. It passes posteriorly near the mid-line, receiving *intercostal* veins from the intercostal muscles of both sides. It is homologous with the right postcardinal of the lower forms, the left having been lost in many mammals. In man a part of the left postcardinal is also retained (hemiazygos). Slightly anterior to the azygos the precava is joined by a smaller vein which comes from the dorsal region of the anterior part of the thorax. This is the *superior intercostal* vein which drains the most anterior intercostal muscles. At about the same level a tributary will be seen extending antero-dorsally. This is the *vertebral* vein and may be traced to its exit from the vertebrarterial canal in the cervical vertebrae. It drains the brain.

b. A little anterior to the heart the precava may be seen to arise as a fusion of three vessels: (1) The small *internal jugular* which passes toward the mid-line and parallels the trachea in company with an artery (internal carotid) and a nerve (vagus); (2) the *external jugular*, which appears to be the anterior continuation of the precava; and (3) the *subclavian*, which extends laterally toward the limb.

c. Trace the internal jugular anteriorly to the head region.

d. Trace the external jugular. It soon sends an anastomosis across the ventral surface to its mate on the other side. Note the superficial *cephalic* vein located on the lateral surface of the upper arm. Trace this toward the body where it will be

found to enter the external jugular. Near the angle of the jaw the jugular arises as a fusion of two veins: (1) The *anterior facial*, draining the anterior part of the face and jaws; and (2) the *posterior facial* from the posterior part of the head.

e. Trace the subclavian. Internal to the body wall a posterior branch is received. This will be seen extending along the inner side of the sternum near the mid-ventral line, in company with an artery. It may be traced by picking away the transverse muscles. This vein, the *internal mammary*, extends beyond the thorax onto the abdominal wall, where it is called the *superior epigastric*. The *subclavian* penetrates the body wall anterior to the first rib. In the axilla, between the arm and the body, the vein is called the *axillary* vein.

f. The axillary vein receives the following tributaries:

(1) The *long thoracic* enters the axillary on its posterior surface. It extends along the outside of the ventral part of the thorax. Posteriorly it is continued on the abdominal wall as the *external mammary*, which drains the mammary glands. This portion lies next the skin and probably was removed with it.

(2) The *subscapularis*, a vein from the dorsal shoulder muscles, will be seen extending slightly posteriorly and then dorsally.

(3) Several small branches draining the shoulder muscles.

(4) The *brachial* vein is the continuation of the axillary within the limb.

g. The branches of the left precava are like those of the right, except that there is no azygos.

h. The postcava has previously been located entering the right auricle. Trace it posteriorly from this point. As the postcava passes through the diaphragm it receives *phrenic* veins from the diaphragmatic muscles. Pick away the liver tissue to determine its course through that organ. Note the *hepatic veins* which it receives within the liver. How did the blood in these veins get into the liver?

i. Locate the large bean-shaped kidneys outside the peritoneum to either side of the mid-dorsal line. The right is usually more anterior than the left. Near the anterior end of each, slightly mediad, is a small, rounded, yellowish organ, the *adrenal* (*suprarenal*) *gland*. This is an organ of internal secretion.

j. On the right side, near the anterior end of the kidney, the postcava receives two vessels. The more anterior is the *right adreno-lumbar* vein, collecting blood from the right adrenal gland and the body wall. The more posterior is the *right renal* vein. How did the blood in the latter get into the kidney? How does this differ from the condition in the anamniotes and reptiles? In some specimens the adreno-lumbar and renal veins will be found to unite before entering the postcava.

k. Now find the *left adreno-lumbar* and *left renal* veins. These almost invariably unite before entering the postcava.

l. The *genital* veins enter the postcava directly from the gonads. In the female this vein is called the *ovarian;* and in the male, in which it may be seen extending posteriorly into the scrotum, it is called the *internal spermatic.*

m. Loosen the cava and lift it gently to see the *lumbar* veins entering its dorsal surface. These are paired, but may fuse and enter the cava as a single vein. They drain the muscles of the dorsal portion of the body.

n. Near the posterior end of the peritoneal cavity the cava receives the paired *ilio-lumbar* veins. They pass laterally along the body wall.

o. Posterior to this point the aorta lies ventral to the postcava and conceals it. The remaining posterior branches will be described in Paragraph 7.

4. The Arch of the Aorta and Its Branches.

a. The aorta, after leaving the ventricle, turns to the left and passes posteriorly. The curved portion is known as the *arch* of the aorta; and the part directed posteriorly is divided into the *thoracic* aorta, anterior to the diaphragm, and the *abdominal aorta* posterior to that structure.

b. Three branches leave the anterior face of the arch of the aorta. From left to right these are the *left subclavian, left common carotid,* and the *brachiocephalic* or *innominate.* Trace the brachiocephalic.

c. The brachiocephalic immediately divides into two vessels, the median *right common carotid* and the lateral *right subclavian.* Trace the latter toward the limb.

d. As the subclavian passes through the body wall anterior to the first rib it gives off the following branches:

(1) The *vertebral* artery extends anteriorly and then bends sharply dorsally toward the cervical vertebrae. It enters the vertebrarterial canal and goes to the brain.

(2) The *internal mammary* passes directly posteriorly, internal to the sternum but outside the transverse body muscles. It can be followed by picking away these muscles. At the end of the sternum it is continued along the abdominal wall as the *internal epigastric.*

(3) The *superior intercostal* dips almost directly dorsally and then posteriorly to the dorsal part of the thorax. It gives off the most anterior intercostal arteries.

(4) The *transverse artery* of the *neck* passes laterally between the first and second ribs to the thoracic portion of the serratus anterior. It can be found on this muscle and traced back toward the subclavian.

(5) The *axillary* is the continuation of the subclavian in the axilla.

e. The axillary artery gives off the following branches before it enters the arm as the brachial:

(1) The *long thoracic* is a large artery extending directly posteriorly along the pectoralis muscle near its origin on the sternum. It is continued along the abdominal wall as the *external mammary* artery supplying the mammary glands. The latter portion was probably removed with the skin.

(2) The *subscapularis* extends slightly posteriorly and then dorsally. It supplies the dorsal shoulder muscles.

(3) Several small branches are given off to various muscles of the shoulder region.

f. Trace the *right common carotid.* It gives off branches to the trachea and esophagus. Immediately anterior to the thyroid gland the *superior thyroid* artery is given off to that gland. Another branch is given off to the larynx. Mediad to the angle of the jaw the common carotid splits into the large *external carotid,* and the *internal carotid.* The latter extends directly laterally and then dorsally to enter the brain case. The external carotid gives off a *lingual* artery to the tongue, the *external maxillary* to the masseter and upper and lower jaws, two small branches to the pinna of the ear, and then penetrates deeply and need not be followed.

g. Except for their origin the left common carotid and the left subclavian arteries are like those on the right side and need not be followed.

5. The Portal System.

a. This, in terms of mammalian anatomy, refers to the hepatic portal, since it is the only portal system in the body.

b. Locate the *portal vein* in the peritoneal cavity by lifting the liver and displacing the viscera to the left side. The vein will be found just dorsal to the common bile duct, and ventral to the postcava. Remove the fat and connective tissue. Do not injure any arteries in this dissection.

c. Trace the vein anteriorly and note its branches into the liver. Then trace it posteriorly. The tributaries are described from their junction with the portal, back toward their origins. In many cases it will be easier to find the vessels on the structures they drain and trace them toward the portal.

d. Just posterior to the point where a branch of the portal passes to the right lobe of the liver, the portal vein receives the *gastro-duodenal* on its right side. Trace this to its origin as a fusion of two vessels:

(1) The right *gastro-epiploic* drains a part of the greater curvature of the stomach and the omentum. ("Epiploic" comes from a Greek word meaning "omentum".)

(2) The *anterior pancreatico-duodenal* vein appears to be a continuation of the gastro-duodenal. It passes through the pancreatic tissue and along the first part of the duodenum to its anastomosis with the *posterior pancreatico-duodenal* vein which will be seen later.

e. Pull the descending limb of the duodenum with the attached part of the jejunum to the right side. Shortly posterior to the entrance of the gastro-duodenal, the portal is joined by the *gastro-splenic*. This arises as a fusion of two vessels:

(1) The *gastric* drains the walls of the lesser curvature. From the ventral side of the lesser curvature it receives the radiating *coronary* veins, and also a branch from the dorsal side of the lesser curvature. The "coronary" vessels of the stomach should not be confused with the "coronary" arteries and veins supplying the walls of the heart.

(2) The *splenic*, which is formed by a fusion of several branches from the spleen, the stomach, and the greater omentum.

f. Turn the duodenum back to the left side. Some distance posterior to the entrance of the gastro-splenic the portal receives the *posterior pancreatico-duodenal*. This extends along the mesentery and is seen to arise as two large branches. The more anterior branch, draining the anterior part of the descending limb of the duodenum, anastomoses with the anterior pancreatico-duodenal. The posterior branch drains the remainder of the duodenum. Both branches drain parts of the pancreas, although the anterior branch drains the greater part.

g. At the same point, but on the opposite side, the portal is joined by the *inferior mesenteric vein*. This passes along the dorsal part of the mesentery, receiving branches that drain the descending colon, part of the transverse colon and the rectum.

h. Beyond this point the portal is known as the *superior mesenteric* vein. It receives many branches. Note the intestinal vein, draining the greater part of the small intestine; and the *ileocaecolic*, draining the ileum, caecum, colon and appendix. The superior mesenteric vein drains all parts of the intestinal tract not previously mentioned.

6. The Thoracic and Abdominal Aorta.

a. As the aorta passes through the thoracic region it gives off numerous paired intercostal arteries to the intercostal muscles. How are the most anterior of the intercostal muscles supplied with blood? As the aorta passes through the diaphragm several small *phrenic* arteries are given off to the muscles of that structure.

b. The first median unpaired branch of the abdominal aorta is the *coeliac*. This arises from the aorta at a point dorsal to the cardiac portion of the stomach. The coeliac immediately gives off from its posterior surface the *gastro-splenic* artery. The latter sends a *gastric* branch to the left end of the stomach, the *left gastro-epiploic* along the greater curvature, and the *splenic* to the spleen. The coeliac, after giving off the gastro-splenic, is continued toward the dorsal surface of the stomach.

As it passes dorsal to the fundus it gives off an *esophageal* artery to the esophagus, and the *coronary* (or left gastric) artery. The latter can be identified by its radiating branches on the fundus and cardia. The coeliac now passes dorsal to the stomach and may be found by displacing the stomach to the left side. Near the pyloric end of the stomach the coeliac gives off two branches: the *right gastro-epiploic* to the omentum and lesser curvature; and the *anterior pancreatico-duodenal* to the duodenum and pancreas. (Sometimes these two vessels arise as the single gastro-duodenal which then splits into the two branches mentioned.) The coeliac also gives off the *right gastric* to the pylorus. The coeliac is then continued as the *hepatic* and enters the hepatico-duodenal ligament to pass to the liver.

c. The *superior mesenteric* artery leaves the aorta about an inch posterior to the origin of the coeliac. After about half an inch several small *middle colic* arteries pass to the transverse colon. Displace the colon to the left side and again find the superior mesenteric. A large vessel will be seen leaving the dorsal side of the superior mesenteric artery and passing to the pancreas and duodenum. This is the *posterior pancreatico-duodenal.* At about the same point the superior mesenteric splits into two vessels: (1) the *intestinal* which supplies most of the small intestine, and (2) the *ileocaecolic,* which passes toward the junction of the large and small intestine and supplies the posterior part of the ileum, the caecum and appendix, and the ascending colon.

d. Posterior to this the aorta gives off the paired *adreno-lumbar* arteries. Each divides into a branch to the adrenal gland and a branch to the adjacent body wall.

e. The *renal* arteries are also paired, each passing directly to one kidney.

f. The *genital* arteries are paired vessels arising about halfway between the kidneys and the girdle. In the female this artery is called the *ovarian* and passes to that organ. In the male, as the *internal spermatic,* it turns posteriorly and enters the scrotum to supply the testis.

g. Near the genital arteries the unpaired *inferior mesenteric artery* leaves the aorta. It passes directly ventrally in the mesentery where it splits into an anterior and posterior branch.

The anterior branch supplies the descending colon and anastomoses with a branch of the superior mesenteric. The posterior branch supplies a part of the colon and rectum.

h. Posterior to this the aorta gives rise to the paired *common iliac* arteries. Trace the right one. It gives off, on its anterior surface, the *ilio-lumbar* artery. This passes laterad and supplies muscles of the body wall. (This vessel often arises from the external iliac instead of the common iliac.) The common iliac splits into the large *external iliac*, which appears to be the direct continuation, and the small, more posterior, *internal iliac*. Trace the external iliac. As it passes through the body wall it gives off the *inferior epigastric* artery which sends branches to the inguinal region and, in the male, the *external spermatic* to the testis. The inferior epigastric itself extends anteriorly along the abdominal wall to anastomose with the superior epigastric. The external iliac is continued into the leg as the *femoral* artery.

i. The internal iliac should not be traced because of its close relationship to the urinogenital system which might thus be destroyed. It supplies the rectum, bladder, external genitalia, and, in the female, the uterus.

j. The aorta is continued beyond the common iliac as the caudal artery. This is more dorsal than the iliacs and should not be traced.

7. The Posterior Branches of the Postcava.

a. Remove the aorta and trace the postcava. The posterior branches may now be seen. At about the same level as the origin of the two common iliac arteries, the *external iliac* veins enter the postcava. Shortly posterior to this the postcava arises as a fusion of the two *internal iliac* veins. The caudal vein enters one of these.

b. Trace the external iliac. As it passes through the body wall it receives the *inferior epigastric* vein, extending along the body wall in company with the inferior epigastric artery. The external iliac also receives a branch from the bladder. In the female this branch also drains part of the uterus. The external iliac is continued into the leg as the *femoral*.

c. The internal iliacs should not be traced. They drain the regions supplied by the internal iliac artery.

8. The Pulmonary System.

a. The *pulmonary artery*, which leaves the heart ventral to the aorta, dips sharply dorsally. As it turns it is connected to the aorta by a cord of tissue, the remnant of the ductus Botalli (ductus arteriosus) of the embryo. Dorsal to this the pulmonary artery splits into the *right* and *left pulmonary* arteries. Trace each to its lung.

b. The *pulmonary veins* empty into the left auricle. The *left* pulmonary vein passes directly from the left lung to the auricle. The right vein passes dorsal to the heart to enter the auricle.

c. Note the bronchi, the branches of the trachea, entering the lungs. Remove one lobe and make a longitudinal incision through the bronchus, artery, and vein. Note the character of the lung, and the branches of the bronchus and blood vessels.

F. Cat

1. The mammal circulatory system will be described with considerably more detail than the other systems, mainly because it is much nearer the condition found in man. The major differences between the system of the cat and that of the reptile are:

a. There is no mixture of aërated and non-aërated blood.

b. The sinus venosus has been absorbed into the heart and so is not present in the adult.

c. The right radix of the aorta has been lost.

d. The renal portal system has been lost.

e. The abdominal veins have been lost, but possibly their homologue is retained.

f. The postcardinals, which are not present in specialized reptiles, are retained in part as the azygos vein.

2. The Heart and Its Vessels.

a. Remove the pericardial sac if this has not already been done. The mammalian heart is more compact than those previously studied.

b. The *apex* points posteriorly, and anteriorly is the broad, flat *base*. Probe the walls and determine which parts are thickest.

c. The *ventricles* form a greater part of the heart, and occupy the posterior portion. The division into the *right* and *left* ventricles

is marked externally by a slight groove extending from the left of the base to the right of the apex.

d. The *auricles* may be identified by their darker color and thinner walls

e. Two main arteries may be seen leaving the ventricles. The most ventral is the *pulmonary artery*. From which ventricle does this arise? Dorsal to this is the *dorsal aorta* (or simply "aorta" in the mammal, there being no ventral aorta). From which ventricle does it arise?

f. Gently lift the heart so that its dorsal surface may be seen. Two veins will be seen entering the right auricle. The one entering on the posterior face is the *postcava*, and the one entering laterally is the *precava*. The *pulmonary veins* will be seen entering the left auricle.

3. The Systemic Veins. It is desirable to dissect the systemic veins before the anterior arteries because of the more ventral position of the veins. As previously mentioned there is but one precava, the typical two having fused in the cat.

a. The *precava*, close to its entrance into the heart, is joined by a large vein from the dorsal thoracic region. Trace this vein by lifting the heart and picking away the connective tissue between the right auricle and the right lung. The vein, the *azygos*, will be found close to the mid-dorsal line. Note that it collects *intercostal* veins from the intercostal muscles. At the level of the anterior end of the lung the precava receives a mid-ventral branch, the *trunk* of the *internal mammary* veins. Where this leaves the sternum it will be found to be formed by a fusion of the *right* and *left* internal mammary veins. These are continued onto the abdominal wall as the *superior epigastric* veins. A little farther anteriorly the precava will be found to arise as a fusion of the *right* and *left brachiocephalic* (*innominate*) veins, the branches of which are alike. Trace the right one anteriorly.

b. The brachiocephalic immediately receives the *vertebral* vein on its posterior side. Trace this dorsally to where it leaves the vertebrarterial canal in the cervical vertebrae. The vertebral vein drains the brain. A short distance beyond this the brachiocephalic arises as a fusion of three vessels: (1) the large *subclavian*, which may be seen extending toward the

limb; (2) the large *external jugular* vein, which may be seen extending anteriorly along the side of the neck; and (3) the small *internal jugular* which extends anteriorly beside the trachea, accompanied by an artery (internal carotid) and a nerve (vagus). Trace the subclavian through the body wall into the axilla, where it is called the *axillary* vein.

c. The axillary receives a large vein on its antero-dorsal surface. This vein, the *subscapular*, extends dorsally to the muscles of the dorsal part of the shoulder. A short distance beyond this, the axillary is joined on its posterior surface by two small veins. The more mediad and smaller of the two is the *thoracocromial*, which drains some of the ventral shoulder muscles. The more distal is the *long thoracic*. This extends along the wall of the thorax under the pectoralis muscle. Posteriorly it is continued as the *external mammary* vein which drains the mammary glands. This part was probably removed with the skin. The axillary is continued into the limb as the *brachial*.

d. The *external jugular* at the level of the shoulder receives a lateral tributary. This vein, the *cephalic*, may be found as a superficial vessel on the lateral surface of the leg. Anteriorly the external jugular will be found to arise as a fusion of the *anterior* and *posterior facial* veins. The anterior facial, which drains the anterior part of the head, sends an anastomosis across the neck, ventral to the angle of the jaws, to its mate on the other side. The posterior facial drains the ear and posterior part of the head in general.

e. The *internal jugular* drains the brain. It may be traced forward along the trachea to the skull, from which it passes through the jugular foramen.

f. The *postcava* was previously seen as a large vein entering the posterior part of the right auricle. It can be traced posteriorly from this point. As it passes through the diaphragm it receives small *phrenic veins* from the muscles of that structure. Pick away the liver tissue to see the course of the postcava through that organ. Note the numerous *hepatic veins* which enter the postcava. How did the blood in these veins enter the liver? Did it pass through capillaries in the liver?

g. Posterior to the liver the postcava is located near the mid-dorsal line. Note the bean-shaped kidneys lying outside the

dorsal part of the peritoneum. The right is usually more anterior than the left. Near the anterior end of each kidney is the yellowish, ovoid *adrenal* (*suprarenal*) *gland*. *Adreno-lumbar* veins, draining the glands and the adjacent body wall, empty into the postcava. Posterior to these, the *renal* veins draining the kidneys enter the postcava. How did the blood in these veins get into the kidney? How does this differ from the system of the anamniotes? On the left side the renal vein usually receives a posterior branch, the *genital* vein. In the female this drains the ovary and oviduct and is called the *ovarian* vein. In the male it drains the testis and is called the *internal spermatic*. On the right side the genital vein empties directly into the postcava. Do not trace the postcava farther posteriorly at this time. The posterior branches will be described in Paragraph 7.

4. The Arch of the Aorta and Its Branches.

a. The aorta, after leaving the left ventricle, immediately bends to the left and then passes posteriorly. The bend is called the *arch* of the *aorta*. As the aorta passes posteriorly it is termed the *thoracic aorta*. After it passes through the diaphragm it is known as the *abdominal aorta*.

b. The arch of the aorta has two branches, the *brachiocephalic* and the *left subclavian*. Between the two is the small *coronary artery* which supplies the walls of the heart and the pericardium. The left subclavian lies to the left of the brachiocephalic. Trace the latter.

c. After about an inch the brachiocephalic splits into the two *common carotid* arteries. The *right* common carotid immediately gives off a lateral branch, the *right subclavian*. Follow this, as its branches are identical to those of the left subclavian.

d. The right subclavian passes antero-laterally toward the limb, and just before passing through the body wall gives off several branches:

(1) The *internal mammary* is a posterior branch which extends along the thorax to one side of the mid-line, giving off branches to the intercostal muscles. It may be followed by picking away the transverse muscles. It is continued beyond the thorax as the *superior epigastric*.

(2) At about the same point as the origin of the internal mammary, and on the opposite side, the subclavian gives off a branch, the *vertebral*, which dips sharply dorsally to the cervical vertebrae. Here it enters the vertebrarterial canal and passes anteriorly to the brain.

(3) In the same region the small *superior intercostal* artery is given off to the most anterior intercostal muscles. It leaves the subclavian artery on the same side as the internal mammary.

(4) The *thyroid axis* is given off slightly laterad to the vertebral, and on the same side. It passes directly anteriorly in company with the external jugular vein. When near the anterior limit of the shoulder it branches to various shoulder muscles.

e. The *axillary*, the continuation of the subclavian outside the body wall, gives off the following branches before entering the limb. As these are quite variable in their origin the student must depend largely upon the distribution of the arteries for identification.

(1) The *long thoracic* artery is a small branch of the axillary passing posteriorly along the side of the thorax. It passes beneath the pectoralis muscle and continues posteriorly onto the abdominal wall as the *external mammary*, supplying the mammary glands. This posterior part was probably removed with the skin.

(2) The *ventral thoracic* passes to the ventral muscles of the shoulder. Sometimes there is more than one.

(3) The *circumflex* extends dorsally beside the head of the humerus to the deltoid and triceps muscles. The axillary is continued into the arm as the *brachial* artery.

f. Return to the right common carotid. This continues anteriorly after giving off the subclavian. A *thyroid* branch is given off to the thyroid gland, and *esophageal* arteries to that structure. On the side of the head, lateral to the bulla, the common carotid divides into the *external* and *internal carotid* arteries. The latter immediately enters the cranium to supply the brain. The external carotid passes anteriorly along the side of the face, supplying muscles, and then passes into the brain cavity through several branches.

g. The left subclavian is similar to the right, except as to its

origin. The left common carotid is like the right, except that it gives off no subclavian.

5. The Portal System.

a. Displace the viscera toward the left side of the body, and find the *portal vein* entering the liver. It lies dorsal to the bile duct, and splits into branches supplying each lobe of the liver. Trace it posteriorly, picking away the fat in which it is partially embedded.

b. The *anterior pancreatico-duodenal* is a tributary entering the portal vein near the pylorus. To find this, separate the pancreas from the duodenum. The vein will be found lying in the mesentery next to the intestine. Trace it to its entrance into the portal and in the opposite direction to determine its distribution.

c. The *gastrosplenic* enters the dorsal side of the portal about three-quarters of an inch posterior to the pancreatico-duodenal. It will be found by picking away the fat surrounding the portal in this region. Trace it away from the portal vein. It extends directly dorsally and then turns posteriorly. At the bend it receives the small *pancreatic* vein from that organ. Displace the viscera to the *right* side and find the continuation of the gastrosplenic in the mesentery between the spleen and the stomach. Note the small *gastric* vein from the dorsal surface of the stomach entering the gastrosplenic. The main vessel, now called *splenic*, arises as a fusion of several vessels from the spleen. On the greater curvature of the stomach find several small veins partially embedded in fat. Trace these away from the stomach. The vessel formed by their fusion, the *gastro-epiploic*, may empty into the splenic or directly into the portal. On the lesser curvature find the radiating branches of the *coronary* vein. Follow this vein. It may empty into the portal vein dorsal to the pylorus or may fuse with other veins before entering the portal. The "coronary" vessels of the stomach should not be confused with the "coronary" vessels of the heart.

d. Return to the portal vein. Some distance posterior to the entrance of the gastrosplenic the portal received the *posterior pancreatico-duodenal*. This passes directly outward along the mesentery toward the end of the duodenum. It receives an

anterior branch that anastomoses with the anterior pancreatico-duodenal, and a posterior branch that extends along the jejunum.

e. At about the same level, the *inferior mesenteric* is received. This extends posteriorly to the large intestine where it may be seen extending anteriorly and posteriorly along the colon, caecum and rectum.

f. The portal beyond this point is called the *superior mesenteric*, and receives many *mesenteric* branches from the small intestine.

6. The Thoracic and Abdominal Aorta.

a. After the brachiocephalic and left subclavian arteries are given off the arch, the main vessel is continued posteriorly as the thoracic aorta.

b. The thoracic aorta gives off paired *intercostal* arteries to the intercostal muscles. How are the most anterior intercostal muscles supplied? As the aorta passes through the diaphragm it gives off *phrenic* arteries to the muscles of that structure. Beyond this point the main artery is called the abdominal aorta.

c. The abdominal aorta gives off paired metameric *parietal* arteries to the body wall, and very delicate arteries to the tissues of the mesentery.

d. The *coeliac* artery leaves the aorta just posterior to the fundus of the stomach. The variations of the branches of this artery are so great that no detailed description will be attempted. The following main branches are quite constant in their distribution, although variable in their origin: (1) the *hepatic* artery, passing to the liver; (2) the *pancreatico-duodenal*, supplying the pancreas and duodenum; (3) the *gastro-epiploic* supplying the stomach and greater omentum; and (4) several *splenic* arteries to the spleen. The hepatic is usually the first branch to arise from the coeliac.

e. The *superior mesenteric* leaves the aorta just posterior to the coeliac. It passes postero-ventrally, giving off many branches. Several small arteries are given off and pass along the mesentery directly to the anterior part of the small intestine. A large branch, the *ileo-caecolic*, passes toward the junction of the small and large intestines. Here it gives off many

smaller arteries along the ileum, jejunum, caecum, and anterior part of the colon. Another large branch passes posteriorly to supply the greater part of the colon, and to anastomose with an artery (inferior mesenteric) which leaves the aorta more posteriorly.

f. An *adreno-lumbar* artery is given off on either side of the aorta about a half-inch posterior to the superior mesenteric. It sends a very small branch to the adrenal gland and continues to the large dorsal muscles of the lumbar region.

g. Loosen the aorta and note the dorsal paired branches, the *lumbar* arteries, passing to the dorsal body wall.

h. The *renal* arteries arise from the aorta at the level of the middle portion of the kidneys. Each passes directly to the kidney where it breaks into capillaries.

i. The *genital* arteries leave the aorta at the level of the posterior end of the kidneys. In the female these are called the *ovarian*. In the male, as the *internal spermatic*, they pass posteriorly into the scrotum.

j. The *inferior mesenteric* is an unpaired branch from the aorta about an inch posterior to the genital arteries. It passes along the mesentery to the intestine where it splits into an anterior and posterior portion. The anterior part forms the anastomosis with the superior mesenteric that was seen previously. The posterior part supplies the posterior part of the colon and the rectum.

k. The *ilio-lumbar* arteries are given off a little posterior to the inferior mesenteric. They pass laterally, penetrating the body wall and supplying muscles of that region.

l. The *external iliac* arteries are large branches from the aorta near the anterior end of the pelvic girdle. Trace the right one. This gives off a posterior branch which immediately divides into four branches: (1) the *vesicle* artery which passes to the bladder; (2) the small *external spermatic* which crosses to the spermatic cord of the male and extends posteriorly to the testis; (3) *inferior epigastric*, which passes anteriorly along the inside of the body wall to anastomose with the superior epigastric; and (4) a dorsal branch which penetrates between muscles to supply some of the deep muscles of the thigh. The external iliac then passes through the body wall. External to the wall it gives off the small anterior *superficial epi-*

gastric, which anastomoses with the external mammary. The external iliac is now continued into the limb as the *femoral*.

m. The *internal iliac* arteries arise immediately posterior to the external iliacs. The aorta is continued posteriorly and slightly dorsally as the caudal artery. Do not trace either of these arteries, as the urinogenital system might be injured in the dissection. The internal iliac supplies the gluteal muscles, rectum, external genitalia, ovary and oviduct, and bladder.

7. Posterior Branches of the Postcava.

a. Remove the posterior part of the aorta. Loosen the postcava and lift it gently to see the unpaired veins entering its dorsal surface. These are the *lumbar* veins which extend dorsally, branching to drain the large muscles beside the vertebral column. Often these veins are paired.

b. The *ilio-lumbar* vein is paired, entering the postcava about halfway between the kidneys and the girdle. Each passes laterally, where it will be seen to arise as a fusion of two branches. One of these drains the muscles of the pelvic region and the other leads out of the kidney.

c. The postcava arises by the fusion of the two *common iliac* veins with the small median *caudal* vein from the tail. Trace the right common iliac.

d. The common iliac arises as a fusion of the larger *external iliac* with the smaller *internal iliac*. The latter is somewhat mediad and dorsal to the former. Trace the external iliac.

e. The external iliac immediately receives a small *vesicle* vein from the bladder. Just before passing through the body wall the external iliac receives the *inferior epigastric* which passes along the inside of the abdominal wall. It extends anteriorly and anastomoses with the superior epigastric. It accompanies the inferior epigastric artery.

f. The external iliac penetrates the body wall, receiving before entering the leg a small branch from the inguinal region. The external iliac is continued into the leg as the *femoral*.

g. The internal iliac will not be traced because of its intimate relation with the urinogenital system. It drains the regions supplied by the internal iliac artery.

8. Pulmonary System.

a. The *pulmonary artery* leaves the right ventricle, swings to the left, ventral to the aorta, and passes toward the left lung. Immediately after leaving the heart it gives off a dorsal branch, the *right pulmonary artery*, which passes dorsal to the heart toward the right lung. As the *left pulmonary artery* passes the aorta the two are connected by a stout cord of tissue, the remnant of ductus Botalli (ductus arteriosus) of the embryo.

b. The *pulmonary veins* pass from the lungs into the left auricle. There are two veins from each lung. The right pulmonary veins pass dorsal to the right auricle and ventricle, to enter the left auricle independent of the veins from the left lung.

c. Note the bronchi, branches of the trachea, entering the lobes of the lung. Remove one lobe and cut longitudinally through the bronchus and the artery and vein. Note the character of the lung, and the ramifications of the bronchus and blood vessels.

G. Structure of the Heart

1. Before starting this work, review the heart of the Dogfish. Then remove the hearts of the various animals. It is very important to leave attached to the heart *one inch* of all blood vessels. Otherwise, the work will be made needlessly difficult.

2. Necturus.

a. Identify the parts as given previously. The sinus venosus can be seen to much better advantage than before the removal of the heart. It opens into the right auricle.

b. Cut into the sinus venosus, and locate the opening into the auricle. This is guarded by the *sin-auricular valves.*

c. Continue the incision into the right auricle. Then open the dorsal surface of the left auricle. Wash out the injecting mass and observe the *interauricular septum.* This septum is incomplete, being perforated by several openings.

d. Now cut off the posterior end of the ventricle and wash out the injecting mass. Note the heavy spongy walls. The *auriculo-ventricular opening* is guarded by a pair of valves. The opening into the arteries is guarded by a transverse row of three *semilunar* valves.

e. The bulbus arteriosus has a longitudinal septum dividing it into right and left halves.

3. Turtle.

a. Identify the blood vessels attached to the heart.

b. Slit open the *sinus venosus* and remove any injecting mass or blood which it may contain. Note the *sin-auricular opening* into the right auricle. This opening is guarded by two flaps of tissue, the *sin-auricular valves*. They are simply folds of the wall.

c. Starting at the apex of the heart, cut along the sides of the ventricle as far as the auricles, thus making a dorsal and ventral flap. Cautiously separate the two flaps, removing any clotted blood or injecting mass. A thin "curtain" of tissue will be seen extending between the dorsal and ventral walls. This sheet is free on its lateral margins. The sheet is a continuation of the septum between the auricles and functions as the *auriculo-ventricular valve* of the openings from the auricles.

d. Make a small slit in each auricle and gently pass a probe through into the ventricles. It will be found that the openings are anterior to the lateral edges of the auriculo-ventricular valve, the opening from the right auricle being more dorsal than that of the left.

e. Make small incisions into the right radix, left radix and pulmonary artery near their origin. Carefully probe backward into the heart. It will be found that the openings of the left radix and pulmonary artery are close together and are separated from the opening of the right radix by a low muscular ridge. This ridge, which becomes closely applied against the opposite wall during contraction of the heart, is the incomplete *interventricular septum*. This incompletely divides the cavity into the very small *right* ventricle and the *left* ventricle which is the major part of the cavity.

f. Now make a horizontal incision along the anterior parts of the auricles to see the *auricular septum* which completely separates the auricles.

g. The course of blood in the turtle heart is rather complicated. Unaërated blood enters the right auricle from the sinus, and then passes into the ventricles. Due to the shape of the heart

this tends to eddy around into the small *right* ventricle. At the same time aërated blood is flowing from pulmonary veins into the left auricle and thence into the large left ventricle. Some mixture results. When the ventricle is partially full, the right auricle contracts, quickly followed by the left. This distends the ventricles which then contract, the right preceding the left. The mainly unaërated blood of the right ventricle passes out through the left radix and the pulmonary artery, while the mainly aërated blood of the left ventricle passes out through the right radix. The latter vessel, it will be recalled, gives rise to the brachiocephalic, so the head region receives a good supply of oxygen. During the contraction of the ventricles the ventricular septum becomes closely applied to the opposite wall, thus tending to reduce the mixture of the two types of blood.

4. Alligator.

a. Remember that while all other reptiles have a three-chambered heart, that of the Crocodilia is a true four-chambered one.

b. Orient the heart in the position which it occupies in the animal. The apex points backward, the base of the heart being anterior and containing the two auricles. On the dorsal surface of the heart find the very thin-walled sinus venosus, emptying into the right auricle, and the divided pulmonary vein entering the left auricle.

c. Carefully separate the arteries leaving the heart, by removing the surrounding connective tissue. It will be seen that the "conus" is less extensive than at first appeared. Identify all the arteries. Cut off the posterior ends of the ventricles and probe with straws to trace the origin of the vessels. Which come from the right and which from the left ventricle? Notice the slight difference in thickness of the walls of the two ventricles.

d. With scissors slit open the *right* and *left aortae*, continuing the incision through the walls of the ventricles. Observe the *auriculo-ventricular valves*. These are held in place by tendinous cords, the *chordae tendinae*, which run from the edge of the valve to muscular projections of the wall of the ventricle, called *trabeculae carnae*. The wall of the heart, the *myo-*

cardium, is composed of cardiac muscle tissue. What peculiar characteristics has it? The backflow of blood from the arteries is prevented by *semilunar valves*, easily identified by their cup-shaped, membranous structure.

e. At the point of exit from the heart there is an opening between the two radices of the dorsal aorta, the *foramen Panizzae*. This permits an admixture of the aërated and non-aërated blood. It is claimed that in quiet breathing the flow of blood is from the right radix to the left; but in rapid breathing the direction is reversed. With what physiological condition would this be correlated? How is the same result accomplished in the mammal?

5. Pigeon.

a. Identify the *auricles* and *ventricles*. The single aorta, from the right radix of the embryo, has been identified. Birds have a complete four-chambered heart, with no admixture of aërated and unaërated blood.

b. The pulmonary veins enter the left auricle; the systemic veins enter the right auricle.

c. Cut off the apex of the heart and observe the greatly developed walls of the left ventricle. The right ventricle is crescentic in shape, and tends to embrace the left. Wash any blood or injecting mass from the ventricles.

d. Carefully open the cavities of the ventricles and observe the valves. The left *auriculo-ventricular* valve has two membranes which are attached to the walls of the heart by tendinous cords. The right valve has a flap of tissue to close it. This type valve is peculiar to the birds.

e. Observe the walls, which are thrown into slight corrugations, the *trabeculae carnae*. From these arise the tendons (*chordae tendinae*) which pass to the valves to hold them in place as they close.

f. The *semilunar* valves of the arteries prevent the backflow of blood into the heart. They are cup-shaped structures.

g. The *sinus venosus* is missing, being absorbed into the right auricle.

6. Mammal.

a. As the dissection is carried on, it is well to have at hand an outline of the *cardiac cycle*, and to keep this in mind when

dissecting the structures. As a beginning for an account of this, assume that the semilunar valves are in the process of closing.

(1) At this time, the ventricle has reached the end of its contraction (*systole*) and is beginning its relaxation (*diastole*). The auricle has previously reached its peak of contraction, and is more nearly relaxed than the ventricle. At all times the blood from the venous trunks continues to pour into the auricles, except that at one period, to be pointed out below, it may be momentarily checked.

(2) Both parts of the heart continue to relax, the auricle completing its relaxation before the ventricle. The short but definite period between relaxation and the next contraction is the period of *diastasis.* The venous blood rapidly fills the auricle, and the pressure floats open the auriculo-ventricular valves. The ventricle then also becomes partially filled with blood.

(3) Contraction begins in the auricle and spreads into the ventricle. As the auricle contracts, a surge of blood tends to be sent in both directions. This partially or completely checks the inflow of blood momentarily, and also fills the ventricle and distends it to a slight extent. When, due to the contraction of the ventricle, the pressure mounts in that chamber, the auriculo-ventricular valves are forced shut, and the semilunar valves forced open. Continued ventricular contraction necessarily forces the blood into the arteries.

(4) The auricle is the first to become completely contracted. The ventricle reaches its peak of contraction immediately afterward. When the back-pressure in the arteries becomes greater than the pressure in the ventricle, the semilunar valves are forced shut.

b. Identify the parts of the heart, and the venous and arterial vessels entering and leaving it.

c. Make a transverse incision in each of the auricles, and wash them out. Find the complete *auricular septum* dividing the two auricles. On the floor of each chamber find the *auriculo-ventricular opening.*

d. Cut off the apex of the ventricles. Note the thick walls of

the left ventricle, and the thinner walls of the crescentic right ventricle. With what is this correlated? Separating the two ventricles is the *ventricular septum.*

e. Beginning at this cut, make an oblique incision along the wall of the right ventricle and the pulmonary artery. Wash out the blood and injecting mass that may be present, and study the following features:

(1) The *right auriculo-ventricular opening,* which has been seen previously from the auricle. This opening is guarded by the *tricuspid valve,* consisting of three triangular flaps of tissue.

(2) The ridges on the walls of the ventricle are the muscular *trabeculae carnae.*

(3) On the wall of the ventricle are small loops of muscle, attached at both ends but free at the middle. These, the *moderator bands,* tend to prevent over-distention of the ventricle.

(4) The *papillary* muscles are quite prominent projections from the wall. These are connected with the flaps of the tricuspid valve by the very slender *chordae tendinae.* These prevent the flap from being forced through the opening into the auricle.

(5) At the base of the pulmonary artery, are the three cup-shaped *semilunar valves.*

f. Make an incision along the wall of the left ventricle and dorsal aorta. The auriculo-ventricular opening on this side is guarded by the *bicuspid (mitral) valve.* This differs from the corresponding valve of the right side by having only two flaps. Identify the trabeculae carnae, moderator bands, papillary muscles, and chordae tendinae. Find the three semilunar valves at the opening into the aorta.

H. The Microscopic Structure of Blood

1. Amphibian.

a. Under *high power* study a drop of Frog's blood mounted in a normal salt solution. Observe the large yellowish *erythrocytes,* or red blood corpuscles. Why are they not red? Darken the field and try to see the smaller *leucocytes,* or white blood corpuscles. These are quite transparent and scarce in comparison with erythrocytes. Both types of cells

are nucleated. Note the shape of the cells. To see this, it may be necessary to take off the cover slip and study the cells with low power.

b. Stained slide. Make a smear of amphibian blood and stain with Wright's stain. For technique see Paragraph 3 below. This blood stain colors the nuclei blue and the cytoplasm pink. Note the nuclei of the erythrocytes. Pay particular attention to finding leucocytes. Note that there are different kinds, as judged by the shape of their nuclei. Draw as many different kinds as can be found.

2. Reptile.

a. Study under *high power* a drop of reptile blood mounted in normal salt. Compare the size of the erythrocytes with those of the frog.

b. Next study a prepared slide. The nucleated erythrocytes can be immediately identified. Note the number and size of the leucocytes, and after studying the stained blood of the human, return to this slide and compare.

3. Mammal.

a. Clean two plain slides, and two cover slips.

b. Sterilize a needle. With alcohol sterilize an area of skin on the fourth finger proximally to the nail. Wrap a handkerchief tightly around the middle phalanx and bend the finger. With the needle prick the finger immediately posterior to the cuticle of the nail.

c. Take a drop of blood on the edge of a slide, quickly place the edge on the surface of a second slide, and draw it across the second slide in such manner as to leave a thin film or smear of blood. Allow this slide to become perfectly dry. Proceed with the next paragraph in the meantime.

d. Place another drop of blood on a clean cover slip and drop it face down on a glass slide. Study at once. Observe the biconcave shape of the erythrocytes. In human blood there are between four and five millions in each cubic millimeter. The leucocytes number (normal blood) about 8,000; one for five or six hundred red corpuscles. The erythrocytes will soon form *rouleaux*, caused by the corpuscles piling up like stacks of coins.

e. As the blood dries the fluid medium becomes concentrated, resulting in osmosis from the corpuscle. The cell shrinks

and becomes irregular in outline. This is known as crenation, and the cells are popularly called "star cells". Observe the shape of the shrunken cells, and then with a pipette add a drop of tap water to the edge of the cover slip. As the fluid becomes hypotonic, notice that the cells take up the water, swell and become spherical. Draw a few crenated cells, and some that have become swollen.

f. Using the following technique, stain the smear prepared. (See Paragraph c.) With a pipette cover the smear with a few drops of the prepared Wright's stain, and let it stand for two minutes. Add an equal amount of water, and after three minutes wash in tap water until the edges of the smear become yellow in color. Drain by placing the edge of the slide on a paper towel. Dry the *under* side and study under high power.

g. The leucocytes are divisible into three general groups: (1) *lymphocytes* (20 to 25% of the leucocytes) are about the size of a red blood corpuscle, or slightly larger, and have a single nucleus with little cytoplasm; (2) *mononuclear leucocytes* (1 to 3%) are large, with a round or crescentic nucleus, and relatively more cytoplasm than the lymphocytes; (3) *polymorphonuclear leucocytes* which have nuclei variously constricted, often appearing multinuclear. The third type may be divided into different groups, based upon the staining reactions of the dyes. The aniline colors are acid, basic or neutral, and the cells are named from their affinities. The neutrophiles, cells which are stained by the neutral dyes, are most numerous (70 to 72% of all leucocytes) and will be stained reddish-violet; the acidophile cells contain cytoplasmic granules staining red (2 to 4%); and the basophile cells (0 to 1%) will appear purple and very granular.

PART XI

URINOGENITAL SYSTEM

A. Necturus

1. The urinogenital systems of the amphibia are very similar in the sexes, the following structures being common to both:

a. In the posterior part of the peritoneal cavity, located on either side of the mid-dorsal line, is the dark, elongate *kidney* or *mesonephros*. This is larger in the male than in the female.

b. Along the outer border of each kidney find the *Wolffian duct*. This is much more delicate in the female than in the male. Why?

c. Extend the incision through the pelvic girdle, taking care not to destroy any underlying structures. Locate the rectum. Open the cloaca to one side of the mid-line, continuing the incision into the rectum.

d. Ventral to the rectum is the elongated, sac-like *allantoic bladder*. Its opening is median, in the ventral portion of the cloaca. How does it function?

2. The Female.

a. Identify the *ovaries*. Each is suspended by a mesentery, the *mesovarium*.

b. Lateral to the ovaries are the much coiled white tubes, the *Müllerian ducts*, or oviducts. Locate their anterior openings, or *ostia*. The two ducts do not have a common opening as was the case in the Dogfish. What is the shape of the ostium? How is it attached to the body wall? Find the opening of each oviduct into the cloaca. Each is on a small papilla, lateral to the mid-line.

c. Just posterior to these openings is another pair, the openings of the *Wolffian ducts*. What is the function of these ducts in the female?

3. The Male.

a. Identify the *testes*. The mesentery by which each is attached is called the *mesorchium*.

b. Identify the *Wolffian ducts.*

c. Hold the mesorchium to the light, and notice the very fine tubules, the *vasa efferentia,* leading from the testis into the kidney. The sperm pass through the tubules of the kidney into the Wolffian duct. This anterior "sexual kidney" is the homologue of the epididymis of the amniotes.

d. Anterior to the Wolffian duct is a very minute strand of pigmented tissue. This is the vestigial Müllerian duct.

B. Turtle

1. The Male.

a. Remove the stomach and small intestine, leaving the colon and rectum in place.

b. The *metanephric kidneys* were noted previously as the paired flat yellowish organs near the mid-dorsal line. A *testis,* together with the coiled *epididymis,* will be seen ventral to each. The testis is a rounded organ, and is suspended into the peritoneal cavity by a distinct mesentery, the *mesorchium.*

c. Examine the coiled epididymis. Connecting it with the testis are delicate tubules in the mesorchium, the *vasa efferentia.* The whole mass is the homologue of the mesonephros of the anamniotes. Uncoil the epididymis and follow it toward the cloaca. Its posterior continuation is the *vas deferens,* or Wolffian duct.

d. Remove the epididymis and beneath it find the *ureter,* the duct from the metanephros. It is a straight tube and enters the cloaca just anterior to the vas deferens.

e. The cloaca has previously been exposed by cutting through the pelvic girdle. The dark structure ventral to the cloaca is the *penis.* Clear away the connective tissue, but while doing so note the muscles attached to the ventral wall of the cloaca which retract the penis. The posterior pointed part of the penis is the *glans.* At the anterior end are two rounded eminences, the *bulbs* of the *corpora cavernosa,* projecting into the coelom. They will be seen to be gorged with injecting mass.

f. Slit open the cloaca along one side. Examine the penis as seen from the inside of the cloaca. The *corpora cavernosa,* which are the erectile bodies, will be seen as two marked ridges. Between them is the *urethral groove* which, during erection, becomes a tube due to the increased size of the

cavernous bodies. At the anterior end of the cloaca are several structures that should be noted:

(1) The *accessory urinary bladders* are lateral outpocketings of the anterior end. They lie external to the peritoneum, against the posterior wall of the carapace.

(2) The *anus*, the posterior end of the rectum, is the large median opening. Insert a probe into the opening to check the identification. If necessary, make an incision in the rectum and probe toward the cloaca.

(3) The *urinary bladder* opens medially just ventral to the anus. Open the bladder, spread the walls apart, and note the median opening at its base. Insert a probe and find the opening in the cloaca.

(4) The openings of the *ureters* and the *vasa deferentia* will be found at either side of the anterior portion of the urethral groove.

2. Female.

a. The ovaries have been previously noted as the sac-like structures usually containing large eggs of various sizes. The ovaries are suspended by a separate mesentery, the *mesovarium*.

b. Lateral to each ovary is a coiled *Müllerian duct* or *oviduct*. Find the funnel-shaped opening of the anterior end, the *ostium*. Trace the oviducts posteriorly into the cloaca.

c. Remove the ovaries to expose the flat *kidneys*, or *metanephroi*. Leaving the ventral surface of each is a straight tube, the *ureter* or metanephric duct. Trace it to the cloaca.

d. Lateral to the posterior ends of the kidneys is a pair of thin sac-like structures external to the peritoneum. The function of these *accessory urinary bladders* is unknown, although variously claimed to be respiratory or hydrostatic. The median *urinary bladder* has been previously noted as a membranous sac ventrally placed.

e. The cloaca was previously exposed by the removal of the ventral bones of the pelvis. Remove the connective tissue surrounding the cloaca. The small dark organ attached to it ventrally is the *clitoris*, the homologue of the penis of the male.

f. Starting at the posterior end of the cloaca make an incision lateral to the clitoris. Anterior to this structure, swing the

incision to the mid-ventral line, continuing it into the urinary bladder. Be careful to keep the lower blade of the scissors as near the surface as possible. Open up the cloaca and note the following:

(1) Near the anterior end of the cloaca is the mid-dorsal *anus*, the opening of the rectum.

(2) Lateral to the dorsal margin of the anus is a pair of very wide openings leading into the *accessory urinary bladders.*

(3) Anterior and ventral to the anus the extreme anterior end of the cloaca is partially divided off into a separate chamber by a fold of the lining. On the sides of this anterior chamber are the openings of the two *oviducts.* Just anterior to each large oviducal opening is the very minute opening of the *ureter.* This probably can be found only by inserting a bristle into the duct and pushing it toward the cloaca. Between the oviducal openings is a median opening into the *urinary bladder.*

C. Alligator

1. Remove the digestive tract, leaving the rectum in position. The *metanephric kidneys* are lobulated organs closely applied to the dorsal wall outside the posterior part of the peritoneum. The peritoneum covering them is usually heavily pigmented, and should be removed to expose the kidney. Leaving the posterior end of the kidney is a large duct, the *ureter*, or *metanephric duct.*

2. The Male.

a. The *testes* are located median and ventral to the anterior part of the kidney. The testis is supported by a separate mesentery, the *mesorchium.* Leaving the testis is a slender duct, the *vas deferens.* This, the Wolffian duct of lower forms, extends posteriorly toward the cloaca.

b. Within the cloaca locate the *penis.* The free end or *glans* of the penis is directed posteriorly. The *base* of the penis is attached to the pubic symphysis. The penis is bent into a distinct arc. Along the convex surface is the *urethral groove.* During erection this groove is closed into a tube by the increase in size of the erectile bodies, and serves as a duct for the semen.

c. Within the cloaca are the following structures:
   (1) The *anus*, the posterior end of the rectum.
   (2) The openings of the Wolffian ducts (vasa deferentia) and the ureters.

3. The Female.

a. The *ovaries* lie in the same relative position as the testes. In sexually immature specimens they are about the same size as the testes, but are indistinctly marked off into lobes. The ovary is supported by the *mesovarium*.

b. Laterad to each ovary is a coiled tube, the *Müllerian duct*, or oviduct. Trace it to its anterior end where it opens into the body cavity by the *ostium*. Trace it posteriorly into the cloaca.

c. Within the cloaca find the small *clitoris*, the homologue of the penis of the male. It is of the same general shape as its homologue.

d. The *anus*, and openings of the ureters and Müllerian ducts, may be found within the cloaca.

D. Pigeon

1. The bird urinogenital system is an example of the cloacal type, which is typical of birds and reptiles. In the pigeon no penis is present, though found in some birds (duck, goose, and ostrich); and when found is homologous with the penis of the mammals. The penis of Alligator and turtle is similarly homologous, but that of the snakes and lizards is not.

2. Male.

a. The *kidneys* are tri-lobed, and are set in depressions of the bones of the pelvis. As in all amniotes the kidney is a *metanephros*.

b. Ventral to the kidneys are the paired bean-shaped *testes*.

c. Dorsal to each testis extending toward the cloaca, is a white convoluted tube, the *vas deferens*. What is this tube embryologically? What is its function? At its posterior end is an enlargement, the *seminal vesicle*. Find this, but do not injure the structures of the cloaca.

d. More or less parallel to the vas deferens is a straight tube the *ureter*. How did this arise? Find its connection to the kidneys, and trace it posteriorly.

e. At the anterior end of the kidney is an irregular yellow body, the *adrenal gland*. This is not properly a part of the urinogenital system, but an internally secreting gland, having an effect on the sugar content of the blood, on the circulation during fright, etc.

f. The *cloaca* is described under Paragraph 4.

3. Female.

a. The female urinogenital system is remarkable for having only one ovary and oviduct. They are paired in the embryo, but before hatching, the right ovary and duct have atrophied, leaving the *left* as the adult structure. Occasionally traces of the degenerate ovary remain and may be identified. The right oviduct is usually present as a vestige.

b. Identify the large, lobed *ovary*. This has rounded, unequal prominences which are caused by the *ova* within the *follicles*.

c. Lateral to the ovary is the large *left* oviduct. What is this embryologically? Find its opening, the *ostium*, which will be found near the ovary. Note its large size in the adult bird. The duct empties into the cloaca.

d. Find the *ureter* as for the male.

4. Make a *transverse slit* in the *cloaca*, continuing the incision into the rectum. Note the subdivisions of the cloaca.

a. The *coprodaeum* is the chamber into which the rectum opens.

b. Dorsal to this and separated by a fold is the *urodaeum*, into which empty the urinary and genital ducts. Find these openings.

c. The most dorsal and external compartment is the *proctodaeum*. This is a small chamber with a raised rim which opens to the exterior through the *anus*. On the anterior wall notice a small median opening. This opens into a small sac, the bursa fabricii. The function is unknown. Find this sac.

E. Mammal

1. Remove the intestinal tract, but leave in place the rectum and two or three inches of the posterior part of the colon.

a. The *kidneys* (metanephroi) are bean-shaped, dark-red structures near the mid-dorsal line, the right being the more anterior. The shape varies in the amniote groups, even within the mammalia. In man the left kidney is slightly more anterior

than the right. As in all vertebrates, the kidneys are outside the peritoneum. Remove the peritoneum and adipose tissue from around the kidney. The mediad portion has a depression, the *hilum*. Connected with the organ at this point may be seen blood vessels and also a white tube, the *ureter*. This immediately turns at a right angle and passes posteriorly near the mid-dorsal line.

b. Trace the ureters to where they enter a white muscular structure, the *urinary* (*allantoic*) *bladder*.

c. The bladder is prolonged posteriorly to enter the *urethra*, which opens distally in close association with the outlets of the genital ducts of both sexes.

2. **The Male.**

a. The parts of the external genitalia have previously been noted (see Part VII, page 111). Slit the skin ventral and anterior to the penis. Note the pointed end, the *glans* of the penis, and the *prepuce* which is a fold of skin enclosing the organ. Trace the hard cylindrical penis to its firm attachment to the pelvic girdle.

b. Carefully split the skin of the *scrotum* ventral and slightly anterior to the testis. Note that the wall of the scrotum is composed of muscles. These are homologous to the muscles of the body wall, and formed as an outpocketing of them during the descent of the testis. The lining of the scrotum and the smooth covering of the testis are continuous. These smooth membranes, the *tunica vaginalis*, are outpocketings of the peritoneum; and the space between the *somatic* portion lining the scrotum and the *visceral* portion covering the testis is a part of the *coelom*. The testis is therefore outside the peritoneum. In the cat and in man the cavity of the scrotum is entirely separated from the peritoneal cavity, but in the rabbit an open connection is retained.

c. At the anterior end of the white, elongated *testis* is a mass of convoluted tubules, the *head* of the *epididymis*. This is homologous to the tubules of the anterior end of the mesonephros. The *body* of the epididymis passes posteriorly along the dorsal wall of the testis, and forms another mass, the *tail*, at the posterior end of the organ. To the latter portion is attached the gubernaculum.

d. The testis is supported dorsally by the *mesorchium*, and posteriorly by the *gubernaculum*, homologous respectively with the broad and round ligaments of the uterus.

e. Along the base of the mesorchium is the large white *vas deferens*. Trace this to the posterior end of the testis, where it originates as a continuation of the epididymis. Running parallel with the vas deferens are nerves and blood vessels, the whole composing the *spermatic cord*.

f. From the anterior end of the testis, note the blood vessels extending craniad. With these is the *cremaster* muscle forming part of the sheath of the spermatic cord.

g. Trace the spermatic cord anteriorly. It soon penetrates the abdominal wall through the *inguinal canal*. The outer and inner openings of this are known respectively as the *external* and *internal inguinal rings*.

h. The vasa deferentia pass ventral to the ureters near the point where the latter enter the bladder.

i. Now cut through the pubic and ischial symphyses, using a stout scalpel and being careful not to injure any underlying structures. Exerting some pressure, spread the legs apart.

j. In the RABBIT cut the ureters and raise the bladder. The vasa deferentia will be seen extending posteriorly, dorsal to the median *urethra*. The vasa enlarge and pass into the large sac-like *seminal vesicle*, which pouches anteriorly between the rectum and bladder. In most mammals this is paired, and an indication of this can sometimes be seen in the rabbit in the forked condition of the anterior end. Cut the vesicle open, and find the openings of the vasa deferentia, and on its dorsal wall a thickening caused by the *prostate gland*. The *bulbo-urethral* or *Cowper's glands* are situated on either side of the urethra, just posterior to the seminal vesicle, and may be recognized by their light yellow or pinkish color.

k. In the CAT cut the ureters and raise the bladder to follow the vasa deferentia. These pass posteriorly beside the urethra, finally entering the latter near an enlargement. Dorsal to this enlargement is a gland that wraps itself around the sides of the urethra. This is the *prostate gland*. Slightly distal to this, in the angle between the urethra and the attachments of the penis to the pelvis, is a pair of rounded glands about the

size of a pea, the *bulbo-urethral* or *Cowper's glands*. The seminal vesicle is absent in the cat.

l. The *semen* is a rather viscid fluid containing the sperm cells. The fluid is secreted by the testis, seminal vesicles (if present), the prostate and bulbo-urethral glands.

m. Make a cross-section of the penis. Locate the urethra. The tissue immediately surrounding the urethra is the *corpus cavernosum urethrae* (corpus spongiosum) which expands distally to form the glans. Dorsal to this are the *corpora cavernosa* which lie close together in the distal part of the penis and slightly separated proximally. These cavernous bodies are very vascular, consisting in most part of sinus-like expansions of the blood vessels. When these cavities become filled with blood the penis becomes erected. In the cat an *os penis*, a small sliver of bone, will be seen just dorsal to the corpus cavernosum urethrae.

n. Make a longitudinal section of the testis to observe the arrangement of the tubules, in the walls of which the sperm cells develop. The interstitial tissue lies between the tubules.

3. The Female.

a. The parts of the external genitalia were noted in connection with the external anatomy (page 111). Within the *labia majora*, locate the *labia minora*. Beginning between the ventral limits of these, slit the skin ventrally. Carefully separate the sides of the incision, and in the underlying connective tissue expose the elongate *clitoris*. The free distal end of this is the *glans* of the clitoris (glans clitoridis). Trace the organ to where it is attached by ligaments to the ischium and the symphysis of the pubis. With what structure in the male is the glans clitoridis homologous?

b. The *ovaries* are small light-brown bodies, situated lateral to the kidneys, and at the level of the posterior limit of the left one. Each will probably show minute clear vesicles, the *Graafian follicles*, each of which contains an ovum. In a pregnant specimen, there will be very hard dark spots on the ovary. These are the *corpora lutea*, and are composed of a mass of pigmented cells that have filled the depression left by the rupture of the follicle. The ovary is supported by a mesentery, the *mesovarium*.

c. Near the ovary will be found the coiled *Fallopian (uterine) tube.* From what did this arise embryologically? The opening of this tube, the *ostium,* lies anterior to the ovary, and has fringes or *fimbriae* on its border. The Fallopian tube is supported by the *mesosalpinx,* the anterior portion of which forms a sort of hood over the ovary.

d. The Fallopian tube widens to form the *uterus.* The size of this varies; in virgin females there is a relatively small increase in size over that of the uterine tube, while in pregnant ones or those that have been pregnant, there is a great enlargement. In the RABBIT there are two separate uteri, each opening into the vagina, a condition called the *duplex uterus.* In the CAT the Müllerian ducts are fused before entering the vagina. The lateral separated portions of the uterus are called the "horns" or *cornua,* and the uterus as a whole is called a *bipartite uterus.*

e. The strong fold supporting the uterus is the *mesometrium.* The mesovarium, mesosalpinx, and mesometrium together make up the *broad ligament* of the uterus. The *round ligament* is a fold extending from the beginning of the uterus to the lateral body wall. It is continuous with, but at right angles to, the broad ligament.

f. Using a stout scalpel, cut through the pubic and ischial symphyses. Be careful not to destroy any of the underlying structures. Exerting some pressure, spread the legs apart so that the urinogenital structures can be traced through the pelvis.

g. The uterus empties into the *vagina.* In the rabbit there are two openings, in the cat but one .

h. Trace the *urethra* posteriorly. It lies ventral to the vagina, quite closely bound to it with connective tissue. Separate the two structures with the back of a scalpel and find where the two tubes join.

i. Make an incision along the vagina from the uterus to the external opening. Note the junction of the uterus (two uteri in the rabbit) with the vagina. The end of the uterus is called the *cervix.* Note how it projects into the vagina as a fold. The opening of the uterus into the vagina is called the *external uterine orifice.* By searching along the opened tube find the opening of the urethra into its ventral floor. Just craniad to the opening of the urethra there is a visible change in the

character of the wall. This marks the caudad end of the vagina; the connection with the outside, into which the urethra opens, is called the *vestibule*. In the rabbit the vestibule is very long and in the cat rather typical in length. In the human the vestibule is eliminated as a tube, the urethra and vagina having separate openings between the labia minora.

4. Kidney.

a. Remove a kidney, together with an inch of the blood vessels and ureter. Make a sagittal section, cutting as nearly as possible through the center of the hilum and the ureter.

b. The expanded end of the ureter within the kidney is the *pelvis*. Projecting into this will be found the single *papilla*. Radiating outward from the latter is a collection of minute tubules, the *pyramid*. The outer part of the kidney, the *cortex*, contains the glomeruli and the vascular part of the tubules. The inner portion, the *medulla*, contains the straight converging collecting tubules. In man there are about twelve pyramids and papillae, although there is only one in the rabbit and cat.

F. Structure of the Gonads

1. Mammalian Testis.

a. *Discussion.* The internal structure of the testis, the gross relationships of which have been seen in the dissection, can be studied only under the microscope. The testis is covered with a heavy layer of connective tissue which extends into the testis and divides it into *lobules*. The main mass of the testis is composed of *seminiferous tubules*, in the walls of which the sperm cells develop. The greater part of each tubule is coiled, the distal portion being straight. In the connective tissue sheet covering the testis, near the head of the epididymis, these straight tubules anastomose, forming the *rete testis*. The tubules then empty into the tubules of the epididymis. The latter are eight to fifteen in number in man. The epididymis empties into the *vas deferens*. The seminiferous tubules are separated from each other by connective tissue which is continuous with that between lobules. Associated with this tissue are large cells, the *interstitial cells*, which produce the internal secretion controlling the production of secondary sexual characters.

b. Study a section of testis. Such sections often do not show the epididymis, but contain only the sperm-forming region of the gonad.

c. The *lobules* may not show clearly, depending on the size and angle of the section.

d. The *seminiferous tubules* are the most apparent structures in the testis. If a tubule is seen in cross-section it is in the form of a circular mass with an opening in the center. Many other shapes will be present, due to the fact that the tubules are cut at various angles. What is the appearance of a duct cut longitudinally? Select a tubule that was cut at right angles and place it under high power.

e. Around the outside of the tubule is a compact layer, the *basement membrane*. Outside of this, between the tubule and adjacent ones may be seen *interstitial connective tissue*.

f. The cells of the tubule are of two types: (1) Most of the cells are *spermatogenic* or sperm-forming cells. (2) Near the periphery, on careful observation, large pyramidal cells, the *cells of Sertoli*, will be seen. To them may be seen attached smaller developing sperm cells. The cells of Sertoli pass food materials to the more specialized developing sperm, and also suspend them in position.

g. Observe the spermatogenic cells. These are in various stages of maturation, and their nuclei will vary from a very delicate network of fine threads to a compact mass. The cells nearest the *lumen* or duct are the closest to maturity. Extending into the lumen delicate, darkly stained threads may often be seen. These are the tails of the spermatozoa. Within the lumen fully developed *sperm cells* will sometimes be seen. They are characterized by a very deeply staining spindle-shaped anterior end and a filamentous tail which also takes a heavy stain.

h. Turn to the connective tissue between tubules. Follow this to find the large rounded *interstitial cells*, which produce an internal secretion.

2. The Mammalian Ovary.

a. *Discussion.* The ovary is covered on the outside by peritoneum. At the point where it is attached, the tissues of the broad ligament extend into the ovary, forming the connective

tissue *stroma* which supports the softer parts. The peritoneal covering is highly modified. Its connective tissues penetrate the surface and are continuous with the stroma. Its mesothelium is modified into cuboidal cells forming the *germinal epithelium*, so named because of its supposed function of producing future ova. In development, cells appear in this epithelium, and then, as part of a string-like mass, grow into the stroma. This *germ cord* then breaks, leaving a mass of cells deeply embedded within the ovary One of these becomes enlarged, the others multiplying and forming a thick capsule or follicle around the developing egg. Soon a liquid-filled space develops within the mass, the ovum remaining attached to the wall of the follicle. As the entire follicle and the egg become larger, the tissue between the follicle and the wall of the ovary becomes thinner and thinner. It finally ruptures, liberating the liquid which washes away the egg. The latter is then picked up by the oviduct. Early maturation of the ovum takes place before or soon after birth, before the egg grows into the center of the ovary. There follows a long rest period, and final maturation takes place just before the egg is liberated.

b. Study a section of an ovary. Use low power.

c. Within the ovary, some distance from the periphery, will be seen large spaces, the *Graafian follicles*. These will be described in more detail below. Near the surface will be seen many smaller cells which are characterized by a large amount of cytoplasm and their greater size than the cells by which they are immediately surrounded. These are *rudimentary ova*. They have undergone early maturation, but have not increased markedly in size nor grown into the middle of the ovary. The connective tissue stroma will be apparent as the large masses of fibers extending throughout the ovary.

d. Select a Graafian follicle in which the cavity is large, and where the *ovum* with its nucleus shows in the section. The ovum is attached by a stalk to one side of the follicle. Place the follicle under high power of the microscope.

e. The ovum is spherical, and in its approximate center is the large nucleus, or *germinal vesicle*. Within the latter is a deeply staining spot, the nucleolus. Immediately surrounding the ovum is a clear area (zona pellucida) perforated by minute

canals. Just outside of this is a layer of columnar cells (zona radiata), processes from which pass through the canals of the clear area and carry nourishment to the egg cell. These two layers, enclosing and supporting the ovum, are attached to the side of the follicle by the *germ hill* (discus proligerus).

f. The space within the follicle (follicular cavity) is filled with a liquid (liquor folliculi) which coagulates during the preparation of the slides and appears in the section as a granular mass.

g. The cells of the follicle next to the cavity (membrana granulosa) are characterized by their granular appearance. Outside of this the stroma of the ovary forms a heavy layer of connective tissue around the follicle, thus forming a capsule in which the follicle is supported.

h. Along the periphery of the ovary a few *egg cords* may usually be seen. Each is a mass of tissue extending toward the interior of the organ. Enclosed within the mass will be rudimentary ova. At a later stage this mass would grow further into the stroma and then lose its connection with the periphery. It would then develop into a typical follicle.

i. Remnants of *corpora lutea* may usually be seen. The cells have a small nucleus, with a relatively large amount of weakly staining cytoplasm. Large numbers of these cells are packed closely together. The corpus luteum is a mass of tissue which fills the space left within the follicle after ovulation. It is thought to have an internal secretion affecting the secondary sexual characters of the female.

PART XII

NERVOUS SYSTEM

A. Development

1. Slides of the developing chick are used, and it must be remembered that the section includes only the *blastoderm*, or germinal part that lies on top of the yolk. This type of development is true of all large-yolked eggs. The general plan of the development of the nervous system is the same in both meroblastic and holoblastic ova.

As early as the eighteenth hour the nervous system has begun to develop. The embryo, which at this stage is a flat plate of cells spread out on the yolk, has the three layers present (endoderm, mesoderm, and ectoderm). Down the center a thickening shows the line of the *notochord*, and on either side of it the thickened ectoderm has begun to rise in parallel folds. This is the *neural plate*. From then on the nervous system develops rapidly. The lateral folds rise on either side and grow toward the dorsal median line. At twenty-four hours the deep *neural groove* extends nearly the entire length of the body, and is nearly closed in the head region. It is important to remember that development proceeds from anterior to posterior, and several stages of development may be studied in the same embryo. When the anterior end of the tube is closed, the head end begins expansion, though there is at first no differentiation between the brain and the nerve cord. At twenty-eight hours of incubation the three divisions of the brain are faintly indicated, with enlargements which will form the *optic vesicles*. At forty-eight hours the three divisions are very distinct, and the eye and ear are laid down.

2. Thirty-Three Hour Chick: Total Mount. The embryo is mounted whole, and the slide is very thick. Therefore, *do not use high power*. Study with a good hand lens or with the *low* power of the microscope.

a. Locate the anterior end of the embryo, and note the extra-

embryonic tissue surrounding the centrally placed embryonic tissue.

b. Extending down the mid-line is the brain and nerve cord, which are closed for most of their distance, only the posterior end being an open groove.

c. Locate the anterior *brain*, which is approximately one-third the length of the embryo. It is divided into three parts by two constrictions, the last part (*hindbrain*) passing into the nerve cord.

d. The most anterior portion, the *forebrain*, or *prosencephalon*, is the largest part with large evaginations extending laterally. These are the *optic vesicles* which give rise to the eyes. On the dorsal surface a smaller evagination can be made out by focussing upward. This pocket is the anlage of the *cerebral hemispheres*.

e. The *midbrain* or *mesencephalon* is about as long as the forebrain, but narrower. It gives rise to the *optic lobes*, the brain center of the eye. The fibers of the optic nerve pass back to it as they develop.

f. The *hindbrain* or *rhombencephalon* is the posterior part, and several smaller constrictions can be seen in it. This part of the brain is long and narrow in the embryo of this age. The anterior part of the hindbrain develops into the *cerebellum*, the posterior portion into the *medulla*.

g. The closed nerve cord extends posteriorly from the hindbrain. Near the posterior fourth of the embryo the neural folds can be seen to separate, the groove between widening as they pass caudad.

h. The *notochord*, an endodermal structure, is clear in the region where the neural folds are wide apart.

i. On either side of the neural tube are the *mesodermal somites*, which appear as regular blocks of tissue. The typical number is twelve pairs for the 33-hour chick.

j. In the anterior third of the embryo locate the bulbous *heart* and *vitelline veins*. As these are ventrally located, focus down to observe them. Follow the veins out into the extra-embryonic tissue where they spread to form numerous capillaries.

3. Thirty-Three Hour Chick: Serial Sections.

a. The embryo at 33 hours is so large that the sections cover two or three slides. *Low power* will show most of the neces-

sary structures; but if high power is required use great care, as the destruction of one slide ruins the entire set.

b. In the extreme posterior region find a section with the *neural groove* open. The upper layer is the ectoderm. Immediately below the neural groove is the *notochord*, with the endoderm stretching as a thin sheet below. Between the two layers observe the mesoderm extending laterally from the notochord.

c. More anteriorly find a section showing the groove nearly closed. The structures will be present as in "b".

d. Still more anteriorly note that the groove has closed to form a tube, the neural tube. Is the mesoderm different from the first section? The tube may have become separated from the ectoderm above. At the point where the dorsal edge of the tube is in contact with the inner side of the dorsal ectoderm, find a small knot of cells. This is the *neural crest* from which will develop the dorsal ganglia of the peripheral nerves. At a slightly later stage the single neural crest divides and each portion will be found laterad to the dorsal portion of the neural tube. When the large ventral *heart* is found, observe its structure. Compare its position with the total mount.

e. In the anterior region locate a section through the head. The head has become folded from the yolk sac, and will be circular in shape with the ectoderm completely surrounding the embryo. The thick layer forming the brain will be in three pockets, one dorsal (the cavity of the forebrain) and two extending laterally, the *optic vesicles*.

f. The four sections studied will give an idea of the development of the nerve tube as the embryo grows. Study as many structures as you can, and mentally reconstruct the embryo from the cross-sections.

4. Forty-Eight Hour Chick: Total Mount.

a. The brain will be the most prominent structure in the embryo. Observe that it is completely doubled on itself, due to the bending, or *flexures*, of the embryonic nerve cord. There are three of these flexures, the first through the midbrain, the *cervical flexure*, which bends the forebrain at right angles to the primitive axis. The second bends the brain at the base of the medulla, carrying the forebrain farther forward. The

48-hour chick is at this stage of development. The third is the *pontine* flexure, through the hindbrain, and carries the forebrain back toward the antero-posterior axis.

b. In addition to the flexures, the brain changes its position due to the turning of the embryo onto its side. The 48-hour chick has not completed this *torsion*, or turning movement. These two movements have placed the *midbrain* in the most anterior position of the embryo, with its right side upward. It is separated from the hindbrain by a definite constriction.

c. The *forebrain* should be studied first after the location of the parts. A very slight constriction divides the forebrain into two parts, the anterior *telencephalon* and the more posterior *diencephalon*. The *optic vesicles* are prominent, and are now invaginated distally to form an *optic cup*. Within the cup is the *lens*, which is a thickening of the skin ectoderm, and not a part of the brain outpocketing.

d. The *hindbrain* lies almost touching the forebrain. Lying over the hindbrain, almost opposite the eye, is the ring-shaped *auditory pit*. It is an ectodermal inpocketing from the outer part of the embryo, and not an evagination from the brain.

e. Trace the nerve cord posteriorly.

f. The following structures can be easily identified:

(1) The mesodermal somites on either side.

(2) The *vitelline arteries* from the embryo to the yolk mass are about one-third the length from the posterior end. The *vitelline veins* from the yolk to the heart are at the level of the anterior third.

(3) The heart lies between the right vitelline vein and the forebrain.

(4) The visceral openings (gill slits) are between the heart and the hindbrain.

(5) Just anterior to the arteries will be seen a fold of tissue forming an arch with its crest pointed craniad. This is the fold of the *amnion*, which now incompletely covers the embryo.

B. Inner Ear of the Dogfish

1. Remove the skin of the head, clearing away the muscle and connective tissue until the cartilage of the skull is exposed in the region posterior and dorsal to the eye. Be careful not to injure

the brain which lies in the median line. Begin $\frac{1}{4}$ inch lateral to the endolymphatic fossa, and shave away the cartilage. In this region lie the *vertical canals* of the *inner ear*. Clear lines in the cartilage in a V-shape will soon appear with the apex near the endolymphatic fossa. When the canals can be seen through the cartilage, begin on the anterior canal, and carefully cut away the cartilage until the transparent tubular structure appears. Work toward the apex, and then clear the *posterior* canal, which is at right angles to the first. Between the two vertical canals lies the cavity of the inner ear. Do not injure this central structure. Then work toward the ventral limit of the two vertical canals, watching closely for the *horizontal canal* and the *ampullae*, or bulbs which lie at the junctures of the canals. Leave the organs embedded in the chondrocranium, but dissect away the cartilage until all parts are exposed to view.

a. Each canal terminates in a rounded sac, the *ampulla*. The space between the canal and the walls of the cavity in which it lies is filled with a liquid, *perilymph*, which acts as a medium in which floats the delicate canal. Both ends of the semicircular canal end in the cavity or *vestibule*.

b. This vestibule is divided into two parts: the larger dorsal cavity, the *utriculus;* and the smaller ventral *sacculus*, embedded in a pit in the cartilage.

c. Insert a human or horse hair into the endolymphatic and perilymphatic ducts. Note that the endolymphatic duct leads into the sacculus, while the perilymphatic duct leads to the space between the sacculus, and the surrounding cartilage.

d. The ampullae of the anterior vertical and the horizontal ducts are in communication with each other and with the utriculus. The ampulla of the posterior vertical duct is ventral to the horizontal duct and also communicates with the utriculus. Since the endolymphatic duct opens into the sacculus (an outpocketing of the utriculus) the whole vestibule and the three ducts are in communication with each other, and with the exterior. This entire system is filled with the endolymphatic fluid. The whole structure is floated in perilymph.

e. In the sacculus is always a rounded concretion, or *otolith*, although in formalin specimens this may have been dissolved. It aids in maintaining equilibrium. How?

f. On the side of each ampulla may be seen a white opaque area. From this may be traced branches of the eighth nerve. This sensory patch is termed the *crista.*

g. Changes of pressure of water on the surface of the head, due either to vibrations or change in position, are conducted to the inner ear through the endolymphatic duct. It appears that either, or both, the ampullae and the vestibule control equilibrium. Perception of vibrations (hearing) is presumably restricted to the vestibule.

C. Eye of the Dogfish

1. Musculature of the Eye.

a. This dissection must be performed on the same side that was used for the inner ear. Loosen and remove the remaining skin around the eye, and on the dorsal side cut away the cartilage of the supraorbital ridge, taking care not to injure the brain cavity, or the nerves passing to the eye.

b. On the dorsal surface of the eye will be seen two muscles. (1) The more anterior is the *superior oblique.* This inserts on the dorsal part of the eye, and can be traced to its origin on the anterior part of the orbit. The *fourth nerve* from the brain will be found passing through its foramen in the chondrocranium, and spreading out on the muscle. Passing longitudinally across the dorsal part of the orbit is a large branch of the fifth and seventh nerves. (2) The *superior rectus* inserts near the former, and passes caudo-ventrally to its origin. It is innervated by a branch of the *third nerve.* Carefully depress the eye capsule and note that at the point of origin there are three other eye muscle origins. These are the other rectus muscles.

c. Remove the superior rectus and pull the inner surface of the eye outward. This exposes the other rectus muscles. The anterior is the *internal rectus* and the ventral is the *inferior rectus,* both innervated by the third nerve, which is a small nerve passing from the chondrocranium to the eye. (The deep ophthalmic, a branch of the fifth, may be confused with the third.)

d. The posterior muscle is the *external rectus,* arising with the others, and inserting on the eye. It is innervated by the sixth nerve.

e. Cut the superior oblique and observe the *inferior oblique* which arises with the former, and passes to the ventral side of the eye. It is innervated by the third nerve.

f. Before removing the eye, locate the *optic nerve* which enters the eye in its anterior ventral part.

g. The eye muscles arise as three small muscle segments of the embryo, each innervated by a single nerve. One segment splits to form four of the muscles, carrying its nerve with it. This accounts for the peculiar innervation of the optic muscles.

2. Cross-Section of the Eye.

a. Cut the muscles of the eye and remove it from the orbit. Do not pull the eye, but lift it by the muscles, clipping any connecting strands of tissue.

b. Within the orbit are the large *maxillary* and *mandibular* branches of the fifth and seventh nerves.

c. In removing the eye the *pedicel*, a cartilaginous structure supporting the eye, will probably have been broken. This is attached to the chondrocranium and may have been identified when the skeleton was studied.

d. Study the outer surface of the eye. Notice the central clear *pupil* with the pigmented *iris* surrounding it. More peripherally is the clearer portion which is the "white" of the eye. This is darker than it appears in the living specimen. The outer covering of the eye is the *sclera*, which developed from the optic capsule. In some animals (reptiles and birds) this layer may become ossified, but never fuses with the chondrocranium. Locate the exit of the *optic nerve*.

e. Place the eye under water, and using a sharp safety razor blade make an incision through the pedicel and optic nerve. Carry the incision to the *crystalline lens*, almost bisecting the eye.

f. The large inner cavity, posterior to the lens, is filled during life with a gelatinous fluid, the *vitreous body*.

g. The inner layer of the wall in contact with the vitreous body is the *retina*, a yellowish white membrane, which contains the nerve cells and nerve endings. How far around the eye does it extend? Is it firmly attached at the region of the optic nerve? The nerve fibers from the retinal cells collect in this region and pass out into the nerve.

h. Outside the retina is the black *choroid membrane.* What is the advantage of the pigment? Under the influence of strong light the pigment cells enlarge, surrounding the nerve cells. On the front of the eye this membrane is continued as a shelf forming the iris.

i. The outer covering of the eye is the mesodermal covering, the sclerotic layer, which has been identified.

j. Over the iris and pupil is the *cornea,* a transparent membrane composed of mesoderm and ectoderm. The mesodermal part is continuous with the sclera, and the ectodermal portion is continuous with the epidermal epithelium of the rudimentary lids. The epidermis of the cornea in amphibia and many reptiles is shed when the skin is cast. The mesodermal part of the cornea remains intact.

k. Between the cornea and lens is another cavity, the *anterior chamber* filled with the *aqueous humor.*

l. The *lens* is attached to the wall of the eye by suspensory ligaments from the ciliary processes. These ligaments are attached just behind the iris.

D. Nervous System of the Dogfish

1. General Description.

a. Review the description of the gross anatomy of the dogfish brain as given in Part II, page 11.

b. Skin the head, and then carefully shave away the cartilage of the chondrocranium until the brain is exposed. Recall that the foramen of Nerve IV lies in the extreme dorsal part of the orbit; therefore great care must be exercised not to injure this very delicate nerve.

c. In the median line, and at the level of the anterior border of the eye, find the *epiphyseal foramen.* A tube of tissue, a little expanded at the end, leads from the thin-walled *diencephalon* to this opening. This is the *epiphysis* or *pineal organ.*

d. Continue the dissection posteriorly until the dorsal surface of the entire brain and an inch or two of the spinal cord are exposed. Wash away any coagulated lymph that may be collected in the cavities.

e. Identify the parts of the brain:

(1) The forebrain with the anteriorly projecting *olfactory nerves,* noting that the forebrain is now divided into an

anterior *telencephalon* containing the *cerebrum*, and a thin-walled *diencephalon*. Observe the vascular covering of the diencephalon before it is destroyed.

(2) The large *optic lobes* which developed from the *mesencephalon*.

(3) The hindbrain which is divided into a large *cerebellum* and a narrow *medulla*.

f. The *spinal cord*, which is included with the brain as the *central nervous system*, is a continuation of the medulla.

g. The mesodermal coverings of the brain are relatively simple in the dogfish. These *meninges* are divided into three parts in the mammal, but in the *dogfish* there is a single *meninx primitiva*. This closely covers the brain, being separated by a fluid-filled space from the endochondral covering of the chondrocranium. The meninx is continued into the neural arch, surrounding the spinal cord.

2. Cranial Nerves.

a. Nerve I. *Olfactory.*

The true olfactory nerves of the dogfish are very short. In the most anterior part of the cranial cavity are the *olfactory tracts* which connect the telencephalon with the terminal *olfactory bulbs*. The bulbs are really an extension of the brain out to the nasal sacs which surround the capsules. The short nerves pass from the epithelium of the nasal sac to the bulb, which is closely opposed to it. Cut open the nasal sac and observe its highly corrugated surface, and the numerous nerves passing from the epithelium to the bulb. On the median side of each olfactory tract is a small *terminal nerve*. This nerve arises separately from the olfactory nerve, but is considered by some anatomists as a part of the olfactory tract.

b. Nerve II. *Optic.*

The optic nerves extend as thick white cords from the eyes to the optic lobes. They may be located at the bottom of the orbit between the eye and the skull, under the superior oblique muscles. Within the cranial cavity they may be seen in dorsal view at the level of the diencephalon. They cross on the ventral surface of the brain as a *chiasma*, which will be studied later. The optic nerves are sensory, passing from the retina through the optic stalk to the brain.

c. Nerve IV. *Patheticus* (*Trochlear*).
The fourth nerve arises on the dorsal side of the brain at the posterior side of the optic lobe. It is a delicate thread piercing the lateral wall of the orbit, dorsal to the optic nerve, and passing outward to innervate the superior oblique muscle of the eye. Again trace its course from the optic lobe to its point of termination.

d. Nerve III. *Oculomotor.*
By cutting the fourth nerve and slightly lifting the brain, the origin of the third nerve will be seen on the ventral surface of the midbrain. It penetrates the orbit as a fair-sized nerve at the level of the rectus muscles. It immediately divides into three branches, two of which innervate the internal and superior recti, and the ventral branch going to the inferior rectus and the inferior oblique. Recall the origin of the eye muscles, and correlate with these nerves.

e. Nerve VI. *Abducens.*
This nerve supplies the posterior (external) rectus muscle. It is a very delicate thread, and will be identified when the brain is removed. Its termination on the eye muscles can be followed in the orbit.

f. Nerve V. *Trigeminal.*
The fifth arises on the medulla, in close contact with the seventh (Facial) nerve. Within the chondrocranium it can be seen as a large nerve mass at the posterior level of the orbit. Connected with its roots is a large ganglion, the *Gasserian ganglion.* The nerve is mixed, carrying both sensory and motor fibers. It splits into three main branches which pass into the orbit:

(1) The *superficial ophthalmic* passes anteriorly above the eye muscles. This nerve contains a large branch of the seventh nerve. It branches profusely, and is distributed to the sensory organs of the dorsal and lateral surface of the snout. A branch of the ophthalmic, the *deep ophthalmic,* is a comparatively slender nerve passing below the superficial, between the superior and posterior rectus muscles, and forward along the medial surface of the eye. It supplies the region of the snout after giving off the *ciliary* nerves to the eyeball.

(2) The *maxillary* branch crosses the floor of the orbit as a

broad, strap-like nerve, carrying with it a branch of the facial nerve. The two nerves remain associated even in the small branches. Near the anterior edge of the orbit it branches into three, and ends in the skin of the upper jaw.

(3) The *mandibular* branch arises beneath and behind the maxillary. It runs outward, posterior to the latter, and turns downward into the lower jaw. It should be traced as far as possible.

g. Nerve VII. *Facial.*

The ganglia of the seventh lie in such close contact with the Gasserian that the origin of the nerve on the medulla cannot be separated by the student. The two nerves intermingle for much of their distance in many of their branches, but are distinct in origin. In mammals there is a clearer differentiation of the nerves. The *ophthalmic* branch has been described in connection with the similarly distributed branch of the fifth nerve. A small *palatine* branch is associated with the maxillary branch of the fifth, and is distributed to the roof of the mouth. The *hyoidean* branch may be found immediately under the skin, posterior to the spiracle. The hyoidean supplies the skin and muscles of this region. This branch should be traced back to its exit from the cranium.

h. Nerve VIII. *Auditory.*

The auditory nerve arises on the medulla, close to the fifth and seventh. Portions of it were seen when the ear was dissected. This nerve is sensory in function, its branches spreading over the internal ear.

i. Nerve IX. *Glossopharyngeal.*

The nerve arises near the eighth. In locating the ninth nerve, watch carefully for the tenth. Recall that in the chondrocranium the foramen of the ninth is at the posterior angle, and the tenth is near the foramen magnum. The nerve takes a caudo-lateral direction through the posterior part of the otic capsule toward the first gill cleft. Where it leaves the foramen there is a ganglion (the *petrosal* ganglion), the nerve immediately splitting into two branches. The smaller anterior part is the *pretrematic*, and the posterior is the *post-trematic* branch. The nerve is mixed, supplying the first gill.

j. Nerve X. *Vagus.*
The vagus arises by several small roots posterior and mediad to the former, and has probably been uncovered in dissecting that nerve. Where it leaves the chondrocranium two main branches will be found. Pull the skin from the sides of the body and over the gills, and make an incision posteriorly from the *lateral* branch of the vagus. This will open the anterior cardinal sinus which lies just above the gills, and the nerve can be followed. Branches are given off to each gill except the first. The nerve is continued to the viscera. Now trace the *median* branch of the vagus. Cut into the muscle tissue, avoiding the nerve itself. At the level of the first gill *slit* the nerve turns sharply mediad and ventrad. Continue the incision, following the nerve. Near the pectoral girdle it becomes deeper but follows the *lateral line* to the end of the body. The nerve follows the horizontal septum between the hypaxial and epaxial muscles.

3. Spinal Nerves.

a. Where the incision has been made between the dorsal and ventral muscles in following the vagus, the spinal nerves can be located. Carefully lift the epaxial group and the nerves will be seen crossing under the vagus, almost at right angles.

b. Select a nerve and follow it dorsad. This is the *somatic branch* of a spinal nerve. Remove the tissue as you advance. *Do not tear* the muscles out, as other nerves will probably be needed for dissection. Clear the nerve up to the vertebral column. Two roots are easily distinguishable, the fusion being well outside the vertebrae in the dogfish. The *dorsal sensory* root is the more anterior, and can be found entering the intervertebral plate of the neural arch. (See Part II, Section B, page 13.) The *ventral motor root* has a wider origin from the nerve cord. The spinal nerves are metameric, passing to the body and giving off small branches to the *sympathetic* system. These *communicating rami* will probably not be seen. The *somatic* branch of the nerve splits, a smaller branch going to the epaxial muscles, and a larger to the hypaxial. In the region of the fins there are large *plexuses* of spinal nerves. The pectoral group can be found by locating the hypaxial rami of the nerves immediately dorsal to the fin and lifting

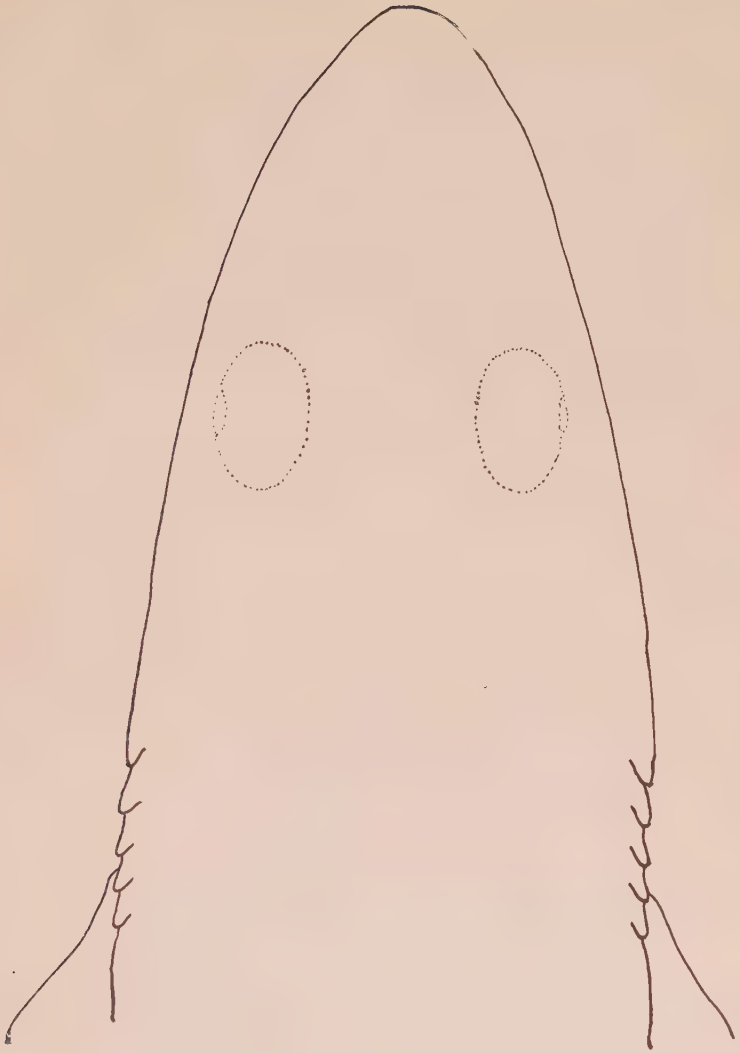

PLATE 19. Outline of the head of Squalus, for drawing of the brain and cranial nerves. Indicate the position of the chondrocranium and draw the nerves in position.

the tissue back. The nerves lie next the peritoneum, and several will be seen to converge near the posterior border of the pectoral fin.

4. Ventral Surface of the Brain.

a. After dissecting the cranial nerves the brain may be removed. Cut the spinal cord posterior to the vagus nerve, and also cut the roots of the cranial nerves, leaving the stumps as long as possible. Be careful not to injure the olfactory bulbs and the structures of the ventral side of the brain.

b. Identify the roots of the cranial nerves.

c. Trace the optic nerves to their point of juncture beneath the diencephalon, forming the *optic chiasma* previously mentioned. There is a complete crossing in the dogfish, the fibers of one eye crossing to the opposite side of the brain. From the chiasma the optic tracts sweep backward to the *optic lobes*. Though the eye arises from the forebrain, the brain center is in the mesencephalon.

d. Immediately behind the optic chiasma are two rounded *mammillary bodies*. Between them is a sac-like extension arising from the diencephalon. This is the *hypophysis*, a ventral outpocketing from the brain. In the adult the stalk is the *infundibulum*, and the expansion at the end is the *pituitary body*. This is a gland of internal secretion, and has a double embryonic origin, though it is entirely ectodermal.

e. At the base of the *cerebellum* are anterior prolongations of the medulla, the *restiform bodies*. The covering of the medulla is very thin, and was probably destroyed.

5. Hemisected Brain.

a. With a sharp scalpel split the entire brain along the median line, exposing the ventricles.

b. Note first the *third ventricle*, the cavity of the diencephalon. From this the *lateral ventricles* extend into the more anterior *cerebral hemispheres*. The dorsal wall is very thin, is non-nervous, and is called the *pallium* of the hemispheres. This should be compared later with the cerebral hemispheres of the mammal. From the lateral ventricles are anterior extensions into the olfactory lobes.

c. The third ventricle merges into the cavity of the optic lobes, and then narrows to form the *iter*, or *aqueduct of Sylvius*.

d. The cavity of the medulla is the *fourth ventricle* which opens from the iter, and is continuous with the *central canal* of the spinal cord. The entire cavity of the brain and cord are continuous, and constitute the *neurocoel.*

E. Nervous System of the Bird (Pigeon)

1. Dorsal Surface of the Brain.

a. With heavy scissors and a cartilage knife remove the bones of the skull, beginning at the juncture of the frontals and parietals. The skull is thin at this point, and in young birds a diamond-shaped opening is present, the *fontanel,* where the dermal bones have not quite fused. Is a similar fontanel present in young humans? Work anteriorly until the large *cerebral hemispheres* are uncovered; then remove the spongy bone covering the posterior part of the brain.

b. Lying close to the bones is the *dura mater,* a heavy brain *meninx* which developed from the outer part of the meninx primitiva found in the dogfish. Closer to the brain, following each of its folds, is the *pia mater,* or inner layer of the meninges. The two developed by a splitting of the primitive meninx.

c. Uncover the eye and observe the muscle attachments. Remove both eyes to facilitate dissection, but preserve both for further study.

d. With the brain in place identify:

(1) The very small anterior *olfactory lobes,* which can be seen to better advantage when the brain is removed.

(2) The large, smooth *cerebral hemispheres,* the most prominent division of the brain. The increased growth is due to the enlargement of the ventral nuclei, the corpora striata. The dorsal *pallium* is thin and only slightly nervous, but is now called the *neopallium* to distinguish it from the non-nervous *archipallium.*

(3) In the median line at the posterior border of the cerebral hemispheres is the small *pineal body* which arises from the *epiphysis* of the embryo. The pineal is attached to the *diencephalon* which is covered by other structures.

(4) The *optic lobes* are large and pushed to the lateral sides of the brain. They lie in contact with the cerebrum.

(5) The large, grooved *cerebellum.* Its size is correlated with the motor coördinations required of flight. The

lateral outgrowths of the cerebellum, the *flocculi*, will be identified later.

(6) The *medulla* is short, and passes into the spinal cord. It, with the cerebellum, arises from the hindbrain.

e. The *cranial nerves* are difficult to locate, due to the compactness of the brain. The *optic* nerve can be seen in the orbit, with the branches of the *fifth* and *seventh*. Clear away the otic region, observing the *semicircular canals* which will be exposed and cut, and find the *ninth* and *tenth* (vagus) nerves. The *Amniotes* have *twelve* cranial nerves, but the last two will not be found.

2. Ventral Study of the Brain.

a. Cut away the bone, preserving as much as possible of the cranial nerves, and remove the brain. Cut the spinal cord, and use care in lifting the brain from its case.

b. Locate the parts identified in dorsal view, observing their relationships on the ventral surface.

c. The *optic chiasma* is very prominent, and the nerves can be traced posteriorly to the optic lobes. The chiasma is complete in the bird.

d. In close contact with the optic chiasma are the small *mammillary bodies*, with the *hypophysis* between as a median outpocketing of the brain. The *pituitary gland* was probably destroyed. Recall its double origin, which is true of all vertebrates. The gland has an endocrine function, the anterior lobe influencing bone growth.

e. The roots of the cranial nerves can be identified. Nerves I and II have been located. On the medulla, near the mid-line, are Nerves III, VI, and XII, proceeding from anterior to posterior. Curving under the optic lobe is Nerve IV. Between the fourth and sixth is the root of the large fifth; and passing backward from the fifth, almost in a straight line, are Nerves VII, IX, X, and XI.

3. Hemisected Brain.

a. With a sharp scalpel or razor blade divide the brain in the sagittal plane.

b. The *ventricles* of the brain are difficult to find, as the walls of the *third ventricle* of the diencephalon are pushed in on either side. If the section passes directly through it, its wall can be

distinguished from the cut tissues by its smooth glistening surface. The third ventricle is continued ventrally into the infundibulum. Its anterior wall between the cerebral hemispheres is very thin, being called the *lamina terminalis*. Located in the lamina is a small group of transversely running fibers connecting the lobes, the *anterior commissure*.

c. Passing from the third ventricle is an opening on either half which expands in the cerebral hemisphere as the *lateral ventricle*. The narrow opening is the *foramen of Munro*. Open a window in the pallium to observe the ventricle, and the large brain nucleus (the *corpus striatum*) of the ventral side.

d. The ventricle narrows in the midbrain to form the *iter*, or *aqueduct of Sylvius*. The iter widens in the hindbrain to form the large *fourth ventricle*, which passes into the nerve cord as the small *central canal*.

e. Observe the structure of the *cerebellum*, with the large amount of gray substance which is composed largely of nerve cells. The *white substance* is mostly nerve fibers.

4. Structure of the Eye.

a. Bisect the eye, carrying the incision through the optic nerve. If care is used the lens may be cut without destroying the internal structures.

b. The *sclerotic layer* is heavy, and often shows signs of ossification. Its continuation over the *pupil* of the eye as the *cornea* is apparent.

c. Lying next the sclera is the black pigmented layer, the *choroid layer*, which can be followed to the *iris* which surrounds the circular opening or *pupil*.

d. The *retina* is the yellowish layer lining the cavity of the eyeball and contains the nerve cells.

e. Attached near the optic nerve is the *pecten* which is supposed to have a sensory function. It is a black corrugated structure swinging loose at its distal end within the *vitreous body*.

f. The *lens* is rather small and is attached to the wall by the *ciliary processes*. Observe its elliptical cross-section. The bird has some accommodation to distance and light, but due to their position the eyes cannot focus together on one object.

5. Peripheral Nerves.

a. Skin the dorsal part of the shoulder, loosen the muscles of the girdle, and pull the scapula outward. Remove the connective tissues and near the axilla observe the large *plexus* of nerves.

b. Carefully dissect this *brachial* plexus dorsally, select a spinal nerve and follow its course to the vertebral column. Remove the bone from the dorsal side of the spinal cord, and expose the roots of the nerve.

c. A relatively large *ganglion* will be noticed, which consists of a fusion of both the dorsal ganglion and the *vertebral* ganglion of the *sympathetic system*. The dorsal and ventral roots of the spinal nerve can be separated with a blunt needle.

d. Next displace the viscera and remove the *lungs*. Carefully push the dorsal aorta to one side and notice the numerous branches of the sympathetic nerves. The *vagus* nerve has branches in the region, but are hardly distinguishable. The sympathetic ganglia can be seen from the ventral side between the ribs, and passing from one to the other is a connecting nerve, the *gangliated cord*.

e. Clear the tissue until the spinal nerve previously dissected is seen to connect with the ganglion. The *ramus communicans* is very short, but relationships of the cord and sympathetic system are apparent.

f Note that each spinal nerve has two roots from the cord. The united nerve divides into somatic and visceral branches, the former passing to the body. The visceral branch is the extremely short ramus communicans which passes to the sympathetic vertebral ganglion. This ganglion is in contact with the spinal ganglion in the bird. The vertebral ganglia are connected with each other to form a chain of ganglia, and each sends out nerves to the ganglia of the mesenteries and back to the spinal cord. Thus, each vertebral ganglion is connected with the spinal cord, with the other chain ganglia, and with the deeper sympathetic ganglia of the viscera.

F. Brain of the Mammal

1. Technique. The essential features of the placental brain are identical, and one description is given with notes to explain differences. The brain of the RABBIT is easily removed, but the skull bones of the CAT are heavier. As SHEEP brains can be bought

from any slaughter house for a few cents, hardened in 10% formalin, and kept as permanent study material, this brain is preferable due to its large size and saving of students' time. However, the student should remove the brain of his specimen for comparison, particularly if the rabbit is used.

a. The RABBIT brain can be taken out by removing the skin and muscles from the top of the head and opening the skull with a heavy scalpel. First split the thin nasal region, then pry the frontals and parietals apart. With the handle of an all-steel scalpel carefully widen the cut over the brain, cutting the tissues which adhere to the brain. The skull can then be broken open and the brain removed. If the rabbit is young, the entire skull and brain can be hemisected with a heavy scalpel and the brain removed in halves.

b. The CAT skull will require bone forceps unless the animal is very small. Begin the dissection of the bones at the anterior end, and work posteriorly. When the top of the calvarium is removed the brain can be taken out by cutting the dura mater around the cranial nerves. As the brain is lifted, cut the ventral attachments and save the hypophysis.

c. The brain should be kept moist during study, and must be handled carefully. If the formalin or embalming fluid did not thoroughly infiltrate the brain, it should be hardened in 10% formalin for a day or more before study.

2. Dorsal Surface.

a. In taking the brain from the skull observe the *meninges*. The *meninx primitiva* found in the dogfish was a single structure. In amphibia, reptiles and birds there are two membranes: (1) The *dura mater*, a tough outer covering; and (2) the *pia mater*, the thin inner membrane carrying the blood vessels for the brain. In the mammals the dura is completely fused with the periosteum of the inside of the skull, and the pia mater has split to form the *arachnoid layer*, an extremely thin membrane lying between the pia and dura. The spaces between are fluid filled.

b. The *cerebral hemispheres* are the most prominent structures of the mammal brain. The *pallium* is very thick, with the outer surface a heavy mass of cells. This is a *neopallium*, and in the mammals this coating of cells forms the *cerebral cortex*.

The two hemispheres are separated by the longitudinal fissure into which extends an elongation of the dura mater.

c. The *convolutions* or gyri of the placental brain are important, being definitely correlated with the intelligence of the group. The gyrus is the ridge, separated by the *fissures* or *sulci*. The fissures vary in depth, a few *complete fissures* dividing the hemispheres into definite *lobes*. The *frontal* and *parietal* lobes are distinct in most mammals, but the *occipital* lobe is weakly marked in the lower mammals. The *temporal* lobe lies lateral to the parietal. In the *rabbit* the gyri are very poorly developed.

d. The *cerebellum* is wide and corrugated, lying immediately posterior to the cerebral hemispheres. The median portion is the *vermis*, and is transversely incised. The lateral lobes lie to either side of it, and are homologous with the *flocculi* of the reptiles and birds.

e. Carefully separate the cerebellum from the cerebrum, and observe the midbrain lying under the posterior part of the cerebral hemispheres. The primitive optic lobes are transversely cut in the mammal to form the *corpora quadrigemina*. The anterior lobes are larger and imperfectly separated from the posterior.

f. The *pineal body* lies immediately anterior to the corpora, but can be seen to better advantage in the hemisected specimen.

g. The *medulla*, with its thin dorsal surface covered by the *choroid plexus* of blood vessels, lies posterior to and partly under the cerebellum.

3. Ventral Surface.

a. The olfactory lobes are usually injured in removing the brain. They lie on the anterior ventral surface, projecting forward against the ethmoid bone. In the RABBIT they are more prominent than in the CAT. The olfactory tract can be traced back to about the middle of the cerebral hemisphere, where it ends in the *pyriform lobe*.

b. Mediad to the anterior part of the pyriform lobes is the *optic chiasma*. The optic tracts arise from the diencephalon and midbrain, the nerves uniting at the chiasma. The chiasma of the mammals is incomplete; the fibers of each tract enter both optic nerves as they pass to the retina of the eye. This is correlated with binocular vision.

c. Posterior to the optic chiasma is a rounded median body, the *tuber cinereum*, to which was attached the infundibulum and its terminal *pituitary gland*. The latter are usually destroyed. The small perforation in the tuber cinereum connects directly with the third ventricle.

d. The small *mammillary bodies* lie posterior to the tuber, and are indistinctly separated from it. Near the mid-line, posterior to the mammillary bodies, are the roots of the *third* nerves.

e. Lateral to the third nerves and mammillary bodies are the *cerebral peduncles*. They can be recognized as heavy bundles of fibers extending almost longitudinally, and passing under a large band of transverse fibers. The peduncles form the base of the midbrain, and are fiber tracts passing backward from the cerebral hemispheres. Nerve IV will be found lateral to the peduncles, next the pyriform lobe.

f. The *pons Varolii* has been noted as the band of transverse fibers under the cerebellum. Its fibers pass from the lobes of the cerebellum. At the lateral border of the pons is the large *fifth* nerve; and slightly posterior to it are the roots of the *sixth*, *seventh*, and *eighth*, the sixth being most median.

g. The region posterior to the pons is the *medulla oblongata* (or *medulla*) with the *median ventral fissure* extending its entire length. On either side of the fissure is a heavy band of fibers, the *pyramids*, a somatic motor tract from the brain carrying impulses from the cerebrum to the voluntary muscles. At the base of the medulla there is an almost complete crossing over of the nerves fibers, any such crossing of the fibers being known as a *decussation* of nerves. Lateral to the pyramids are the rounded *olives*, which are nerve nuclei. The roots of Nerves IX, X, XI, and XII lie along the medulla.

4. Hemisected Brain.

a. At the base of the longitudinal fissure of the cerebral hemispheres is the *corpus callosum*, the largest commissure of fibers connecting the two sides of the brain. As each fiber represents a nerve cell in the cerebrum, the size of the corpus callosum indicates the size of the cerebral cortex. At its anterior end the corpus bends sharply downward and is greatly thickened. It thins posteriorly, and is connected with a more ventral tract, the *fornix*. At the point of juncture the two form an

acute angle. The fornix is the fiber tract of the *hippocampal* region of the cerebrum. The hippocampus is a large lateral nucleus of the brain in lower vertebrates, which has been pushed into the interior of the mammal brain by the overgrowth of the cerebral cortex.

b. The other commissures of the brain are very difficult to find in ordinary specimens. The *anterior commissure* is a small cord of fibers immediately anterior to the optic chiasma, and about half way between the base of the brain and the fornix. The large *middle commissure* is posterior to the former, and above the hypophysis. It connects the two sides of the *thalamus*, the nuclei of the diencephalon. The *posterior commissure* is at the anterior part of the base of the corpora quadrigemina.

c. The *ventricles* of the brain can be identified by the smooth, shiny appearance of their uncut surfaces. The *lateral* ventricles are in the cerebral hemispheres. Each connects with the third ventricle by a *foramen of Munro*, which opens into the ventricle. The *third* is in the diencephalon, and surrounds the middle commissure. It, the third ventricle, extends into the hypophysis.

d. The ventricles narrow at the midbrain to form the *iter*, or *aqueduct of Sylvius*, which passes under the corpora quadrigemina. The midbrain is more solid than in lower forms, pressing against the cavity of the brain.

e. The *fourth ventricle* is in the hindbrain, and is very large. Observe that the dorsal wall of the medulla is very thin, and probably collapsed when the spinal fluid was lost. The cavity is continued into the spinal cord as the *central canal.*

f. The *cerebellum* is highly lobulated, with a central core of white tissue. This relationship is typical of the mammals, the numerous lobes giving an increased area of cortical cells.

g. Make a transverse section of one of the cerebral hemispheres. Observe the extent of the corpus callosum; the nuclei of the ventral surface; the lateral ventricle; and the cerebral cortex.

G. Spinal Cord and Nerves of the Mammal

1. Dissection of Nerve Roots.

a. Cut the epaxial muscles of the RABBIT near the last rib. Catch the muscles and pull them craniad, thus exposing the trans-

verse processes of the vertebrae. As the muscles are pulled up, small cord-like nerves will be seen passing from the body muscles toward the vertebrae. These are the *spinal nerves.* Trace one of them by clearing away the muscles and connective tissues to the point where it passes under a transverse process. The process can be broken off with the fingers, and the nerve cleared to the opening between two vertebrae. In the CAT heavy forceps are usually necessary.

b. Carefully lift the nerve and observe two very small nerves passing ventrally from it. These are the *rami communicantes* which connect the central nervous system with the sympathetic system; and which also connect the latter with the sweat and other glands of the skin. These cannot be preserved in the following dissection.

c. With a cartilage knife cut into the neural spine and remove it. Then with heavy forceps or the fingers break off the zygapophyses, exposing the *spinal cord.* Clear the small bits of tissue from the nerve and trace it to its exit from the spinal cord.

d. Observe that the spinal nerve expands as it approaches the cord. Very carefully clear it. Dorsally there is a smooth enlargement, the *dorsal sensory ganglion,* a part of the *dorsal root* of the spinal nerve.

e. Lift the nerve, and note that the *ventral motor root* arises from the cord by numerous nerves. The separation between the two roots exists for only a short distance.

f. With a blunt needle, or small forceps, separate the two roots by slipping the instrument between.

2. Sympathetic Ganglia.

a. Lift the lungs and trachea of the specimen, saving the aorta and larger arteries if they have not been destroyed in previous dissection.

b. Lying against the exposed ribs and vertebrae is a large group of nerves, including sympathetic and spinal fibers. The *vagus* was identified when the carotid artery and internal jugular veins were dissected, and has probably been destroyed.

c. Between the heads of the ribs are the *vertebral ganglia* of the sympathetic system. They are stellate in shape, and fine cords will be seen connecting them from anterior to posterior. Because of these connecting cords this system is called the

chain ganglia. Lying on the vertebrae observe the nerve fibers from the ganglia.

d. Each ganglion is connected with the spinal nerve by two connecting cords, the *rami communicantes*. One ramus passes from the cord to the ganglion, and the other (the *gray ramus*) passes from the ganglion to the somatic branch of the spinal nerve, where the sympathetic nerves go to the capillaries, sweat glands, and hair muscles of the skin.

e. The nerves which pass ventrally from the ganglia go to deeper ganglia, the *prevertebral* ganglia, which cannot be found. The nerves of the deep ganglia innervate the viscera. Branches of the vagus accompany the sympathetic nerves in the anterior half of the body, acting as antagonistic controls for the sympathetic.

f. Note that the sympathetic system is intimately connected with the peripheral nerves and the spinal cord. Each ganglion is connected in series with the others; with the spinal cord; with the somatic branch of the spinal nerve; and with the deeper ganglia. Thus the sympathetic system is not an independent unit, but an intimate part of the nervous system. Wherever the sympathetic and *cranial* nerves innervate the same organ, in general terms the sympathetic may be considered the speeder of action, and the cranial nerves as depressors.

3. Dissection of Spinal Cord.

a. Continue the dissection of the cord anteriorly, noting that the spinal nerves are paired. If the cord is exposed to the cervical region, note the *cervical enlargement*, with the great number of spinal nerves passing to the plexus of the axilla. In the lumbar region is another enlargement, the *lumbo-sacral* enlargement, which can be exposed.

b. Cut the cord and observe it in cross-section. Even without a hand lens the two portions can be distinguished. The outer part is a glistening white, and toward the center is a darker grayish or yellowish H-shaped mass. The outer part is made up of long nerve fibers passing from the body to the brain and from the brain to body. The inner part is made up of nerve cells, a few fibers, and supporting tissue. These are distinguished as the "white substance" and the "gray substance".

c. With fine scissors slit and remove the thin tough sheath surrounding the cord. This membrane is continuous with the brain membranes, but the three layers cannot be separated.

d. It will be observed that both dorsally and ventrally a line extends longitudinally. With needles separate the tissues and open the fissures which cut into the cord, almost cutting it in two halves. These are the dorsal and ventral *fissures* of the cord.

e. Tear off a longitudinal fragment of the cord, place it on a microscope slide and tease the fibers apart. Under low power of the microscope the long course of the fibers can be determined.

4. Microscopic Structure of the Cord.

a. First locate the gray substance which will be more darkly stained than the outer part, due to the greater number of nuclei.

b. Identify the dorsal and ventral fissures, and between them the small *neurocoel.* The cord grew both by a proliferation of the nerve cells and by the invasion of fibers from other cells. The growth took place laterally, causing the two fissures, and accounting for the relatively small size of the neural canal.

c. In one half of the gray matter note the dorsal and ventral extensions or *horns.* The dorsal part is sensory, containing nerve cells which receive sensory impulses. These impulses are transferred to the motor cells by *association fibers.*

d. The ventral horn is *motor,* containing the very large, multipolar motor cells. From them motor impulses are carried through the spinal nerves to the musculature of the body.

e. The *white substance* of the periphery is divided into *tracts.* The two fissures (sulci) divide them into two halves; and the points of entry and exit of the nerve roots divide each half into dorsal, lateral and ventral tracts.

f. The dorsal region is largely sensory. These sensory tracts extend laterally along the periphery. These fibers pass up the cord to the brain, carrying sensory impulses.

g. Laterally, nearer the gray matter, the tracts are mixed sensory and motor; and the ventral tracts are nearly all motor. The motor fibers carry motor impulses from the brain down to the motor cells, the latter relaying the impulse to the body.

Would severing the motor tracts interfere with reflexes? Would voluntary action be interrupted by destroying the ventral motor cells?

h. Different stains may be used to indicate different nerve components. Silver nitrate impregnation stains the neurofibrils.

APPENDIX I

PREPARATION OF DEMONSTRATION SLIDES

1. Sectioning Fresh Cartilage by Hand.

a. A frog or young rat may be used, the former being preferable as the cartilage is more abundant. Take out the femur and clear away the muscle and connective tissue.

b. Using a safety razor blade or sharp scalpel begin at the end and cut the sections as thin as possible. A dissecting binocular microscope expedites the work. Let the sections fall into normal salt solution.

c. Mount a single section in normal salt under a cover slip. The section should be kept moist during study.

d. If the sections are cut perfectly transversely, the bone will be reached in a short time, and the central core of bone will be confusing unless explained. Only a minute fragment is needed.

2. Grinding Dry Bone.

a. Cut a transverse section of a large long-bone with a hack saw, making the section as thin as possible. With care a fairly large piece can be cut as thin as a millimeter.

b. Using a coarse water-stone grind the section down. Hold the section to the stone with a cork, which will keep it perfectly flat. Turn the section over frequently.

c. When the section is transparent under the microscope transfer it to a finer stone and continue until the bone is the required thickness.

d. It is easy to get the sections too thin. Leave enough body to show the caniliculi radiating in all directions.

e. Mount in hot balsam to seal the openings. Heat the balsam on the slide until the xylol is driven off. Place on a smooth, cool surface, put in a small fragment of the bone, and cover quickly with a cover slip. Air bubbles will be plentiful until the student gains proficiency, but they will not interfere unless they cover the bone section.

3. Preparation of Ligamentum Nuchi.

a. The ligament of the neck from a cow or a sheep is better for demonstration work than that of the smaller mammals. The ligament is larger and can be secured freer of other fibers; and the yellow fibers are larger and coarser.

b. A fragment of the ligamentum nuchi can be secured from an abattoir or butcher shop. The freezing causes little injury to the tissues, which can be teased apart and given to the students in normal salt solution.

4. Differentiating Connective Tissue Fibers.

a. White fibers swell with acids, and the principle is used to differentiate white and yellow fibers.

b. Place a fragment of subcutaneous tissue on a slide, tease it out until it is a thin smear, and mount in normal salt solution. Place a drop of 1% acetic acid at the side of the cover slip, and draw it through with a blotter on the opposite side.

c. The white fibers will swell and become almost invisible, leaving the yellow fibers intact.

d. See Paragraph 6 below for Mallory's differential stain.

5. Isolation of Muscle Fibers.

a. Fibers may be teased after fixation in formalin or alcohol, with fair results. Take out a fragment about half an inch long and two or three millimeters in diameter. Cover with fluid in a watch glass, and using two *sharp* needles begin at one end and gently tease the fibers apart. This is more effective for skeletal muscle than for either cardiac or smooth.

b. Maceration of tissues before teasing gives better results. Fix small pieces of tissue in 20 per cent. *nitric acid* and allow to macerate for about twenty-four hours. Decant the acid, add a small amount of water and shake the vial. If the fibers do not separate, cardiac and skeletal muscle should be teased. Smooth fibers may be macerated for a few more hours.

c. The fibers may be studied in water, or preferably glycerine. If permanent mounts are desired, the fibers may be dehydrated, cleared in xylol, and mounted in balsam.

d. For smooth muscle a mixture of equal parts nitric acid, glycerine and water has been recommended. (Lee, p. 247.) Nitric acid is simpler for students, and gives good results.

6. Mallory's Triple Stain.

a. Mallory's aniline stain is excellent for differentiating tissues. With smears that are simply dried the stain is rarely differential for yellow and white connective tissue fibers, but usually a few yellow fibers, or parts of fibers, will be stained a brilliant yellow.

b. For subcutaneous tissue make a smear as described in Par. 4, b. For reticular tissue, paraffin sections are necessary. The technique is simple. (Mallory and Wright, *Pathological Technique*, p. 322.)

c. For best results:

(1) Fix in Zenker's fluid. (Despite the warning of Mallory, the authors have had excellent results with Bouin, or even formalin fixation.)

(2) Embed in paraffin, the thickness of the section depending on the tissue.

(3) Stain in a $\frac{1}{10}\%$ aqueous solution of acid fuchsin for five minutes or longer.

(4) Transfer directly to the following solution and stain for twenty minutes.:

Aniline blue (Grübler's water soluble)	0.5 grams
Orange G (Grübler's)	2.0 grams
1% Aq. sol. phosphomolybdic acid	100.0 c.c.

(5) Wash quickly in distilled water.
(6) Carry directly to 95% alcohol, change several times, and carry through absolute to xylol. Clear several minutes.
(7) Mount in xylol balsam.

APPENDIX II

STAINING AND CLEARING EMBRYOS IN TOTO

1. Clearing and Staining for Bone. Schultze's modification of Spalteholtz' method has been found most economical and simplest for students' use. All that is absolutely needed is an open window, beakers, alcohol, potassium hydroxide, glycerine, a few stains, specimens, and patience. Embryos, frogs, salamanders, lizards, or any small animal can be cleared with the method.

a. If specimens are fixed in formalin, soak for a day or two in 95% alcohol strongly colored with iodine. If fresh embryos are used, fix in alcohol.

b. Embryos of pigs or rodents, which are normally loaded with fat, may be kept in pure acetone for several days after fixation, to remove the fatty tissue. This is an improvement but not necessary.

c. 3% potassium bichromate for one day. *This step can be omitted.* Keep the specimens on a fairly dark place to prevent precipitation.

d. 95% alcohol for four or five days. Any but delicate animals can be transferred from 95% alcohol to aq. sol. without damage.

e. Potassium hydroxide, 1% to 4%, aqueous solution, depending on the size of the specimen. Clear until the ribs are visible. If the appendages get soft, carry to glycerine-KOH (see "g" below) to harden. Depending on the specimen and the strength of the solution, from a day to several months may be required.

f. Stain *bones* with alizarin sodium sulfonate. Make a saturated solution of the alizarin in 95% alcohol, and add enough to a 1% solution of KOH to give a burgundy color. (Get a deep but transparent color.) Stain for a few hours, or make a weaker solution and stain longer. Dermal bones are better stained lightly, the amount of staining being easily determinable by examining the specimen. Turn the specimen to get equalization of staining. For *cartilage* stain see below.

g. Transfer to Mall's solution (water 79 parts, glycerine 20 parts, and KOH 1 part). If quicker results are desired, use less glycerine. Keep specimens in strong sunlight for depigmentation. This is particularly true of amphibia, reptiles, etc. Watch the specimens for disintegration, and if the appendages get floppy, transfer to stronger glycerine solution. Allow the specimen to remain in this until the soft tissues are completely destained.

h. Glycerine 25% for several days or longer. Gradually carry the specimen into stronger glycerine. Allowing the water to evaporate works very well. Preserve in pure glycerine.

i. If *fungi* develop, kill with a few crystals of thymol. It is well to add the thymol as a preventative to all containers, particularly when the finished product is stored.

2. Cartilage Staining.

a. Fix in formalin or alcohol.

b. Wash over night in 70% alcohol to which a few drops of strong ammonia have been added.

c. Stain with *toluidin blue.*

70% Alcohol	100. c. c.
Hydrochloric acid	0.50 c. c.
Toluidin blue	0.25 grams

Let stand for several hours, mixing thoroughly, and then filter. Stain the specimen for 3 to 5 days in an incubator at 35 or 40 degrees Centigrade, or longer at room temperature.

d. Harden and destain the specimen in 95% alcohol for several days. (Noble, G. K., recommends absolute alcohol for a day or two, but this is not necessary.)

e. Clear specimens in potassium hydroxide as given for bone. A weaker solution is recommended as the tissues are not so easily destained, and a slower reaction is preferable.

f. When reasonably clear, carry to Mall's solution weakened to one half strength, and then into pure glycerine.

g. Though the directions sound complicated, an intelligent student can make excellent preparations. Staining litter mates of embryos, some for bone, others for cartilage, makes a thoroughly worthwhile demonstration. Stages of development can be made with embryos of different ages.

3. Clearing Dogfish Skin.

a. Depigment the skin with hydrogen peroxide, dehydrate with absolute alcohol, and clear with xylol. This is the simplest method, and is fairly effective.

b. Better preparations can be secured by clearing with five per cent. potassium (or sodium) hydroxide, using sunlight as a depigmenting agent. Hydrogen peroxide is quicker, but causes a degeneration of the tissue when placed in the alkali. When the tissue is clear, place in 25 per cent. glycerine, and carry up to pure glycerine.

c. Depigmenting with hydrogen peroxide, boiling for a few minutes, and drying flat will give a permanent preparation of the skin. The dermal denticles show clearly with this method.

4. Dissociation of Dermal Denticles.

a. Boil a piece of the skin, preferably from the dorsal side where the denticles are larger, in a weak solution of potassium or sodium hydroxide. The denticles are left in better condition if the boiling is

done slowly using a weaker solution; or keep the water just below the boiling point.

b. The dissociated denticles can be demonstrated dry; mounted in a drop of glycerine under a cover slip; or, if permanent preparations are desired, in depression slides with balsam. The denticles are too thick for satisfactory mounting unless depression slides are used.

APPENDIX III

INJECTION AND PRESERVATION OF ANIMALS

1. Injections of the circulatory system may be made with one, two or three colors. When one color (red) is used, the injection is most conveniently made into the left ventricle of the heart. In this case the blood is forced into the veins, and when clotted turns black, thus enabling one to follow the veins. A more satisfactory method is to make a multiple injection, using two or three colors. An injection of the latter type usually shows the arteries red, the systemic veins blue, and the hepatic portal system yellow. This injection takes more time, but if this is available is well worthwhile. When a double or triple injection is made the blood is washed out before injecting the coloring mass.

2. Injection Masses.

a. For a single injection a very simple mass is satisfactory. This can be made by mixing corn-starch with water, making the mixture about the consistency of cream. Then add powdered *cinnabar* to obtain the color desired. Strain through several layers of cheese-cloth before using. Keep the mass well stirred up, or the coloring and starch will settle.

b. A much more satisfactory method is to use a warm gelatine mass. When the animal cools this sets, so when a vessel is accidentally cut the mass will remain in the vessel. This mass may be made as follows (Guyer's *Animal Micrology*, page 83):

Red injection mass.

(1) Rub up 4 grams of carmine with 8 cc. of water in a mortar. Add ammonium hydrate (NH_4OH) drop by drop until a transparent red color results.

(2) Soak 10 g. of best French gelatine with about 100 cc. of water until it is swollen and soft. If a granulated form is used this is a matter of only a half-hour. If another form is used it must be soaked over night.

(3) Remove the gelatine to a large beaker and heat it in a water bath until it is liquefied. Add the coloring mass, stirring constantly.

(4) Add a 25% solution of glacial acetic acid to the mass drop by drop, stirring constantly. Stop adding the acid when the mass becomes slightly opaque and the smell of ammonia is replaced by a slight acid odor. If this point is not reached the stain will diffuse through the tissues. If too much acid is added the carmine will be precipitated.

Blue injection mass.

(1) Make a gelatine mass as described above. To the warm mass add a saturated aqueous solution of Berlin blue to give the desired color. If the blue does not dissolve add a little oxalic acid.

Yellow injection mass.

(1) Make a gelatine mass consisting of 1 part gelatine to 4 parts of water by weight.

(2) Take equal parts of (1) the gelatine mass, (2) a cold saturated aqueous solution of potassium bichromate, and (3) a cold saturated aqueous solution of lead acetate. Add the bichromate solution to the gelatine and heat almost to boiling. Then add slowly, stirring constantly, the solution of lead acetate. The resulting precipitate will be sufficiently fine to go through any cannula.

c. Place each coloring mass in a bottle and allow to cool. When solid, cover the surface with a little 95% alcohol to prevent the growth of mold. When it is desired to use the mixture, pour off the alcohol and heat the gelatine mass.

3. Materials Needed.

a. Single injection.

(1) Syringe—preferably a 250 cc. metal one.

(2) Glass tubing drawn out into a point, and point broken off to give sharp edge. Not needed if a sharp steel needle is available.

(3) Rubber tubing with the glass needles attached at one end, the syringe to be attached to the other.

(4) Anesthetizing material—ether, chloroform, illuminating gas.

(5) Dissecting instruments.

b. Double injection or triple injection. Same as in "a" but with the following differences and additions:

(1) The glass cannulae to be finer (the inside diameter of the tube should be about 1 m.m. in diameter) and the edges to be flamed to avoid the cutting of blood vessels.

(2) Normal salt solution (0.7 – 0.9% aqueous solution of NaCl) warmed to blood temperature (98°F.).

(3) Injecting masses. If gelatine mass is used this should be melted and kept in a warm bath of water.

(4) Course thread for ligatures.

4. Method of Single Injection.

a. Expose the heart and remove the pericardium.

b. Slit the skin on the medial surface of the hind leg. Pull the skin away from the incision until two parallel blood vessels and a nerve are exposed.

c. Insert the sharp glass or steel needle into the ventricle—into the left if two ventricles are present—and inject the mass. Continue the injection with a steady pressure until the injecting mass appears in the artery which was exposed on the hind leg. Continue a short time more to be sure that all the vessels are injected. When they are full

the back pressure will be considerable, as the corn-starch mass will not pass through capillaries.

d. Remove the needle and preserve the animal (see Paragraph 11).

e. For specific directions for various animals used in this manual see Paragraphs 6–10.

5. Method of Triple Injection.

a. Slit the skin on the side of the neck to expose the large vein, the jugular. Loosen this and slip two ligatures lightly around the vessel.

b. Slit the skin of the thigh to expose the leg blood vessels (femoral artery and vein). Loosen these and separate them from each other.

c. Slip a ligature around each vessel. Make an oblique slit in the artery distal to the ligature, the slit slanting toward the body. The artery can be distinguished from the vein by its lighter color.

d. Fill the syringe and an attached glass cannula with warm normal salt solution, slip the cannula into the artery, and tighten the ligature so it holds the artery tightly around the cannula.

e. Make a slit in the jugular vein between the ligatures, and inject the normal salt into the femoral artery until all the blood is washed out and the salt solution comes out of the jugular unmixed with blood.

f. Unscrew the syringe from the cannula and fill the syringe with red gelatine mass. Again attach the syringe to the cannula and inject this until the tip of the nose becomes pink or until the back pressure becomes great. Slip the cannula out of the artery, tightening the ligature as it is withdrawn.

g. Inject blue coloring mass into the femoral vein in the same way. When this mass starts coming out of the jugular vein tighten both the ligatures on that vessel. Inject a little more blue and then withdraw the cannula as before.

h. Open the body cavity and loosen one of the uninjected vessels in the mesentery. Ligate this lightly in two places. Make a slit between the ligatures and inject a yellow mass in one direction. When back-pressure becomes considerable, withdraw the cannula, tightening the ligature. Then in the same way inject in the opposite direction. This injects the hepatic portal system.

6. Injection of Necturus.

a. *Single Injection.* Make an incision through the skin overlying the pectoral girdle and anterior to it. Then cut through the pectoral girdle and the thin wall just anterior to expose the heart. Remove the pericardial membrane and inject a red coloring mass into the ventricle.

b. *Triple Injection.* Inject through the femoral artery and vein (see Paragraph 5). If a double injection is desired the femoral injections are sufficient. If a triple injection is wanted, open the body cavity by making an incision to the right of the mid-ventral line and inject the hepatic portal system. Due to the small arteries and veins a triple injection is difficult, and for practical purposes it is usually

better to make a single injection or to purchase the specimens already injected.

c. For preservation see Paragraph 11. For external anatomy see Part VII, page 107.

7. Injection of the Alligator.

a. *Single Injection.* Slit the skin from the pectoral girdle posteriorly half-way to the pelvic girdle. Beginning at a point where the true ribs will be seen meeting the sternum, make an incision through the body wall just to one side of the mid-ventral line, cutting through the ribs. This will expose the heart within the pericardium. The latter should be removed. Make an injection into the left ventricle.

b. *Multiple Injection.* A *double injection* can be made by opening the jugular vein (see Paragraph 5) and washing out the blood with normal saline injected into the heart. Then inject a red coloring mass into the heart without removing the cannula. Extending along the abdomen, to either side of the mid-ventral line, is an abdominal vein. Select one of these, ligate loosely in two places, and then inject yellow in both directions. This should inject the renal portal and hepatic portal systems, as well as the abdominal veins. A *triple injection* can be made by first making a double injection and then carefully inserting the cannula into the right auricle and injecting blue. See page 109 for external anatomy, which should be studied before the preservation of the animal. Directions for preservation are in Paragraph 11 of this Appendix.

8. Injection of the Turtle.

a. *Preparation:* Anesthetize the animal. Using a hack-saw cut through the lateral bridge of bone which connects the ventral plastron with the dorsal carapace. Make this cut near the plastron, being careful not to cut into the soft tissues. With a saw it is difficult to cut through the thicker anterior and posterior parts of the bridge without cutting blood vessels. These portions can be broken with bone forceps. After having made these cuts on each side, lift the plastron. Slip a dull knife into the incision, and loosen the tissues from the plastron. Muscles, skin, and connective tissue attach to it, and they should be loosened, rather than cut, by keeping the knife close against the plastron. Remove the plastron entirely.

b. *Single Injection.* The heart will be seen in the mid-line about one third the distance from the pectoral girdle to the base of the tail. Remove the pericardial sac and inject into the ventricle.

c. *Multiple Injection.* Expose the jugular vein and make an incision in it (see Paragraph 5). Wash out the blood by injecting normal saline into the heart. Change the syringe and inject red coloring mass into the heart. The abdominal veins will be noted posterior to the heart paralleling the mid-ventral line. Loosen one and inject yellow in both directions. This will inject the renal portal and hepatic portal systems. To inject the systemic veins, the simplest method is to inject blue into the right auricle. It may be necessary

to clamp or tie off the ventricle while making this injection to prevent the blue from passing out through the ventricles. (See Paragraph 11 in this appendix and also page 108.)

9. Injection of the Bird.

a. The injection of the bird is complicated by the great size and the rich blood supply of the pectoral muscles. Care must be taken to avoid cutting this muscle, or the injecting mass will leak through the cut and the posterior part of the body will be uninjected.
b. After anesthetizing the animal, remove the feathers and slit the skin along the "breast".
c. Locate the edge of the keel of the sternum along the mid-ventral line of the anterior part of the body.
d. Using a smooth dull scalpel separate the pectoral muscle from the left side of the keel. The edge of the knife must be kept hard against the bone, as this will cut only the tendinous attachment and not the muscle.
e. After the muscle is entirely separated from the sternum, lay it back and examine the sternum. A flat plate lies parallel to the ventral surface of the body. This is very thin and can be cut with ordinary scissors.
f. Make an incision through this bone next to the keel, and widen the incision with the fingers. Remove the pericardium and inject into the left ventricle.
g. A *multiple injection* may be made by injecting the femoral artery and vein (see Paragraph 5) but a single injection will show all the vessels mentioned in this manual. (See Paragraph 11 of this appendix and also page 110.)

10. Injection of the Mammal (CAT and RABBIT).

a. *Single Injection.* Slit the skin along the mid-ventral line. Beginning at the point where the last ribs join the sternum, cut anteriorly on the left side of the sternum through the ribs to expose the heart. Remove the pericardium. Inject into the left ventricle.
b. *Triple Injection.* Expose the jugular vein and the femoral vein and artery. Ligate these and inject normal salt, following with red and blue coloring masses. Inject the hepatic portal system. For more specific directions see Paragraph 5. For the external anatomy, which should be studied immediately, see page 110. For preservation see Paragraph 11 of this appendix.

11. Preservation of Injected Animals.

a. *Necturus.* If it has not already been done, open the abdominal cavity and immerse in 10% formalin for a few days. Then remove to a 3% solution.
b. *Alligator.* This animal is very difficult to preserve. For satisfactory preservation it is necessary to skin the animal (see page 109). Also open the peritoneal cavity, by making a longitudinal incision through the muscles and peritoneum between the two abdominal veins.

Immerse in 10% formalin for two weeks and then transfer to 5%. Before using, soak in water for two days and then keep the animal in 3% formalin.

c. *Turtle.* This will keep if immediately transferred to 5% formalin.

d. *Bird.* Remove all the feathers. At the base of the neck is the very thin-walled *crop* which is usually partially filled with food. Make an incision in this and clean it. Remove the skin and tissues from the posterior part of the head. Using a cartilage knife or bone forceps make an opening in the skull to allow preserving fluids to reach the brain. Be sure the peritoneal cavity is open. Preserve in 5% formalin.

e. *Mammal.* If the abdominal cavity is not already open, make a longitudinal incision. In the RABBIT a large food-filled sac will be seen. This is the caecum, in which bacterial digestion goes on. Find the two ends, one emptying into the intestine, the other blind. Make an incision at each end, and into one of these run a stream of water, thus cleaning out the food. If the stomach is filled with food, this should also be washed out in the same manner. In the CAT the entire digestive tract should be washed. At the anterior end of the stomach make a small incision. Make another opening about a foot posteriorly. Run water into the first opening. When that part is clean, make another opening a foot farther posteriorly. Run water into the second opening and out this last one. Continue this process until the entire digestive tract is clean. In both animals, using a heavy scalpel or bone forceps, make an opening in the posterior part of the skull to insure preservation of the brain. After studying the external anatomy (page 110) skin the animal and preserve in 5% formalin.

APPENDIX IV

LABORATORY STORAGE OF SPECIMENS

One objection often raised against a systemic method of treatment of comparative anatomy is the mechanical difficulty of storing animals so that they are easily available. When three or four animals are being dissected at the same time the problem becomes acute, and on its solution rests the possibility of using the systemic method.

There are many simple methods by which the animals can be kept separated. In some institutions the method followed is to assign to each student a large covered pail in which he may keep all his specimens. In Washington Square College after much experimentation we have evolved a simple but very satisfactory method for which the following materials are needed for each twenty students:

a. One 30-gallon crock or tank (see below).
b. Large muslin bags about 20″x 30″, with a heavy draw-string in the top. Sugar bags are satisfactory. These bags can be purchased from most bag manufacturers for about 15 cents each. One of these bags is needed for each type of animal used. Each bag is labelled with the type of animal to be placed in it.

The entire twenty students place all their specimens, labelled with the student's name on a tag which is then dipped in melted paraffin, into the same crock. All the Necturi are placed in one bag, mammals in another, etc. When one specimen is desired, the labelled bag with the string makes it possible to draw out of the tank all the animals of that type. The animals are then dumped onto a pan or into a sink, and the student picks out his own specimen. By using this method it has been found possible to use four different animals, and accommodate in a single laboratory, seven groups of sixty students each.

Tanks can be made for use in place of crocks. These are particularly desirable if the storage room is limited, as they will accommodate more animals to a given amount of floor space than crocks. The initial cost is higher, but there is a smaller item for breakage. We have adopted a wooden, galvanized-iron lined tank with inside dimensions of 18″ x 18″ x 24″ deep. The tank has a heavy, hinged top, and is mounted on piano casters. This gives a sturdy, very flexible unit, enabling specimens to be stored with a minimum loss of floor space. If the lining becomes corroded the tank can be relined at a low cost, or a zinc lining, which is more expensive but more durable, can be used in the first place.

APPENDIX V

LATIN AND GREEK ROOTS OF SCIENTIFIC NAMES

The following list of Greek and Latin stems is not intended to be complete, but includes only those terms most frequently used in the course. The root is given in italics, with a letter denoting whether it is taken from the Latin or Greek; this is followed by the original meaning and one or more examples.

a, G. without; Apoda, asepsis
ab, L. away from: aboral, abduct
acantha, G. prickle or spine: Squalus acanthias
acinus, L. grape: acinus, aciniform
acros, G. summit or top: acromion, acrodont
ad, L. to or toward, upon: adduct, adrenal
albus, L. white: albinism, linea alba
alveolus, L. a little pit or socket: alveolar, alveolitis
ambly, G. dull, blunt: Amblystoma
amphi, G. both: Amphioxus, Amphibia
an, G. without: anamniote, Anapsida
ankylos, G. to crook or stiffen: ankylosis
ante, L. before: anterior, anteflexion
anthro, G. man: anthropoid, anthropology
apsis, G. an arch: synapse, anapsid, diapsid
aqua, L. water: aqueous, aqueduct
arach, G. spider web: arachnoid
archos, G. ancient, first: archenteron, archipallium
arthros, G. joint: arthritis, arthrotome
atrium, L. entrance chamber: atrium (of heart or tympanic cavity)
auto, G. self: autostylic, autonomic

basi, L. at the base of: basicranial
bi, L. two: biceps, bilobed
bios, G. life: amphibian, biology
blastos, G. germ: blastoderm, blastula
brachium, L. arm: brachial
brachy, G. short: brachycephalic, brachydactylic
branchia, G. gill: hemibranch, Branchiostoma
bucca, L. cheek or mouth: buccal cavity
bulla, L. bubble: tympanic bulla

caecus, L. blind: caecum
cardia, G. heart: pericardium, cardiac
carina, L. keel: carina (of rostrum or bird sternum)
cauda, L. tail: caudal, cauda equina
cephale, G. head: cephalad, cephalic
cercos, G. tail: heterocercal, homocercal
cervix, L. neck: cervical
chiasma, G. a crossmark: optic chiasma
chondros, G. cartilage: chondrocranium

chorda, L. a cord or string: Cephalachorda, chordate
chyme, G. juice, fluid: mesenchyme
clast, G. to break: osteoclasts
cloaca, L. sewer: cloaca
comma, G. that which is cut off: myocomma
condylus, L. knuckle: condyle
cornua, L. horn: cornu (of hyoid or uterus)
corpus, L. body: corpora quadrigemina, corpus callosum
cortex, L. bark: cortex (of kidney or cerebrum)
costa, L. rib: costal
crossoi, G. fringe: Crossopterygii
cryptos, G. hidden: Cryptobranchus, cryptorchid
cuspus, L. point: tricuspid
cutis, L. skin: cutaneous
cyclos, G. circle: Cyclostomata, cycloid
cytos, G. cell or hollow space: cytology, leucocyte

dactylos, G. finger: pentadactyl, pterodactyl
defero, L. to carry away: deferens
delphos, G. uterus: Didelphys
dendron, G. tree: dendrite
dens, L. tooth: dentist, dentary
derma, G. skin: epidermis, dermal, dermatome
di, G. two: digastric, diapsid
dia, G. between: diaphragm, diapedesis
digitus, L. finger: digit, digitigrade
diplos, G. double: diploblastic, diploid
duco, L. to lead: adduct, aqueduct
dura, L. hard: dura mater

ect, ecto, G. the outer, outside: ectoplasm, ectoderm
effero, L. to carry away from: vasa efferentia, efferent
elasmos, G. plate, flat: elasmobranch
end, endo, G. within, inside: endostyle, endoderm
enteros, G. inside: enteron
ep, epi, G. upon: epidermis, epididymis, epimere
erythros, G. red: erythrocyte
ex, L. out, outside: exterior, exophthalmic

fenestra, L. window: lateral fenestra
fero, L. to carry: afferent, efferent
filum, L. thread: filoplume, filum terminale
foramen, L. an opening: foramen magnum
foramina, L. a small opening
fossa, L. a pit or cavity: temporal fossa, endolymphatic fossa

gaster, L. stomach: gastric, gastrocoele
germino, L. to sprout: germinal, germinativum
glossa, G. tongue: glossopharyngeal, hypoglossal
gnathos, G. jaw: agnatha, Gnathastomata
gradus, L. step, walk: plantigrade, digitigrade

haima, G. blood: haemoglobin, haemolysis
hemi, L. half: Hemichordata, hemibranch
hepar, G. liver: hepatic
heteros, G. different: heterocercal, heterodont
holos, G. whole: holobastic, holostei
homos, G. the same: homocercal, homologue
hyp, hypo, G. or L. below, less than: hypaxial, hypoglossal
hyper, G. over, above: hyperthyroid, hypertrophy

ichthys, G. fish: Ichthyosaurus, ichthyology

incido, L. to cut into: incisor, incisure
inter, L. between: intervertebral, intercostal
intra, L. within: intracellular, intravascular
isos, G. equal: isotonic, isomorphic
iter, L. passage

labium, L. lip: labial, labia
lacrima, L. tear: lacrimal (bone or duct)
lacuna, L. space, void: lacuna
lamina, L. a thin sheath: lamella
lepis, G. scale: Lepidosteus, Lepidosiren
leucos, G. white: leucocyte, leukemia
levator, L. a lifter: levator scapulae
lingua, L. tongue: lingual
lithos, G. a stone: otolith, lithochrome
luna, L. moon: semilunar, lunatum
lympha, L. clear water: lymphatics, lymphocyte

macros, G. large: macroscopic, macronucleus
mamma, L. breast: mammal, mammary
marsupium, L. pouch: marsupial, marsipobranch
medius, L. middle: median, mediad
medulla, L. marrow, core: medulla
meros, G. part: metameric, epimere
mes, *meso*, G. the middle: mesomere, mesenchyme, mesoderm
met, *meta*, G. or L. between or after: metacarpal, metanephros
monos, G. one: monomeric, monophyodont
morph, G. form: morphology, neomorph
mys, G. muscle: myotome, myology
myzon, G. sucker: Petromyzon

nephros, G. kidney: nephrostome, nephrotome
neuron, G. nerve: neurocoele, neurone
notos, G. back: notochord
nucha, L. the nape of the neck: nuchal, ligamentum nuchi

occiput, L. back of the head: occipital
oculus, L. the eye: oculomotor, oculist
odons, G. tooth: heterodont, thecodont
onto, G. being: ontogenetic
ophthalmos, G. eye: ophthalmic
orthos, G. straight: orthogenesis, orthopedic
osteos, G. bone: Teleostei, periosteum
otikos, G. pertaining to the ear: otic, synotic
ovum, L. egg: ovary, oviparous
oxys, G. sharp: Amphioxus

pallium, L. cloak or mantle: archipallium, pallial
papilla, L. nipple: papillary, papilla
para, G. beside, near: parotid, parasphenoid
peri, G. or L. around: pericardium, perilymph
petros, G. a stone: Petromyzon, petrosal
phag, G. to eat: esophagus, phagocyte
physos, G. bubble: epiphysis, hypophysis
planta, L. sole: plantigrade
plax, G. plate: placoid
pleura, G. side: pleural, pleuradont
plexus, L. interweaving: choroid plexus
pneuma, G. breath: pneumogastric, pneumonia
poda, G. foot: Apoda, tetrapod
polys, G. many: polyphyodont, polynuclear
post, L. behind, after: postcava, posterior

pre, L. before: precava, premolar
pro, G. or L. in front, toward: procoelous, procephalic
pteron, G. wing: pterygoid, pterodactyl

quadratus, L. square: quadrate, quadratus lumborum

ramus, L. branch: ramus (of nerve or jaw)
rectus, L. straight: rectum, rectus abdominis
renes, L. kidney: renal, adrenal
rhis, G. nose: rhinal, Rhinoceros, rhinencephalon
rostrum, L. beak: rostrum

sacculus, L. a little sac
saurus, G. a lizard: Dinosauria
scleros, G. hard: sclerotome, arterio sclerosis
sella, L. a seat or saddle: sella turcica
semi, L. half: semilunar, semispinalis
septum, L. fence, wall
sinus, L. curve, hollow bag: sinus venosus
soma, G. body: somatic
splanchnon, G. one of the viscera: splanchnic
squalus, L. fish: Squalus acanthias
squama, L. scale: squamosal, squamous
stego, L. to cover: Stegocephalia
stoma, G. mouth: stomodaeum, Cyclostomata
stratum, L. a layer or cover: stratum Malpighii
stria, L. a furrow: corpus striatum, striated
sub, L. under, below: subintestinal
super or *supra*, L. above: supratemporal, supraoccipital
syn or *sym*, G. or L. together, with: synotic, syncytium
syrinx, G. a pipe

teleos, G. whole, perfect: Teleostei
tetra, L. four: tetrapod, tetrad
theros, G. wild beast: Thermorpha
toma, G. cut section: dermatome, myotome
trema, G. hole; opening: Monotreme, pretrematic
tri, L. three: triceps
tunic, L. tunic: Tunicates, Tunica vaginalis
tympanum, L. drum: tympanic

umbilicus, L. navel: umbilical
ungula, L. hoof: unguligrade
uni, L. oné: uniform, unicellular
ura, G. tail: Urodele, Anura

vas, L. a duct or vessel: vas deferens vasa efferentia
venter, L. belly: ventral, proventriculus
vermis, L. worm: vermiform
vitreous, L. glassy: vitreous humour

zoön, G. animal: protozoa, zoology

INDEX

abdominal pores, 12
abdominal veins—see circulatory system
abducens nerve, 240
abduction, 116
Acipenser, 44
Acipenser, integument of, 100
Acraniata, 37
adduction, 116
afferent branchial arteries—see circulatory system
air sacs, 167
Alligator, 47
  circulatory system, 185
  digestive system, 163
  external anatomy, 109
  muscular system, 120, 123, 127, 138, 144, 148, 156
  respiratory system, 160
  skeleton, 69, 80
  skull, 69
  urinogenital system, 220
Amblystoma
  external anatomy, 42
  tigrinum, 46
Amia, 45
  integument, 101
amnion, 38, 115, 234
Amphibia, 38
  integument, 101
  orders, 45
  skull, 61
Amphioxus
  circulatory system, 7
  cross-sections, 5
  discussion, 8
  gross anatomy, 1
Anapsida, 46
antlers, 106
Anura, 46
Apoda, 45
aponeurosis, definition, 116
appendicular skeleton of dogfish, 13
Archaeopteryx, 47
Archaeornithes, 47
archipallium, 244
Armadillo, 48
arteries—see circulatory system
Artiodactyla, 49
atriopore, 1, 3
atrium, 6
auditory capsules—see otic capsules
auditory nerve, 241
Aves, 38
  sub-classes, 47
Axolotl, 46

bird
  external anatomy, 43, 110
  integument, 103
  see pigeon
blood, structure, 214
bone
  clearing and staining, 260
  preparation of slides, 257
  structure, 56
brain
  development, 34
  dogfish, 32
  mammal, 248
  pigeon, 244
branchial arches, dogfish, 18
branchial arteries—see circulatory system
branchial lamellae—see gills
branchiomeric muscles, 118
buccal cirri, 1
buccal funnel of lamprey, 39
buccal hood, 1
buccal skeleton, 2, 5
bulbo-urethral gland, 225

canine teeth, definition, 75
Capitosaurus, 45
  skull, 61
carapace of turtle, 82
Carinates, 47
Carnivora, 49
carpus, mammal, 92
cartilage, 51
  clearing and staining, 261

cartilage (*continued*)
sectioning, 257
structure, 56
cat
brain, 248
circulatory system, 200
digestive system, 167
external anatomy, 110
muscular system, 120, 125, 134, 142, 146, 153, 158
nervous system, 247, 251
respiratory system, 170
skeleton, 91
skull, 72
urinogenital system, 222
central canal, 8
see neurocoele
cerebral cortex, 248
Cetacea, 49
Chelonia, 46
Chiroptera, 48
chondrocranium
derivatives, 59, 60
development, 15, 59, 60
dogfish, 15
foramina, 17
Chondrostei, 44, 58
Chordata
classes, 37
definition, 37
circulatory system of Alligator, 185
abdominal veins, 186
arteries, 188
dorsal aorta and its branches, 185, 186
heart and its vessels, 185
heart, structure, 211
hepatic portal system, 187
pulmonary system, 188
renal portal system, 186
systemic veins, 187
circulatory system of Amphioxus, 7
dorsal aorta, 7
hepatic portal vein, 7
hepatic vein, 7
sub-intestinal vein, 7
ventral aorta, 7
circulatory system of the cat, 200
dorsal aorta and its branches, 203, 206
heart and its vessels, 200
heart, structure, 212
hepatic portal system, 205
cir. system of the cat (*continued*)
postcava, 202, 208
pulmonary system, 209
systemic veins, 201
circulatory system of the dogfish, 23
abdominal veins—see lateral veins
afferent branchial arteries, 24, 25, 26
dorsal aorta and its branches, 24, 28
efferent branchial arteries, 24, 26
heart and its vessels, 22, 29
heart, structure, 29
hepatic portal system, 25
renal portal system, 25
systemic veins, 24
ventral aorta, 24
circulatory system of Necturus, 175
abdominal vein, 177
afferent branchial arteries, 176
arteries of the head, 179
dorsal aorta and its branches, 176
efferent branchial arteries, 176
heart, 175
heart, structure, 209
hepatic portal system, 177
pulmonary system, 179
renal portal system, 177
systemic veins, 178
circulatory system of pigeon, 188
dorsal aorta and its branches, 189
heart and its vessels, 189
heart, structure of, 212
hepatic portal system, 190
pulmonary system, 189, 191
systemic veins, 190
circulatory system of rabbit, 191
dorsal aorta and its branches, 194, 197
heart and its vessels, 191
heart, structure, 212
hepatic portal system, 196
postcava, 193, 199
pulmonary system, 200
systemic veins, 192
circulatory system of turtle, 179
abdominal veins, 182
dorsal aorta and its branches, 181, 184
heart and its vessels, 180
heart, structure, 210
hepatic portal system, 183

cir. system of the turtle (*continued*)
  postcava, 184
  pulmonary system, 180
  renal portal system, 182
  systemic veins, 183
circumduction, 117
Cladoselache, 44
claspers, 11
classification, method of, 36
clavicle, mammal, 92
claws, 105
clitoris
  Alligator, 221
  mammal, 225
  turtle, 219
condyles—see occipital condyles
connective tissues, 51
  preparation, 258
  structure of, 54
coracoid, dogfish, 14
corpus callosum, 250
corpus cavernosum
  mammal, 225
  turtle, 218
corpus cavernosum urethrae, 225
corpus luteum, 225, 230
corpus restiformis, 33
corpus spongiosum, 225
Cotylosauria, 46
Cowper's gland, 225
cranial flexures, 233
cranial nerves
  dogfish, 239
  mammal, 250
  pigeon, 245
Crocodilia, 47
Crossopterygii, 45
Cryptobranchus, 46
  skull, 64
ctenoid scales, 101
cycloid scales, 101
Cyclostomata, 38
Cynognathus, 46

decussation, definition of, 250
dental formulae, 75
depression, 116
dermal denticle, 100
  dogfish, 12
  isolation of, 261
  see scales
dermatome, 115
dermis, 5
Diapsida, 46
digestive system
  Alligator, 163
  Amphioxus, 3
  cat, 167
  dogfish, 20
  Necturus, 159
  pigeon, 165
  rabbit, 167
  turtle, 160
digestive tract, structure of, 173, 174
digitigrade, definition, 99
Dimetrodon, 46
  skull, 69
Dinosauria, 46
Dipnoi, 45
dogfish, 11
  brain, 32
  circulatory system, 22, 23
  cross-sections, 34
  digestive system, 20
  external anatomy, 11
  eye, 236
  musculature, 19
  nervous system, 238
  skeleton, 13, 15
  urinogenital system, 29
dorsal aorta—see circulatory system
dura mater
  mammal, 248
  pigeon, 244

Echidna, 47
Edentata, 48
efferent branchial arteries—see circulatory system
Elasmobranchii, 44
Elasmobranch integument, 100
embryology, definition, 50
endomysium, 116
endostyle, 3, 6, 8
epaxial muscles
  dogfish, 19
  see muscles
epidermal structures, 106
epididymis
  cat, 223
  dogfish, 30
  rabbit, 223
  turtle, 218
epimere, 115
epimysium, 116
epipharyngeal groove, 3, 6

epiphysis, 244
  dogfish, 33, 238
epithelia
  structure, 52
  types, 50
Euchordata, 37
Eustachian tubes
  mammal, 168
  see skulls
Eutheria, 48
extension, 117
external anatomy
  Alligator, 109
  cat, 110
  dogfish, 11
  Necturus, 107
  pigeon, 110
  rabbit, 110
  turtle, 108
eye, muscles
  dogfish, 236
eye, structure
  dogfish, 237
  pigeon, 246
eye-spot, Amphioxus, 3

facial nerve, 241
Fallopian tube, 226
fascia, definition, 116
fascicles, 116
feathers
  development, 103
  structure, 103
femur, mammal, 94
fibula, mammal, 94
fins, Amphioxus, 2
fins, dogfish, 11
flexion, 117
flexures of brain, 233
foot position, 99
foramina, mammal skull, 76
forebrain, 232, 234

Ganoids, 45, 101
ganoid scales, 100
generalized, definition of, 9, 10
gills
  Amphioxus, 3, 6
  dogfish, 26
gill slits
  Amphioxus, 3, 6
  dogfish, 13
girdle, pectoral
  Alligator, 81
  cat, 91
  dogfish, 14
  pigeon, 86
  rabbit, 91
  turtle, 83
girdle, pelvic
  Alligator, 82
  cat, 93
  dogfish, 14
  pigeon, 87
  rabbit, 93
  turtle, 84
girdles, comparisons, 97, 98
glossopharyngeal nerve, 241
groove of Hatschek, 5

haemal arch, dogfish, 13
hair, 105
Haversian system, 57
head (of muscles), definition, 116
heart, structure of
  Alligator, 211
  dogfish, 29
  mammal, 212
  Necturus, 209
  pigeon, 212
  turtle, 210
heart—see circulatory system
hemibranch, definition of, 26
Hemichordata, 37
hepatic portal system—see circulatory system
herring, external anatomy, 40
heterocercal tail, 14
heterodont, definition, 96
heterodont dentition, 72
hindbrain, 232, 234
histology, definition, 50
Holostei, 44
homocercal tail, 40
homodont, definition, 96
homodont dentition, 72
horns, 105, 106
humerus, mammal, 92
hyoid
  Alligator, 165
  cat, 169
  rabbit, 169
  turtle, 162
hyoid arch, 17
hyomandibular bar, 16, 17

hypaxial muscles
dogfish, 19
see muscles
hypomere, 115
hypophysis
dogfish, 33, 243
mammal, 250
pigeon, 245

Ictidopsis, 46
skull, 72
ileum—see digestive system
ilium, mammal, 93
incisor teeth, definition, 75
inguinal canal, 224
cat, 154
rabbit, 151
injection
Alligator, 266
bird, 267
mammal, 267
Necturus, 265
turtle, 266
injection masses, 263
injection materials, 264
injection methods, 264
inner ear, dogfish, 234
Insectivora, 48
integument
Acipenser, 100
Amia, 101
birds, 103
elasmobranchs, 100
Lepidosteus, 100
Manis, 104
Mammals, 104
interstitial cells of testis, 228
intervertebral plates, 13
ischium, mammal, 93
insertion, definition, 116

kidney, see—
pronephros
mesonephros
metanephros

labia majora, 111, 225
lamprey, anatomy of, 38
lampreys, 38
larynx
Alligator, 165
cat, 134
rabbit, 130
turtle, 163
lateral line, 12
lateral veins—see circulatory system
Lepidosteus, 45
integument of, 100
ligaments, 20
ligamentum nuchi, preparation, 257
limb, anterior
Alligator, 81
cat, 92
comparisons of, 97
dogfish, 14
pigeon, 86
rabbit, 92
turtle, 83
limb, posterior
Alligator, 82
cat, 94
comparisons of, 98
dogfish, 14
pigeon, 87
rabbit, 94
turtle, 84
lizard, external anatomy, 42

mammal
external anatomy, 110
integument, 104
skeleton, 104
see cat and rabbit
Mammalia, 38
orders of, 47
Manis, 49
integument, 104
Marsupialia, 48
Meckel's cartilage
dogfish, 17
embryonic, 59, 60
meninges, 239
bird, 244
mammal, 248
meninx primitiva, 239
mesenchyme, 51
mesenteries—see digestive system
mesonephros
dogfish, 30, 31
development, 32
Necturus, 217
metanephros
Alligator, 220
mammal, 222
pigeon, 221
structure, 227
turtle, 218

Metatheria, 48
midbrain, 232
molar teeth, definition, 75
Monotremata, 47
mouse, external anatomy, 43
Müllerian duct
  Alligator, 221
  dogfish, 31
  development, 32
  mammal, 226
  Necturus, 217
  pigeon, 222
  turtle, 219
Mus, external anatomy, 43
muscle
  action, 116
  classification, 50
  development, 113
  dissection, 118
  gross anatomy, 116
  histology, 53
  nomenclature, 118
muscle fibers, isolation of, 258
muscles of
  anterior limb, 138
  body, 143
  eye, 236
  head, 121
  neck, 126
  pelvis, 147
  shank, 156
  shoulder, 126
  thigh, 147
muscles of Alligator
  biceps, 138
  biceps femoris, 150
  brachialis, 139
  brachioradialis, 139
  coracobrachialis, 139
  deltoid, 129
  digastric, 123
  epaxial, 120, 144
  extensor carpi radialis, 139
  extensor carpi radialis brevis, 139
  extensor carpi ulnaris, 139
  extensor digitorum communis, 139
  extensor digitorum longus, 156
  external mandibulo-hyoid, 127
  external oblique, 144
  flexor carpi ulnaris, 140
  flexor digitorum longus, 157
  flexor digitorum profundus, 140
muscles of Alligator (*continued*)
  flexor digitorum sublimis, 140
  flexor radialis, 139
  gastrocnemius, 157
  gemellus, 149
  geniohyoid, 123
  gluteus, 151
  gracilis, 148
  hypaxial, 120, 150
  iliopsoas, 149
  intercostal, 144
  internal mandibulo-hyoid, 127
  internal oblique, 144
  internal semispinalis capitis, 128
  latissimus dorsi, 129
  latus colli, 128
  levator scapulae, 128
  longissimus capitis, 129
  longus colli, 128
  mylohyoid, 120, 123
  obturator externus, 149
  obturator internus, 149
  omohyoid, 128
  pectoralis, 120, 130
  peroneus anterior, 156
  plantaris, 157
  psoas major, 150
  pterygoid, 120, 123
  pyriformis, 150
  rectus abdominis, 120, 144
  rectus femoris, 150
  rhomboideus, 129
  sartorius, 150
  scalenus, 128
  semimembranosus, 150
  semispinalis capitis, 128
  semitendinosus, 149
  serratus anterior, 129
  sphincter colli, 123
  splenius capitis, 129
  splenius cervicis, 129
  sternohyoid, 127
  sternomastoid, 128
  supinator, 139
  supracoracoideus, 130
  temporal, 123
  teres major, 129
  teres minor, 130
  tibialis anterior, 156
  transversus, 144
  trapezius, 120, 128
  triceps, 139
  vastus, 151

muscles of cat
adductor femoris, 154
adductor longus, 155
anterior trapezius, 121, 135
biceps, 142
biceps femoris, 155
brachialis, 142
brachioradialis, 142
caudofemoralis, 155
clavobrachialis, 137
clavodeltoid, 137
clavotrapezius, 135
cleidomastoid, 134
coccygeal, 147
coracobrachialis, 142
deltoid, 136, 137
depressor conchae, 125
digastric, 126
dorsal levator scapulae, 135
epaxial, 120, 126
extensor carpi radialis, 143
extensor carpi ulnaris, 143
extensor digiti, 143
extensor digitorum communis, 143
extensor digitorum longus, 158
extensor antebrachii, 142
external oblique, 147
flexor carpi radialis, 143
flexor carpi ulnaris, 143
flexor digitorum longus, 158
flexor digitorum profundus, 143
gastrocnemius, 158
gemellus, 156
geniohyoid, 125
gluteus maximus, 155
gluteus medius, 155
gluteus minimus, 156
gracilis, 154
hypaxial, 121, 146, 147
iliococcygeal, 147
iliopsoas, 154
inferior labial, 125
infraspinatus, 137
intercostal, 147
internal oblique, 147
latissimus dorsi, 136
longissimus capitis, 135
longissimus dorsi, 146
masseter, 121
multifidus, 146
mylohyoid, 125
obturator, 156
palmaris longus, 143
muscles of cat (*continued*)
panniculus carnosus, 111
pectineus, 155
pectoantibrachialis, 137
pectoralis, 121, 137
pectoralis major, 121
pectoralis primus, 121
peroneus, 158
plantaris, 158
platysma, 111, 125
posterior trapezius, 121
pronator teres, 143
pterygoid, 126
pubococcygeal, 147
pyriformis, 156
rectus abdominis, 121, 147
rectus femoris, 154
rhomboideus, 136
sacrospinalis, 146
sartorius, 154
scalenus, 137
semimembranosus, 154
semispinalis, 146
semispinalis capitis, 135
semitendinosus, 154
serratus anterior, 136
soleus, 158
splenius, 135
sternohyoid, 134
sternomastoid, 134
sternothyroid, 134
subscapularis, 137
superior labial, 125
supraspinatus, 137
temporal, 126
teres minor, 136
thyrohyoid, 134
tibialis anterior, 158
transversus, 147
trapezius, 121, 135
triceps, 142
vastus intermedius, 155
vastus lateralis, 155
vastus medialis, 154
ventral levator scapulae, 135
muscles of dogfish, 19
muscles of Necturus
biceps, 138
biceps femoris, 148
constrictor branchiarum, 122
coracobrachialis, 138
deltoid, 126
diagastric, 122

muscles of Necturus (*continued*)
epaxial, 119, 143
extensor digitorum, 156
extensor digitorum communis, 138
external ceratohyoid, 122
external oblique, 144
flexor carpi radialis, 138
flexor carpi ulnaris, 138
flexor digitorum communis, 138
gastrocnemius, 156
geniohyoid, 122
gluteus, 148
gracilis, 147
hypaxial, 119, 144
iliopsoas, 148
intercostal, 144
internal ceratohyoid, 122
internal oblique, 144
ischio-caudalis, 148
latissimus dorsi, 126
levator arcuum, 123
levator branchiarum, 122
levator scapulae, 127
masseter, 119, 122
mylohyoid, 120
obturator, 147
omohyoid, 127
pectoralis, 119, 127
peroneus, 156
poplitius, 156
pronator, 138
precoraco-humeralis, 127
pubo-femoralis, 147
pyriformis, 148
rectus abdominis, 119, 144, 147
rectus femoris, 148
sartorius, 148
semimembranosus, 148
serratus anterior, 126
sternohyoid, 127
supracoracoid, 127
temporalis, 119, 122
tibialis anticus, 156
tibialis posticus, 156
transversus, 144
trapezius, 126
triceps, 138
vastus, 148
muscles of rabbit
adductor longus, 152
adductor magnus, 152
anterior trapezius, 121, 131
muscles of rabbit (*continued*)
basioclavicularis, 131
biceps, 140
biceps femoris, 152
brachialis, 140
brachioradialis, 141
clavodeltoid, 133
cleidomastoid, 130
coccygeal, 146
coracobrachialis, 140
deltoid, 132, 133
depressor conchae, 124
digastric, 124
dorsal levator scapulae, 131
epaxial, 120, 145
extensor antebrachii, 140
extensor carpi radialis, 141
extensor carpi ulnaris, 141
extensor digiti, 141
extensor digitorum communis, 141
extensor digitorum longus, 157
external oblique, 145
flexor carpi radialis, 141
flexor carpi ulnaris, 141
flexor digitorum longus, 158
flexor digitorum profundus, 141
flexor digitorum sublimis, 141
gastrocnemius, 157
gemellus, 153
geniohyoid, 124
gluteus maximus, 153
gluteus medius, 153
gluteus minimus, 153
gracilis, 151
hypaxial, 121, 145
inferior labial, 124
infraspinatus, 133
iliococcygeal, 146
iliopsoas, 152
intercostal, 145
internal oblique, 145
latissimus dorsi, 132
longissimus capitis, 131
longissimus dorsi, 145
masseter, 121, 124
multifidis, 145
mylohyoid, 124
obturator, 153
panniculus carnosus, 111
pectoralis, 121, 133
pectoralis major, 121
pectoralis primus, 121

muscles of rabbit (*continued*)
peroneus, 157
plantaris, 157
platysma, 111, 123
posterior trapezius, 121, 132
pronator teres, 141
pterygoid, 124
pubococcygeal, 146
rectus abdominis, 121, 146
rectus femoris, 151
rhomboideus, 132
sacrospinalis, 145
sartorius, 151
scalenus, 133
semimembranosus, 152
semispinalis, 145
semispinalis capitis, 131
semitendinosus, 152
serratus anterior, 132
soleus, 157
splenius, 131
sternohyoid, 130
sternomastoid, 130
sternothyroid, 130
subscapularis, 133
superior labial, 124
supraspinatus, 133
temporal, 124
teres major, 132
teres minor, 132
thyrohyoid, 130
tibialis anterior, 157
transversus, 146
trapezius, 121
triceps, 140
vastus intermedius, 153
vastus lateralis, 153
vastus medialis, 151
ventral levator scapulae, 131
myomere, definition, 1, 5, 19
myosepta, definition, 1, 5
myotome, 115

nails, 105
nasal capsule, 15, 60
lamprey, 39
nasopituitary opening, lamprey, 39
Necturus
digestive system, 159
external anatomy, 107
muscular system, 119, 122, 126, 138, 143, 147, 156
respiratory system, 159
Necturus (*continued*)
skull, 62
urinogenital system, 217
neopallium
bird, 244
mammal, 248
Neornithes, 47
nephridia, 7
nerve cord
Amphioxus, 3, 8
structure, 253, 254
nerves, cranial
dogfish, 239
mammal, 250
pigeon, 245
nerves, spinal
Amphioxus, 8
dogfish, 242
mammal, 251
pigeon, 247
nervous system, development, 231
neurocoele, 8, 244, 246, 251, 254
nictitating membrane, 108
notochord, 15, 90
Amphioxus, 2, 5
dogfish, 13
lamprey, 39

occipital condyles,
definition, 16
see skulls
oculomotor nerve, 240
olfactory capsules—see nasal capsules
olfactory nerve, 239
omenta—see digestive system
omenta, definition, 20
operculum
tadpole, 41
teleosts, 40
optic capsules, 15
optic nerve, 239, 247
optic vesicle, 231
oral region, mammal, 168
oral tentacles, 3
origin, definition, 116
Ornithorhynchus, 47
ostium, definition, 31
otic capsule, 15, 16, 60
ovaries
Alligator, 221
Amphioxus, 2
dogfish, 31
mammal, 225

ovaries (*continued*)
Necturus, 217
pigeon, 222
structure, 228
turtle, 219
oviduct—see Müllerian duct

pallium
dogfish, 243
mammal, 248
parachordal cartilages, 15
Parapsida, 47
patheticus nerve, 40
pectorial girdle—see girdle
pedicel, dogfish, 16
pelvic girdle—see girdle
penis
Alligator, 220
bird, 221
mammal, 111, 223, 225
turtle, 218
perch, external anatomy, 40
pericardial cavity, definition, 23
perimysium, 116
peripheral nerves, bird, 247
Perissodactyla, 49
pharyngeal region, mammal, 168
pharynx
Amphioxus, 3, 6
lamprey, 40
pia mater
bird, 244
mammal, 248
pigeon, 47
brain, 244
circulatory system, 188
digestive system, 165
nervous system, 244
respiratory system, 167
skeleton, 84
urinogenital system, 221
pigment cells, 3, 102
pineal body, 33, 238, 244
Pisces, 38
orders, 44
Pithecanthropus, 49
pituitary gland, 243, 249
pituitary sac, 39
placoid scales, 12
see scales
plantigrade, definition, 98
plastron, turtle, 82
pleural cavities, mammal, 170
Polypterus, 45
postcava—see circulatory system
prechordal cartilages, 15, 59
premolar teeth, definition, 75
prepuce, mammal, 111, 223
preservation of specimens, 267
Primates, 49
primitive, definition of, 9
pronephric duct, 31
pronephros, 31
prostate gland, 224
Prototheria, 47
pterygo-quadrate bar, 17, 59, 60
pubis, mammal, 193

rabbit
brain, 248
circulatory system, 191
digestive system, 167
external anatomy, 110
nervous system, 247, 251
respiratory system, 170
skeleton, 91
skull, 72
urinogenital system, 222
radius, mammal, 92
ramus communicans, 252
Ratites, 47
renal portal system—see circulatory system
reptiles
integument, 102
skull, 67
Reptilia, 38
orders, 46
respiratory system
Alligator, 165
cat, 170
Necturus, 160
pigeon, 167
rabbit, 170
turtle, 162
ribs
Alligator, 81
dogfish, 13
mammal, 89
pigeon, 86
turtle, 83
Rodentia, 48
rostrum
Amphioxus, 1
dogfish, 15
rotation, 117

sacrum, bird—see syn-sacrum
sacrum, mammal, 89
salamander, external anatomy, 42
salivary glands, mammal, 111
Sauripterus, 45
scales
  bird, 103
  ctenoid, 101
  cycloid, 101
  dogfish, 12
  ectodermal, 102
  ganoid, 100
  placoid, 100
scapula
  dogfish, 14
  mammal, 91
sclerotome, 115
scrotum, mammal, 223
Selachii, 44
semicircular canals, 235
seminal vesicle
  dogfish, 30
  mammal, 224
Seymouria, 46
  skull, 67
skeleton
  Alligator, 69, 80
  Amphioxus, 2, 3
  comparison of, 95
  dogfish, 13, 15
  lamprey, 39
  mammal, 72, 87
  pigeon, 84
  turtle, 67, 82
skin
  amphibia, 101
  reptile, 102
  structure of, 101
skull
  Alligator, 69
  amphibia, 61
  Capitosaurus, 61
  Cryptobranchus, 64
  development, 58
  Dimetrodon, 69
  evolution, 58
  Ictidopsis, 72
  Necturus, 62
  pigeon, 85
  rabbit, 72
  reptile, 67
  Seymouria, 67
  turtle, 67
skulls, comparison, 95
specialized, definition, 9, 10
spermatic cord, mammal, 224
spinal cord
  mammal, 251
  structure, 253, 254
spinal nerves, 242
  Amphioxus, 8
  bird, 247
  mammal, 251
spiracle
  dogfish, 12
  tadpole, 41
spleen—see digestive system
Squalus—see dogfish
Squamata, 47
Stegocephala, 45
sternum
  Alligator, 81
  bird, 86
  mammal, 90
suprascapula, dogfish, 14
sympathetic system
  bird, 247
  mammal, 252
Synapsida, 46
syncytium, definition, 54
synotic tectum, 58
syn-sacrum, 86
systemic veins—see circulatory system
swim bladder, 45

tadpole, external anatomy, 41
tarsus, mammal, 94
teeth, types, 75
teleost, external anatomy, 40
Teleostei, 45
Teleostomi, 44
tendons, definition, 116
testis
  Alligator, 220
  Amphioxus, 2
  dogfish, 30
  mammal, 111, 223
  Necturus, 217
  pigeon, 221
  structure, 227
  turtle, 218
thecodont dentition, definition, 96
Therapsida, 46
Theromorpha, 46

MUSEUM ASSOCIATES
LOS ANGELES COUNTY MUSEUM
THE LIBRARY

thyroid gland
  cat, 134
  rabbit, 130
tibia, mammal, 194
traneculae, 15, 59
trigeminal nerve, 40
trochlear nerve, 40
tunicates, 38
turtle
  circulatory system, 179
  external anatomy, 108
  skeleton, 82
  skull, 67
  urinogenital system, 218

ulna, mammal, 92
unguligrade, definition, 99
urinogenital system
  Alligator, 220
  development, 31
  dogfish, 29
  mammal, 222
  Necturus, 217
  pigeon, 221
  turtle, 218
Urochordata, 37
Urodela, 46
uterus
  bipartite, 226
  duplex, 226
  ligaments, 226

vagus nerve, 242
vas deferens—see Wolffian duct
veins—see circulatory system
ventral aorta—see circulatory system
ventricles of brain
  dogfish, 243
  mammal, 251
  pigeon, 245, 246
vertebrae
  caudal, 89
  cervical, 88
  development, 90
  dogfish, 13
  evolution, 90
  lumbar, 89
  sacral, 89
  thoracic, 88
vertebral column
  Alligator, 80
  bird, 85
  comparison, 96
  mammal, 87, 89
  turtle, 82
Vertebrata, 37
  classes, 38
  orders, 44
visceral arches, derivatives of, 60
visceral skeleton, dogfish, 16, 17
vitelline arteries, 234
vitelline veins, 234

wheel organ, 2, 5
Wolffian duct
  Alligator, 220
  dogfish, 30
  mammal, 224
  Necturus, 217, 218
  pigeon, 221
  turtle, 218